



## LETTER TO THE EDITOR

## Rib tip technique (RTT) to rhomboid block: A novel approach

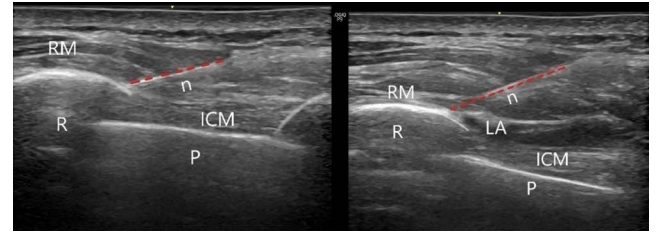
### Romboid bloka yeni yaklaşım: Rib tip (RTT) tekniği

Metem MANİCİ, Barış KÜÇÜKERDEM, Doğa ŞİMŞEK, Yavuz GÜRKAN

To the Editor,

Interfascial plane blocks are rapidly developing regional anesthesia techniques, especially in thoracic surgery, as an alternative to neuraxial blocks.<sup>[1]</sup> The rhomboid intercostal block (RIB) is a superficial plane block described by Elsharkawy et al.<sup>[2]</sup> in 2016. It is applied especially in thoracic surgery for complete analgesia of the hemithorax. In the RIB, first, the trapezius muscle, rhomboid major muscle, intercostal muscles, the ribs, and the pleura are identified by ultrasound guidance, and the injection site is the tissue plane between the rhomboid muscle and intercostal muscles. Analgesia is achieved by administering local anesthetic to the plane between the latter two muscles. The rhomboid intercostal block is assumed to show its analgesic effect by spreading the local anesthetic between the rhomboid muscle and intercostal muscle to the posterior branches of the thoracic spinal nerves at levels T2–T8.<sup>[3]</sup>

The pleura, located immediately below the intercostal muscle, poses a challenge in achieving this block. Accidental pleural injury may cause pneumothorax. To avoid the risk of pneumothorax, anesthesiologists often target the midpoint of the rib. However, thin fascial planes like those in the rhomboid block cause the needle to slide between the planes. This makes the control of the needle harder and increases the number of needle redirections to successfully place the needle tip into the correct plane. We describe a technique called “rib tip technique”, where we target the block needle tip to the adhesion area of the rhomboid muscle and intercostal muscle just by the ribs, but not to



**Figure 1.** Injection point of rib-tip technique and local anesthetic spread after the injection.

RM: Rhomboid major muscle; ICM: Intercostal muscles; R: Rib; P: Pleura; N: Needle.

the plane between the two ribs (Fig. 1). In this way, we think that the angle of the needle is steeper, and slipping of the needle between superficial fascial planes is avoided. In our experience, the block is performed faster compared to the technique which targets the midpoint of the rib. We perform a single shot block right after the surgery with 20 ml of local anesthetic solution, similar to the original technique.<sup>[2]</sup>

We think that the rib tip technique, while performing the rhomboid block, makes block performance easier and safer, while keeping the efficacy the same. The block performance time, success, and safety of the rib tip technique warrant future large-scale studies and randomized controlled trials.

### References

1. Marciniak D, Kelava M, Hargrave J. Fascial plane blocks in thoracic surgery: A new era or plain painful? *Curr Opin Anaesthesiol* 2020;33:1–9.
2. Elsharkawy H, Saifullah T, Kolli S, Drake R. Rhomboid intercostal block. *Anaesthesia* 2016;71:856–7.
3. Manici M, Salgın B, Coşarcan SK, Gürkan Y. Rhomboid block contributes to relieving postoperative thoracotomy pain. *J Clin Anesth* 2021;68:110075.

Department of Anesthesiology and Reanimation, Koç University Faculty of Medicine, İstanbul, Türkiye

Submitted (Başvuru): 01.12.2022 Revised (Revize): 01.12.2022 Accepted (Kabul): 07.02.2023 Available online (Online yayımlanma): 21.12.2023

**Correspondence:** Dr. Doğa Şimşek. Koç Üniversitesi Tıp Fakültesi, Anesteziyoloji ve Reanimasyon Anabilim Dalı, İstanbul, Türkiye.

**Phone:** +90 - 506 - 316 26 89 **e-mail:** dosimsek@ku.edu.tr

© 2024 Turkish Society of Algology