

RESEARCH ARTICLE

Comparison between three cannulated screws and targon locking plate for displaced intracapsular hip fracture: a retrospective study

Xiuxiu Hou, Guojun Shi, Yadi Zhang and Baorui Xing*

Cangzhou Hospital of Integrated Traditional Chinese Medicine and Western Medicine, Hebei Province, China

Abstract

Purpose: The aim of this retrospective study was to compare the clinical and radiological outcomes between three cannulated screws (TCS) and a combination of two cannulated screws along with one fully threaded cannulated screw with a TARGON locking plate (TCS-TLP) for the treatment of displaced intracapsular hip fractures.

Methods: Seventy-five patients with displaced intracapsular hip fractures were treated surgically between January 2013 and January 2019. Thirty-five patients underwent TCS-TLP, while the remaining 40 patients were treated with TCS. Injuries were assessed according to the AO classification, and outcome measurements included the modified Harris hip score (MHHS), visual analogue score (VAS), and radiological data.

Results: The TCS-TLP group showed significantly better MHHS improvement than the TCS group at 12 months (85.6 vs. 75.6, $P < 0.05$) and 24 months (89.4 vs. 81.1, $P < 0.05$). Furthermore, the TCS-TLP group had a lower incidence of complications compared to the TCS group, with 5 patients experiencing complications in the TCS-TLP group versus 14 cases in the TCS group ($P < 0.05$). Similarly, the femoral neck shorten rate was significantly lower in the TCS-TLP group at each follow-up visit ($P < 0.05$).

Conclusion: Patients who are treated with a combination of two cannulated screws, including one fully threaded cannulated screw along with a TCS-TLP, can experience improved functional outcomes, reduced orthopedic complications, and prevention of femoral neck shortening.

Keywords: *displaced intracapsular hip fracture; cannulated screw; Targon locking plate; femoral neck shortening*

Received: 14 May 2023; Revised: 29 May 2023; Accepted: 31 May 2023; Published: 3 July 2023

Intracapsular hip fracture is a prevalent injury that often leads to significant morbidity and mortality, especially among females over the age of 75 years (1). The increasing number of intracapsular hip fractures has resulted in escalating medical costs, placing a considerable social burden (2). Despite advancements, the treatment methods for intracapsular hip fractures continue to present challenges and remain controversial. The main strategies employed include total hip arthroplasty, hemiarthroplasty, and multiple cannulated screws, with several studies reporting satisfactory clinical outcomes using these methods (3). However, these approaches come with disadvantages and potential complications such as implant failure, malunion, and hip neck shortening post-operation, resulting in a total complication rate ranging from 26 to 65% (4, 5).

Recently, there has been increasing interest among researchers in the use of the Targon locking plate (TCS-TLP) for treating intracapsular hip fractures. This approach offers superior rotational stability and minimizes complications. Parker et al. conducted a study involving 320 patients who underwent treatment with a TCS-TLP. The results showed that 252 cases (78.8%) healed without complications, while 35 cases (11.6%) experienced nonunion, and 28 cases (8.8%) developed avascular necrosis during the 2-year follow-up period (6). In contrast, Matar et al. found lower complication rates in patients treated with the TCS-TLP system. Among 43 patients, only 2 cases experienced avascular necrosis, 2 cases resulted in nonunion, and 1 patient had screw cutout (7). Additionally, finite element analysis studies have demonstrated the enhanced rotational stability and resistance to shearing provided by the TCS-TLP (8).

Furthermore, some researchers have reported that fully threaded cannulated screws can minimize complications such as femoral neck shortening and pain. Weil et al. conducted a study involving 24 patients who underwent internal fixation with fully threaded cannulated screws, while another 41 patients were treated with partially threaded cannulated screws. The findings revealed significantly fewer instances of femoral neck shortening and screw pull-out in the group treated with fully threaded cannulated screws compared to the partial threaded group ($P < 0.05$) (9). Kanthasamy et al. also reported that the use of the Targon device can reduce the nonunion rate in comparison to cannulated screws for intracapsular hip fractures (10). However, there is limited published research on the clinical efficacy of fully threaded cannulated screws in combination with the TCS-TLP.

Therefore, this study aims to compare the clinical and radiological outcomes of three cannulated screws (TCS), two cannulated screws, and one fully threaded cannulated screw in conjunction with the TCS-TLP for patients with displaced intracapsular hip fractures.

Materials and methods

Participants

This study is a retrospective analysis that obtained all patient details with displaced intracapsular hip fracture who underwent either TCS or a combination of two cannulated screws and one fully threaded cannulated screw with TCS-TLP between January 2014 and January 2019. The data were extracted from medical records, and the study received approval from the Ethics Committee of Cangzhou Hospital of Integrated Traditional Chinese Medicine and Western Medicine (No. 2019007). Due to its retrospective nature, the requirement for informed consent was waived by the Institutional Review Board of our Hospital. The inclusion criteria were as follows: (1) freshly closed displaced intracapsular hip fractures; (2) age under 75 years old; (3) treatment with TCS or two cannulated screws combined with one fully threaded cannulated screw with TCS-TLP; and (4) intact medical records and more than a 24-month follow-up visit. According to these criteria, a total of 107 patients diagnosed with displaced intracapsular hip fractures were enrolled in this study. Patients were excluded if they refused involvement, had a surgical history in the hip, had long-term hormone use, or had a combined disease that may affect the clinical outcome, such as renal osteopathy, diabetes, and rheumatoid arthritis. Ultimately, 32 patients were excluded, and 75 patients were included in this study.

Surgical procedure

All patients in both groups were administered spinal anesthesia and positioned supine on the treatment table. The fractured limb was gradually reduced through longitudinal traction and rotation under fluoroscopic control.

TCS-TLP group

Around a 5 cm incision, a lateral approach under the vastus lateralis was performed to place a 130° alignment jig. Then, a K-wire was inserted above the level of the lesser trochanter, positioning it in the middle of the femoral neck as confirmed by C-arm fluoroscopy. The TCS-TLP (Fig. 1) and alignment jig were positioned on the lateral proximal femur, and three additional K-wires were inserted through the plate, extending into the femoral neck. Once the K-wires were measured and the screw holes were drilled, they were removed, and two cannulated screws along with one fully threaded cannulated screw were inserted. Finally, the two distal screws were placed through the plate to secure it to the lateral proximal femoral cortex (Fig. 2).

TCS group

After exposing the skin and muscle, locate and mark the level of the lesser trochanter. A K-wire was then inserted manually to achieve a central position, confirmed by C-arm fluoroscopy. Subsequently, three additional guide K-wires were inserted in an inverted triangle configuration, with an anteversion angle of 15 degrees and a gantry angle of 127 degrees. Finally, the guide K-wires were measured, and holes were drilled accordingly to insert TCS under C-arm fluoroscopy (Fig. 3).

The postoperative rehabilitation principles were as follows: during the first week after surgery, patients were instructed to exercise their quadriceps and ankles, and ambulation with walking sticks was encouraged for all patients after 3 to 4 weeks. However, full weight bearing was not permitted during the first 6 weeks.

Outcome evaluation

Pain assessment was conducted using the visual analogue scale (VAS), a self-assessed questionnaire with a range of 0 to 10 points (11). The recovery of hip function was evaluated using the modified Harris hip score (MHHS),



Fig. 1. The diagram of Targon locking plate.

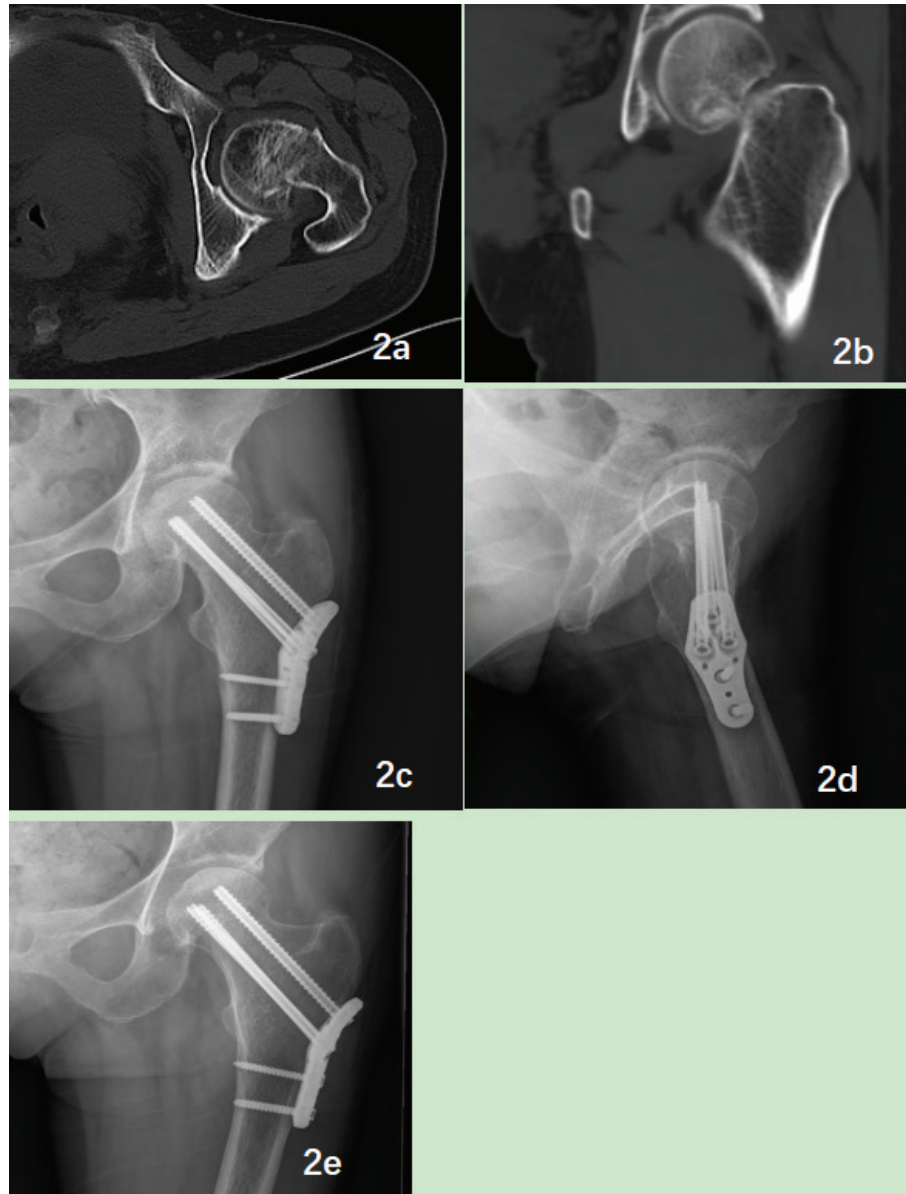


Fig. 2. (a and b): Preoperative hip CT scan of a 54 year-old female patient with displaced intracapsular hip fracture. (c and d): The 3 months postoperative X-ray showed fracture healed without orthopedic complications. (e): The 2 years postoperative X-ray of the fractured site was bone union without implement failure or femoral neck shortening.

which ranged from 0 (worst function and maximum pain) to 100 (best function and minimum pain) (12). General data, including age, gender, fracture side and type, operation time, and blood loss, were collected from medical records in both groups. Radiological data, including X-ray and CT scans, were obtained at preoperative, immediate postoperative, and 1, 6, 12, and 24 months of follow-up visits. These assessments were performed by two experienced orthopedic surgeons (DC Huang and GQ Jiang). The following parameters were analyzed: tip-apex distance, orthopedic complications (such as nonunion, malunion, and implant failure), bone union (defined as the restoration of cortical continuity and absence of a

visible fracture line), malunion (defined as a collodiaphyseal angle less than 120 degrees or less than 50% contact between the proximal and distal fragments), nonunion (defined as a lack of union or fracture displacement after 12 months of follow-up visits), and implant failure (including screw cutout, leakage, and breakage).

At the 6-month follow-up visit, the shortening of the femoral neck was measured using an anterior-posterior radiograph of the pelvis. The measurement was taken from the center of the femoral head along the axis of the femoral neck until it reached the axis of the femoral shaft and then compared to the unfractured site in the immediate postoperative X-ray. For cases with screw cutout, the

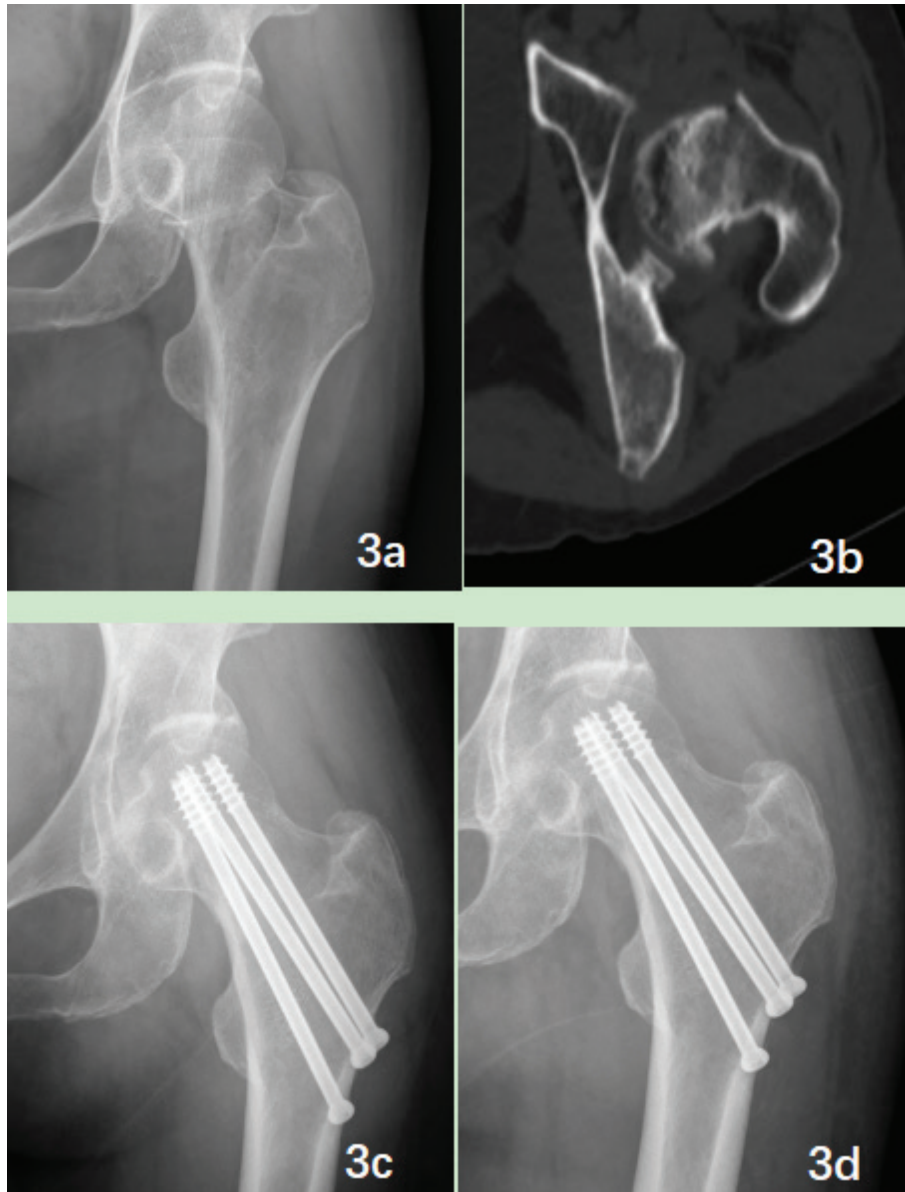


Fig. 3. (a and b): Preoperative hip X-ray and CT scan of a 49-year-old male patient with displaced intracapsular hip fracture. (c and d): The 1 year and 2 years postoperative x-ray showed fracture healed without orthopedic complications.

shortening was measured based on the greatest amount of lateral protuberance (13). A distance greater than 5 mm was defined as femoral neck shortening (14).

Statistics

In this study, all data were presented as mean ± standard deviation, and statistical analysis was conducted using SPSS for Windows version 25. The baseline characteristics and complication outcomes of all patients were analyzed using the χ^2 test. The paired *T*-test was employed to compare the outcomes between preoperative and each follow-up visit within each group, while the independent *T*-test was used to compare clinical evaluations at each

follow-up visit. A *P*-value less than 0.05 was considered statistically significant.

Result

A total of 75 patients were enrolled in this study. All patients with displaced intracapsular hip fracture who underwent either TCS or a combination of two cannulated screws with one fully threaded cannulated screw and TCS-TLP were followed up for a minimum of 2 years. There were no significant differences in general data, including age, gender, body mass index, time from injury to operation, fracture side, and type, between the two groups (*P* > 0.05) (Table 1). Similarly, no significant

Table 1. Comparison of baseline characteristics of two groups

Characteristic	TCS group (n = 40)	TCS-TLP group (n = 35)	P
Age, years (SD)	59.5 ± 13.5	61.3 ± 12.8	0.81
Gender, n (%)			
Male	17 (42.5)	15 (42.9)	0.58
Female	23 (57.5)	20 (57.1)	
BMI (SD)	23.7 ± 2.4	23.1 ± 1.9	0.23
Fracture side, n (%)			
Left	26 (65)	19 (54.3)	0.16
Right	14 (35)	16 (45.7)	
Fracture type, n (%)			
Garden III	28 (70)	23 (65.7)	0.44
Garden IV	12 (30)	12 (34.3)	
Injury to operation, ds (SD)	1.5 ± 0.5	1.7 ± 0.3	0.48

differences were observed in preoperative data between the two groups, such as VAS and MHHS scores ($P > 0.05$).

A significant difference was observed in operation time (57.4 ± 12.9 vs. 45.7 ± 16.4 , $P < 0.05$) and blood loss (68.4 ± 25.7 vs. 36.4 ± 8.7 , $P < 0.05$) between the TCS-TLP group and the TCS group. However, there was no significant difference in the minimal (5.4 ± 1.2 vs. 5.7 ± 0.9 , $P > 0.05$) and maximal (11.5 ± 3.6 vs. 12.1 ± 2.8 , $P > 0.05$) tip-apex distance between the two groups (Table 2). The TCS-TLP group showed significantly better recovery in MHHS compared to the TCS group at the 12- and 24-month follow-up visits ($P < 0.05$), but no statistical difference was observed at the 1- and 6-month follow-up visits between the two groups ($P > 0.05$). The VAS score significantly decreased in both groups after the operation, and a statistically significant difference was detected at the 1-month follow-up visit (2.2 ± 1.7 vs. 2.6 ± 1.4 , $P < 0.05$). However, there was no significant difference between the two groups at other follow-up visits ($P > 0.05$).

In the TCS group, the complication rate was 35% (14 out of 40). Among these, two patients experienced wound infection, which was managed conservatively. Additionally, there were three cases of malunion, one case of nonunion, two cases of screw cutout, four cases of screw loosening, one case of refracture, and one case of avascular necrosis. In the TCS-TLP group, 5 out of 35 patients (14.3%) experienced complications during the follow-up period. These included one case of wound infection and one case of malunion, as determined by radiological assessments at the final follow-up visit. The patient with avascular necrosis underwent treatment with total hip replacement, while the patient who experienced refracture in the operated site due to a fall was treated conservatively. Notably, the incidence of femoral shortening was significantly lower in the

Table 2. Comparison of clinical and radiological outcomes of two groups

Characteristic	TCS group (n = 40)	TCS-TLP group (n = 35)	P
Operation time, mins (SD)	45.7 ± 16.4	57.4 ± 12.9	0.04*
Blood loss, ml (SD)	36.4 ± 18.7	68.4 ± 25.7	0.03*
TAD			
Minimal, mm (SD)	5.4 ± 1.2	5.7 ± 0.9	0.57
Maximal, mm (SD)	11.5 ± 3.6	12.1 ± 2.8	0.39
MHHS (SD)			
Preoperation	37.4 ± 3.1	36.1 ± 2.8	0.48
1 month	71.5 ± 5.4	74.5 ± 3.1	0.15
6 months	73.7 ± 5.8	79.7 ± 3.3	0.61
12 months	75.6 ± 2.7	85.6 ± 3.7	0.03*
24 months	81.1 ± 3.2	89.4 ± 2.1	0.04*
VAS (SD)			
Preoperation	6.4 ± 2.5	6.7 ± 2.8	0.38
1 month	2.2 ± 1.7	2.6 ± 1.4	0.04*
6 months	1.2 ± 1.4	1.5 ± 1.7	0.14
12 months	0.8 ± 0.6	0.7 ± 0.5	0.72
24 months	0.5 ± 0.3	0.6 ± 0.4	0.86

TAD: Tip-apex distance; * $P < 0.05$

TCS-TLP group compared to the TCS group ($P < 0.05$). Specifically, 3 patients in the TCS-TLP group and 15 patients in the TCS group experienced femoral neck shortening (Table 3).

Discussion

Nowadays, there is a rising number of cases involving displaced intracapsular hip fractures, which significantly impact the quality of life for patients and pose a

Table 3. Comparison of complications and femoral neck shortening of two groups

Characteristic	TCS group (n = 40)	TCS-TLP group (n = 35)	P
Complications, n			
Wound infection	2	1	<0.05*
Malunion	3	1	
Nonunion	1	0	
Screw cutout	2	0	
Screw loosening	7	0	
Refracture	1	0	
Avascular necrosis	1	0	
Femoral neck shortening			
<5 mm	25	32	0.003*
>5 mm	15	3	

* $P < 0.05$

substantial economic burden on society. Displaced intracapsular hip fractures continue to pose a challenge for orthopedic surgeons as patients may experience various complications, including refracture, following surgery. The standard treatment for displaced intracapsular hip fractures in the elderly typically involves the use of TCS. Wani et al. conducted a study on 50 patients with displaced fractures of the femoral neck who underwent closed reduction and internal fixation with cannulated screws. The patients achieved satisfactory clinical outcomes, with the Harris hip score (HHS) improving to 90.6 ± 2.2 at the final follow-up visit. However, four patients experienced nonunion, and six patients developed avascular necrosis (15). Similarly, Dong et al. reported on 30 patients with displaced intracapsular hip fractures (Pauwels type III) who underwent standard cannulated screw fixation. They observed significant improvements in HHS and EQ-5D scores, but 17 out of 30 patients experienced femoral neck shortening (>5 mm) during the final follow-up visit (16).

In order to minimize orthopedic complications and femoral neck shortening, an increasing number of surgeons are focusing on the TCS-TLP and fully threaded cannulated screw for displaced intracapsular hip fractures. Parker et al. reported on 208 patients with displaced intracapsular hip fractures who underwent internal fixation with the TCS-TLP. The study showed significant improvement in pain mobility scores, and 148 out of 208 patients (71.1%) experienced uneventful fracture healing (17).

Some finite-element studies have also demonstrated the effectiveness of certain fixation methods. For instance, Li et al. conducted a finite-element analysis comparing ordinary cannulated screws, dynamic hip screws with derotational screws, and cannulated screws with TCS-TLPs. They found that the use of cannulated screws with TCS-TLPs exhibited superior resistance against shearing and rotational forces (18). In a retrospective study by Boraiah et al., 54 patients younger than 65 years old underwent open reduction and internal fixation using fully threaded cannulated screws. Out of the 54 patients, 51 experienced successful healing without any complications, and the average shortening of the femoral neck was measured at 0.54 mm (ranging from 0 to 2.7) (19).

In this study, a total of 75 patients with displaced intracapsular hip fracture who underwent internal fixation were enrolled in our study. Among them, 35 patients received treatment with two cannulated screws combined with one fully threaded cannulated screw and TCS-TLP, while the remaining 40 patients were treated with TCS.

Our findings demonstrate that the TCS-TLP group exhibited better improvement in hip function, decreased orthopedic complications, and minimized femoral neck shortening. At the 12- and 24-month follow-up visits, the MHHS scores were significantly higher in the TCS-TLP group compared to the TCS group ($P < 0.05$). Similarly,

femoral neck shortening of more than 5 mm was detected in 15 out of 40 patients in the TCS group, while only 3 out of 35 patients in the TCS-TLP group showed such shortening ($P < 0.05$). Furthermore, a total of 5 patients in the TCS-TLP group experienced orthopedic complications, and 1 patient had wound infection, whereas 15 patients in the TCS group had orthopedic complications and 2 had wound infections. Similar outcomes have been reported in previously published articles. Warschawski et al. documented that 23 (28.4%) patients experienced orthopedic complications with cannulated screws compared to 6 (17.6%) patients treated with TCS-TLP, although the patients using TCS-TLPs reported higher pain scores. However, femoral neck shortening was not measured in their study (20). Thein et al. retrospectively collected data from 31 patients treated with Targon FN and 47 patients who underwent internal fixation using multiple cannulated screws. They found that patients treated with Targon FN had a significantly lower rate of orthopedic complications and revisions compared to patients treated with multiple cannulated screws ($P < 0.05$) (21).

In our study, the femoral neck shortening rate was 37.5%. Other articles have reported similar outcomes, with femoral neck shortening rates ranging from around 27 to 31% in femoral neck fracture patients treated with multiple cannulated screws (22). Among our patients, only three (8.6%) underwent the combination of two cannulated screws and one fully threaded cannulated screw with TCS-TLP, resulting in femoral neck shortening. Wang et al. reported a femoral neck shortening rate of 23.5% in patients treated with three partially threaded cannulated screws (23). Additionally, Alves et al. found that fully threaded cannulated screws provide better biomechanical support and help prevent femoral neck shortening in femoral neck fractures undergoing internal fixation (24). Similarly, Alshameeri et al. reported that patients treated with Targon lock plates had a lower rate of nonunion and reoperation compared to patients treated with cannulated cancellous screws (25).

The possible reason for the occurrence of more orthopedic complications in patients treated with TCS may be insufficient resistance to shearing and rotational forces. On the other hand, the TCS-TLP not only provides stronger support in the femoral neck but also prevents screw loosening or cut-out (23). By inserting three screws in an inverted triangle, stability can be maintained at the fracture site, and the use of one fully threaded cannulated screw can help prevent femoral neck collapse after the operation. As a result, the TCS-TLP demonstrates superior improvement in reducing orthopedic complications and achieves better clinical efficacy compared to the use of TCS for fixation.

Some limitations of this study are as follows: Firstly, the study was conducted in a single center, and the sample

size is small. It would be beneficial to include a larger sample size and multicenter collaborations in future studies. Secondly, it would have been ideal to include patients treated with three partial threaded cannulated screws with dynamic locking screws as a control group; however, the number of such cases in our hospital was limited. Therefore, future studies with a larger patient population could consider including this control group. Lastly, to provide a more comprehensive analysis, biomechanical or finite element analysis should be conducted to evaluate the force distribution after the operation.

Conclusion

TCS-TLP fixation can significantly improve hip function, minimize orthopedic complications, and prevent femoral neck shortening compared to TCS for displaced intracapsular hip fracture. Furthermore, additional studies are needed to further testify the efficacy of TCS-TLP fixation for treating displaced intracapsular hip fractures.

Declarations

Thanks for the contribution of the tracking system.

Acknowledgements

We would like to thank Dr. Guangpu Han for insightful conversations.

Conflict of interest and funding

The authors have not received any funding or benefits from industry or elsewhere to conduct this study.

Availability of data and materials

The patients' datasets are confidential and are privately held for patient confidentiality safeguard. As such, the datasets generated and/or analyzed during the current study are not publicly available but are available from the corresponding author on reasonable request.

Ethics approval and consent to participate

This study was approved by the medical ethics review board of Cangzhou Hospital of integrated traditional Chinese medicine and Western medicine.

All methods in the study were carried out in accordance with the Helsinki guidelines and declaration.

All procedures were undertaken by the senior author after obtaining informed consent for all patients.

Consent for publication

We acquired informed written consent for publication of this report and accompanying images from the patients.

Competing interests

No competing interest to report.

References

- Alexiou KI, Roushias A, Varitimidis SE, Malizos KN. Quality of life and psychological consequences in elderly patients after a hip fracture: a review. *Clin Interv Aging* 2018; 13: 143–50. doi: 10.2147/CIA.S150067
- Wang Y, Cui H, Zhang D, Zhang P. Hospitalisation cost analysis on hip fracture in China: a multicentre study among 73 tertiary hospitals. *BMJ Open* 2018; 8(4): e019147. doi: 10.1136/bmjopen-2017-019147
- Beebe MJ, Bauer JM, Mir HR. Treatment of hip dislocations and associated injuries: current state of care. *Orthop Clin North Am* 2016; 47(3): 527–49. doi: 10.1016/j.ocl.2016.02.002
- Chammout K, Mukka SS, Carlsson T, Neander GF, Helge Stark AW, Sköldenberg OG. Total hip replacement versus open reduction and internal fixation of displaced femoral neck fractures: a randomized long-term follow-up study. *J Bone Joint Surg Am* 2012; 94(21): 1921–8. doi: 10.2106/JBJS.K.01615
- Bigoni M, Turati M, Leone G, Caminita AD, D'Angelo F, Munegato D, et al. Internal fixation of intracapsular femoral neck fractures in elderly patients: mortality and reoperation rate. *Aging Clin Exp Res* 2020; 32(6): 1173–8. doi: 10.1007/s40520-019-01237-z
- Parker M, Cawley S, Palial V. Internal fixation of intracapsular fractures of the hip using a dynamic locking plate: two-year follow-up of 320 patients. *Bone Joint J* 2013; null(10): 1402–5. doi: 10.1302/0301-620X.95B10.31511
- Mater HE, Chadran P. Outcomes of internal fixation of intracapsular hip fractures using dynamic locking plate system (Targon FN). *J Orthopaedic* 2018; 15(3): 829–31. doi: 10.1016/j.jor.2018.08.019
- Li J, Zhao Z, Yin P, Zhang L, Tang P. Comparison of three different internal fixation implants in treatment of femoral neck fracture—a finite element analysis. *J Orthop Surg Res* 2019; 14(1): 76. doi: 10.1186/s13018-019-1097-x
- Weil YA, Qawasmi F, Liebergall M, Mosheiff R, Khoury A. Use of fully threaded cannulated screws decreases femoral neck shortening after fixation of femoral neck fractures. *Arch Orthop Trauma Surg* 2018; 138(5): 661–7. doi: 10.1007/s00402-018-2896-y
- Kanthasamy S, To K, Webb JI, Elbashir M, Parker MJ. Timing of surgery for internal fixation of intracapsular hip fractures and complications at 1 year; a 32 year clinical study of 2,366 patients at a single center. *Injury*. 2021; 53(2), 584–589. doi: 10.1016/j.injury.2021.11.038
- Brokelman RB, Haverkamp D, van Loon C, Hol A, van Kampen A, Veth R. The validation of the visual analogue scale for patient satisfaction after total hip arthroplasty. *Eur Orthop Traumatol* 2012; 3(2): 101–5. doi: 10.1007/s12570-012-0100-3
- Vishwanathan K, Akbari K, Patel AJ. Is the modified Harris hip score valid and responsive instrument for outcome assessment in the Indian population with pertrochanteric fractures? *J Orthop* 2018; 15(1): 40–6. doi: 10.1016/j.jor.2017.12.001
- Stockton DJ, Lefavre KA, Deakin DE, Osterhoff G, Yamada A, Broekhuysen HM, et al. Incidence, magnitude, and predictors of shortening in young femoral neck fractures. *J Orthop Trauma* 2015; 29(9): e293–8. doi: 10.1097/BOT.0000000000000351
- Liu Y, Al ZS, Shao J, Yang T. Femoral neck shortening after internal fixation. *Acta Orthop Traumatol Turc* 2013; 47(6): 400–4. doi: 10.3944/AOTT.2013.3235
- Wani IH, Sharma S, Latoo I, Salaria AQ, Farooq M, Jan M. Primary total hip arthroplasty versus internal fixation in displaced fracture of femoral neck in sexa- and septuagenarians.

- J Orthop Traumatol 2014; 15(3): 209–14. doi: 10.1007/s10195-013-0278-3
16. Dong Q, Han Z, Zhang YG, Sun X, Ma XL. Comparison of transverse cancellous lag screw and ordinary cannulated screw fixations in treatment of vertical femoral neck fractures. *Orthop Surg* 2019; 11(4): 595–603. doi: 10.1111/os.12503
 17. Parker M, Cawley S, Paliat V. Internal fixation of intracapsular fractures of the hip using a dynamic locking plate: two-year follow-up of 320 patients. *Bone Joint J* 2013; 95-b(10): 1402–5. doi: 10.1302/0301-620X.95B10.31511
 18. Li J, Zhao Z, Yin P, Zhang L, Tang P. Comparison of three different internal fixation implants in treatment of femoral neck fracture—a finite element analysis. *J Orthop Surg Res* 2019; 14(1): 76. doi: 10.1186/s13018-019-1097-x
 19. Boraiah S, Paul O, Hammoud S, Gardner MJ, Helfet DL, Lorich DG. Predictable healing of femoral neck fractures treated with intraoperative compression and length-stable implants. *J Trauma* 2010; 69(1): 142–7. doi: 10.1097/TA.0b013e3181bba236
 20. Warschawski Y, Sharfman ZT, Berger O, Steinberg EL, Amar E, Snir N. Dynamic locking plate vs. simple cannulated screws for nondisplaced intracapsular hip fracture: a comparative study. *Injury* 2016; 47(2): 424–7. doi: 10.1016/j.injury.2015.10.054
 21. Thein R, Herman A, Kedem P, Chechik A, Shazar N. Osteosynthesis of unstable intracapsular femoral neck fracture by dynamic locking plate or screw fixation: early results. *J Orthop Trauma* 2014; 28(2): 70–6. doi: 10.1097/BOT.0b013e3182a225fa
 22. Tidermark J, Ponzer S, Svensson O, Soderqvist A, Tornkvist H. Internal fixation compared with total hip replacement for displaced femoral neck fractures in the elderly. A randomised, controlled trial. *J Bone Joint Surg Br* 2003; 85(3): 380–8. doi: 10.1302/0301-620X.85B3.13609
 23. Wang Z, Yin Y, Li Q, Sun G, Peng X, Yin H, et al. Comparison of early complications between the use of a cannulated screw locking plate and multiple cancellous screws in the treatment of displaced intracapsular hip fractures in young adults: a randomized controlled clinical trial. *J Orthop Surg Res* 2018; 13(1): 201. doi: 10.1186/s13018-018-0901-3
 24. Alves T, Neal JW, Weinhold PS, Dahners LE. Biomechanical comparison of 3 possible fixation strategies to resist femoral neck shortening after fracture. *Orthopedics* 2010; 33(4): 233–237. doi: 10.3928/01477447-20100225-07
 25. Alshameeri Z, Elbashir M, Parker MJ. The outcome of intracapsular hip fracture fixation using the Targon Femoral Neck (TFN) locking plate system or cannulated cancellous screws: a comparative study involving 2004 patients. *Injury* 2017; 48(11): 2555–2562. doi: 10.1016/j.injury.2017.08.063

***Baorui Xing**

Cangzhou Hospital of Integrated
Traditional Chinese Medicine and Western Medicine,
Hebei Province
061000, China
Email: xbrl3832786689@163.com