

網状肢端色素沈着症とDowling-Degos病とを合併した 1例

Take, Nobutoshi

Department of Dermatology, Graduate School of Medical Science, Kyushu University | Department
of Dermatology, Japanese Red Cross Fukuoka Hospital

Kido-Nakahara, Makiko

Department of Dermatology, Graduate School of Medical Science, Kyushu University

Furue, Masutaka

Department of Dermatology, Graduate School of Medical Science, Kyushu University

<https://doi.org/10.15017/1669233>

出版情報：福岡醫學雜誌. 107 (4), pp.82-85, 2016-04-25. 福岡医学会

バージョン：

権利関係：



Case Report

Coexistence of Reticulate Acropigmentation of Kitamura and Dowling–Degos Disease

Nobutoshi TAKE¹⁾²⁾, Makiko KIDO-NAKAHARA¹⁾ and Masutaka FURUE¹⁾

¹⁾*Department of Dermatology, Graduate School of Medical Science, Kyushu University, Fukuoka, 812-8582, Japan*

²⁾*Department of Dermatology, Japanese Red Cross Fukuoka Hospital, Fukuoka, 815-8555, Japan*

Both reticulate acropigmentation of Kitamura (RAK) and Dowling–Degos disease (DDD) are rare genodermatosis that exhibit autosomal dominant inheritance. The reticulated pigmented macules appear most commonly on the dorsa of the hands and feet in the former, and the flexures, such as axillae and groin, in the latter. We report here a rare case with overlapping features of RAK and DDD.

A 34-year-old Japanese woman presented with multiple freckle-like pigmented macules on the neck, axillae, cubital fossa, wrist, ankle, and dorsa of the hands and feet, which had occurred since childhood (Fig. 1a–e). Over the years, the macules had gradually progressed proximally. Hypopigmented macules, perioral pitted scars, and comedo-like lesions were absent. Her past medical history included mild scoliosis. Similar pigmented lesions were noted in her mother, sister, and aunt, but not in her eight-year-old daughter, which suggested that this case involved an autosomal dominant pattern of inheritance. Dermoscopic findings revealed a pigment network along a skin ditch, having a reticular pattern (Fig. 1f). Based on the history, clinical characteristics, and dermoscopic feature, we diagnosed the case as the coexistence of RAK and DDD.

RAK is a rare genodermatosis exhibiting autosomal dominant inheritance, which was first

described in 1943 by Kitamura and Akamatsu¹⁾. The typical age of onset is from childhood to puberty. It is characterized by asymptomatic reticulate freckle-like pigmented macules beginning on the dorsal hands and feet, and may gradually spread proximally and slowly darken. Palmoplantar pits with interruption of a fingerprint or palm print may also be seen²⁾.

DDD is another autosomal dominant genodermatosis that was first reported by Dowling in 1938 and Degos in 1954 ; the concept of the disease was proposed by Jones in 1978³⁾. Its onset is usually in middle age. The characteristic feature of this disease is reticulate pigmentation in the flexural areas of the neck, axillae, cubital fossa, and inguinal area. Occasionally, facial comedo-like lesions and perioral pitted acneiform scars may be presented⁴⁾. As differential diagnosis, dyschromatosis symmetrica hereditaria (autosomal dominant inheritance) and xeroderma pigmentosum (autosomal recessive inheritance) should be considered, but they were clinically distinguished by the existence of hypopigmented macules.

RAK and DDD are both autosomal dominant genodermatoses and have similar histological characteristics, namely, elongation of the rete ridge with hyperpigmentation of the basal layer. Several cases with overlap of RAK–DDD have been reported^{5)–8)}. Some authors¹⁾ suggested that

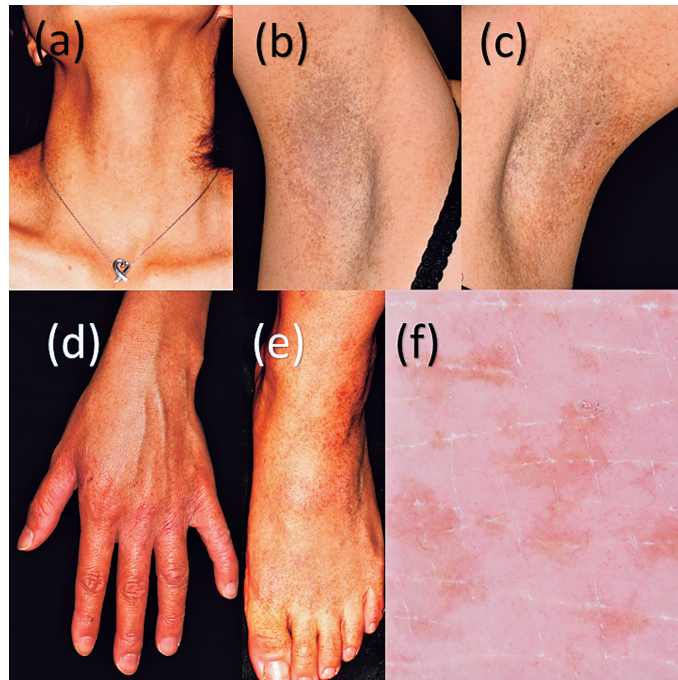


Fig. 1 Freckle-like pigmented macules on the (a) neck, (b) right axillae, (c) left axillae, (d) dorsa of hand and wrist, and (e) dorsa of foot and ankle. (f) Dermoscopic image of pigmented macules on the dorsa of the hand.

the two entities are different phenotypic expressions of the same genodermatosis⁸⁾. However, recently, Kono et al²⁾ showed that ADAM10 is the causative gene of RAK and that the families affected by RAK that they examined did not have a KRT5 mutation, the cause of DDD⁹⁾. Therefore, they concluded that RAK is a genetically distinct clinical entity independent from DDD²⁾. However, no reports about the genetic abnormalities in cases with overlap of RAK-DDD have been published. Further investigations are thus needed to reveal the relationship between RAK and DDD.

References

- 1) Kitamura K, Akamatsu S and A Kind : Of dyschromatosis symmetrica hereditaria. *Rinsho No Hifu Hitsunyo* 8 : 201-204, 1943.
- 2) Kono M, Sugiura K, Suganuma M, Hayashi M, Takama H, Suzuki T, Matsunaga K, Tomita Y and Akiyama M : Whole-exome sequencing identifies ADAM10 mutations as a cause of reticulate acropigmentation of Kitamura, a clinical entity distinct from Dowling-Degos disease. *Hum Mol Genet* 22 : 3254-3533, 2013.
- 3) Jones EW and Grice K : Reticulate Pigmented Anomaly of the Flexures Dowling Degos Disease, A New Genodermatosis. *Arch Dermatol* 114 : 1150-1157, 1978.
- 4) Irifune A, Fukuro S, katayama I and Nishioka K : A report of two cases of Dowling-Degos disease in a family *Rinsho Hifuka* 49 : 730-732, 1995.
- 5) Tang JC, Escandon J, Shiman M and Berman B : Presentation of Reticulate Acropigmentation of Kitamura and Dowling-Degos Disease Overlap. *J Clin Aesthet Dermatol* 5 : 41-43, 2012.
- 6) Fuesun A, Emel F, Turna I, Murat E and Tahsin GA : Dowling-Degos and Kitamura : Different features of the same entity? *J Dermatol* 35 : 311-313, 2008.
- 7) Vasudevan B, Verma R, Badwal S, Pragasam V, Moorchung N and Badad A : A Case of reticulate acropigmentation of Kitamura : Dowling Degos disease overlap with unusual clinical manifestations. *Indian J dermal* 59 : 290-292, 2014.
- 8) Crovato F, Desirello G and Rebora A : Is Dowling-Degos disease the same disease as kitamura's reticulate acropigmentation? *Br J Dermatol* 109 : 105-110, 1983.
- 9) Betz RC, Planko L, Eigelshoven S, Hanneken S, Pasternack SM, Bussow H, Van Den Bogaert K,

Wenzel J, Braun-Falco M, Rutten A, Rogers MA, Ruzicka T, Nöthen MM, Magin TM and Kruse R : Loss-of-function mutations in the keratin 5 gene lead to Dowling-Degos disease.

Am J Hum Genet 78 : 510-519, 2006.

(Received for publication April 4, 2016)

(和文抄録)

網状肢端色素沈着症と Dowling-Degos 病とを合併した 1 例

1) 九州大学大学院医学研究院皮膚科学分野

2) 日本赤十字社福岡赤十字病院皮膚科

武 信 肇¹⁾²⁾, 中原真希子¹⁾, 古江 増 隆¹⁾

症例は、34 歳女性。幼少期より頸部、両腋窩、肘窩、足関節、手関節、手背に小型あるいは網状の褐色色素斑を認め、徐々に近位部に拡大した。脱色素斑は伴わなかった。家族歴として、母親、妹、叔母にも同様の色素斑があるが、8 歳の子供には色素斑を認めない。ダーモスコピー所見は皮溝に沿って pigment network が散在して reticular pattern を示していた。特徴的な臨床所見、ダーモスコピー所見、家族歴で母親、妹、叔母に同様の症状あり、常染色体優性遺伝と思われたことから網状肢端色素沈着症と Dowling-Degos 病の合併例と診断した。網状肢端色素沈着症、Dowling-Degos 病はいずれも稀な常染色体優性遺伝形式の遺伝性皮膚疾患であり、網状肢端色素沈着症では、網状の褐色色素斑が手背、足背に出現し、一方 Dowling-Degos 病では肘窩、鼠径部など屈曲部に生じることが特徴である。網状肢端色素沈着症と Dowling-Degos 病を合併した症例の報告も数例あるが、いまだ少なく、今後遺伝子解析を含め症例の蓄積が待たれる。