

# Overview of bariatric and metabolic endoscopy interventions

Augustine Tawadros, Michael Makar, Michel Kahaleh<sup>ID</sup> and Avik Sarkar

*Ther Adv Gastrointest Endosc*

2020, Vol. 13: 1–11

DOI: 10.1177/  
2631774520935239

© The Author(s), 2020.  
Article reuse guidelines:  
sagepub.com/journals-  
permissions

**Abstract:** The rise of endoscopic techniques allowing weight loss offers an attractive alternative to surgical interventions in Western countries where the obesity epidemic has risen dramatically. Endoscopists are well positioned to manage obesity given their broad-based medical knowledge, understanding of gastrointestinal physiology, and training in endoscopic technique. The field of bariatric and metabolic endoscopy has permitted the development of several efficacious and safe technologies. This review focuses on techniques and devices used for endoscopic management of obesity, as well as the fundamental justifications to offer those therapies to obese patients.

**Keywords:** bariatric, endobariatric therapy, endoscopic sleeve gastroplasty

Received: 15 January 2020; revised manuscript accepted: 15 May 2020.

## Introduction

Obesity has become a global epidemic with sizeable socioeconomic and healthcare-associated burden. As of 2016, 93.3 million US adults had obesity, representing 39.8% of our adult population.<sup>1</sup> It is estimated that approximately US\$147 billion is spent annually on caring for patients with obesity. Combined with the limited effectiveness of diet and behavior modifications, this has created a tremendous interest in surgical and nonsurgical weight loss strategies.<sup>2</sup> Nevertheless, intensive lifestyle intervention and pharmacotherapy are associated with approximately 3.1–6.6% of total weight loss (TWL), and bariatric surgery is associated with 20–33.3% of TWL.<sup>3–8</sup> However, about 1% of eligible patients actually end up undergoing bariatric surgery due to a number of reasons, including risks, limited access, cost, and patient preference.<sup>3</sup>

In recent years, bariatric endoscopic procedures have been developed for patients with obesity who are not eligible for, or do not desire, bariatric surgery. Endoscopic bariatric and metabolic therapies (EBMTs) encompass an emerging field for the treatment of obesity. In general, EBMTs are associated with greater weight loss than lifestyle interventions and pharmacotherapy, but with a less-invasive risk profile than bariatric surgery.

EBMTs may be divided into two general categories—gastric and small bowel interventions. Gastric EBMTs are effective at treating obesity, whereas small-bowel EBMTs are effective at treating metabolic diseases with a variable weight loss profile depending on the device.<sup>9,10</sup> A variety of novel and innovative procedures have been developed for the treatment and management of patients with obesity and related comorbidities. EBMTs have been shown to have improved outcomes with lower risk, cost, and complications when compared with traditional bariatric surgeries. This review article discusses the current literature regarding EBMTs.

## Gastric EBMTs (aspiration therapy, intragastric balloons, endoscopic sleeve gastroplasty, primary obesity surgery endoluminal, Gelesis100, Endomina)

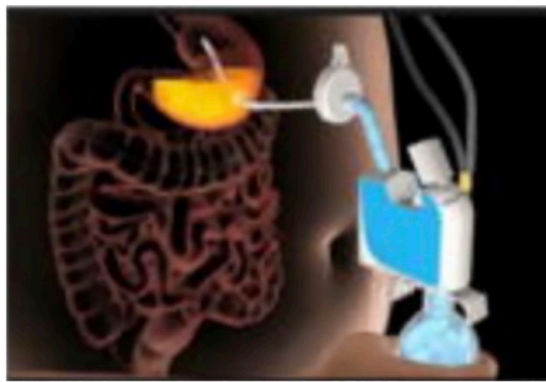
### Aspiration therapy

The AspireAssist device (Aspire Bariatrics, Inc., King of Prussia, PA, USA) is a gastrostomy-based device that allows partial aspiration of recently ingested food (Figure 1). It uses similar technology to a percutaneous endoscopic gastrostomy (PEG) tube to aspirate portions of ingested food from the stomach. Sullivan and colleagues conducted the first pilot study through a randomized controlled

Correspondence to:  
**Michel Kahaleh**  
Professor of Medicine,  
Clinical Director of  
Gastroenterology,  
Chief of Endoscopy,  
Director Pancreas  
Program, Department  
of Gastroenterology,  
Rutgers Robert Wood  
Johnson Medical School,  
Robert Wood Johnson  
University Hospital, 1 RWJ  
Place, MEB 491C, New  
Brunswick, NJ 08901, USA  
[mkahaleh@gmail.com](mailto:mkahaleh@gmail.com)

**Augustine Tawadros,  
Michael Makar**  
Department of Internal  
Medicine, Rutgers Robert  
Wood Johnson Medical  
School, New Brunswick,  
NJ, USA

**Michel Kahaleh, Avik  
Sarkar**  
Department of Internal  
Medicine, Division of  
Gastroenterology, Rutgers  
Robert Wood Johnson  
Medical School, New  
Brunswick, NJ, USA



**Figure 1.** Aspiration therapy.  
Source: Jirapinyo and Thompson.<sup>9</sup>

trial at Washington University School of Medicine. After 1 year, subjects in the aspiration therapy (AT) group lost about 19% of their body weight compared with the lifestyle therapy group which lost about 6% of TBW ( $p < .04$ ). Patients in the AT group maintained their weight loss at 2 years and had no evidence of complications or death. AT resulted in a decrease in total absorbed calories, reduced food intake, and improved eating behaviors.<sup>11</sup> The Pivotal Aspiration Therapy with Adjusted Lifestyle (PATHWAY) Study, conducted by Thompson and colleagues, is a large, 1-year, multicenter study that further evaluated the safety and efficacy of AspireAssist for weight loss management. At 52 weeks, patients undergoing AT lost  $31.5 \pm 26.7\%$  of their excess body weight and  $12.1 \pm 9.6\%$  of total body weight. Patients in the lifestyle group had lost a mean of  $9.8 \pm 15.5\%$  of their excess body weight and  $3.5 \pm 6.0\%$  of total body weight ( $p < 0.001$ ).<sup>12</sup> Patients also experienced amelioration of metabolic parameters such as reductions in triglycerides, glycated hemoglobin (HbA1c), and low-density lipoproteins. Patients also experienced improvements in blood pressure and high-density lipoproteins. Further research studies have shown that AT is an efficient and safe alternative to bariatric surgery in patients with obesity.<sup>13</sup> The AspireAssist device is now approved by the US Food and Drug administration (FDA) in patients with a body mass index (BMI) between 35 and 55 kg/m<sup>2</sup>.

#### *Intragastric balloons*

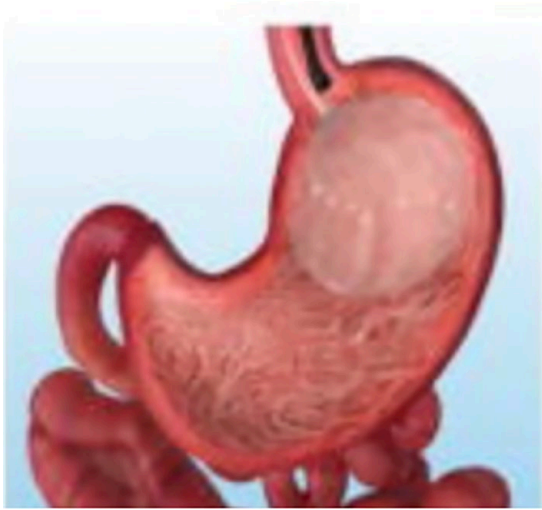Intragastric balloons (IGB) facilitate weight loss by reducing the stomach's potential volume, inducing early satiety and altering gastric motility. Reductions in gastric hormone secretion such as

cholecystokinin and pancreatic polypeptide may reflect delayed gastric emptying and improve glucose metabolism.<sup>14</sup> Furthermore, changes in appetite-regulating hormones such as ghrelin were significantly decreased in patients with IGB, leading to decreased hunger and greater weight reduction.<sup>15</sup> IGB have been studied since 1985, including the Ballobes Balloon and Garren-Edwards Gastric Bubble. These balloons had no significant effects on weight reduction due to small volume and cylindrical shape and had high rates of complications, including gastric erosions and ulcers.<sup>16</sup> However, significant changes and improvements in endoscopic devices have allowed for the development of various types of IGB that have now been approved by the FDA.

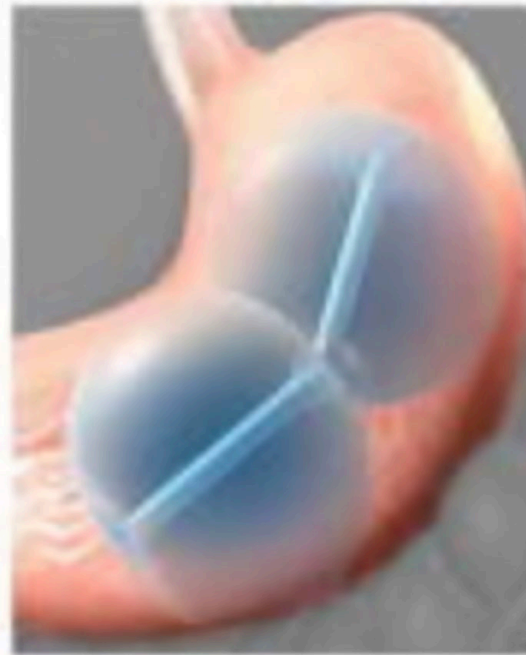#### *The Orbera IGB*

The Orbera (Apollo Endosurgery, Austin, TX, USA), previously known as the Bioenterics Intragastric balloon (BIB®), has been approved in the United States since 2015 for patients with a BMI between 30 and 40 kg/m<sup>2</sup> (Figure 2). The Orbera is one of the most widely used balloons outside the United States in countries like Europe, South America, Asia, and the Middle East. It is a saline-filled single balloon system with a volume ranging from 400 to 700 ml. It is implanted for up to 6 months and requires endoscopic placement and removal. Many studies outside of the United States have been conducted in evaluating the safety and efficacy of this balloon.

Prior to its approval in the United States, the ASGE Bariatric Endoscopy Task Force conducted a systematic review and meta-analysis. In 17 studies including 1683 patients, the percentage of estimated weight loss (%EWL) was 25.44% and total body weight loss (%TBWL) was 11.27% at 12 months after implantation.<sup>17</sup> In a pivotal, multicenter, open-label clinical trial conducted in the United States, patients who made lifestyle modifications in addition to the IGB had an estimated weight loss of 10.2% compared with 3.3% in the lifestyle-only group at 6 months after implantation. At 3 months after balloon removal (9 months after implantation), the balloon group had a mean of 5.7% TBWL more than the lifestyle-alone group. The majority of adverse events included nausea, vomiting, and abdominal pain that were treated conservatively with medications and supportive care. Ten percent of subjects with the IGB had severe adverse events (SAEs) including severe dehydration,



**Figure 2.** Orbera gastric balloon.  
Source: Jirapinyo and Thompson.<sup>9</sup>



**Figure 3.** Reshape Duo intragastric balloon.  
Source: Jirapinyo and Thompson.<sup>9</sup>

gastric outlet obstruction, and gastric perforation, but all resolved without sequela.<sup>18</sup>

One of the largest retrospective studies in Italy looked at 2500 patients undergoing treatment with the use of the BIB and reported a reduction in BMI by 4.9 kg/m<sup>2</sup> and %EWL of 33.9% in a 6-month period. Preoperative comorbidities including hypertension, diabetes, respiratory disorders, dyslipidemia, and osteoarthropathy resolved in 44.3% of patients.<sup>19</sup> A meta-analysis performed by *Imaz and colleagues* looked at a total of 15 articles and more than 3000 patients. Patients lost an estimate of 12.2% of initial weight, 32.1% of excess weight, and had reductions in obesity-related comorbidities such as hypertension and diabetes and decreased overall mortality.<sup>20,21</sup> The Orbera has been extensively studied and is shown to be an effective treatment option for short-term weight loss and reduced metabolic comorbidities.

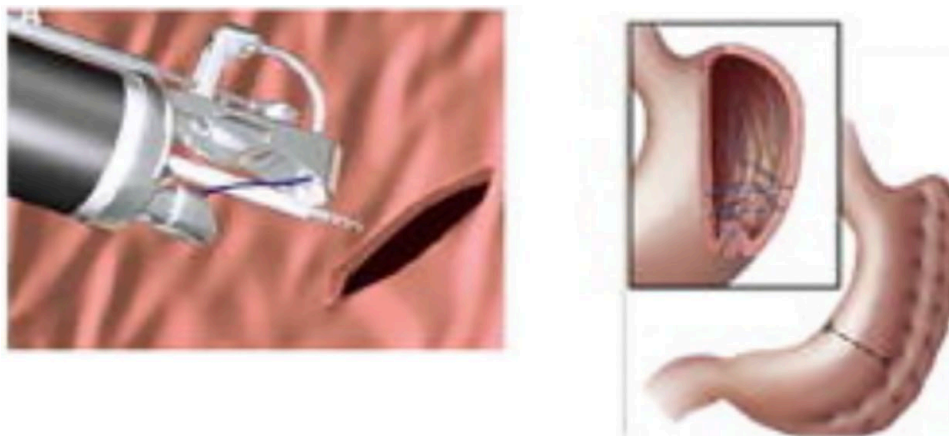
#### *ReShape Duo IGB*

The ReShape (ReShape Medical, Inc., San Clemente, CA, USA) Duo is a saline-filled dual balloon system that is interconnected by a flexible wire (Figure 3). It was approved by the FDA in 2015 for patients with a BMI between 30 and 40 kg/m<sup>2</sup> with one obesity-related comorbidity. Two balloons are placed endoscopically and are filled with 450 ml of normal saline dyed with methylene blue. The dual balloon design reduces the risk of prosthesis migration and is retrieved 6 months after placement.<sup>22</sup> The REDUCE pivotal trial was a

prospective, randomized controlled trial published in 2015 that was conducted to evaluate the safety and efficacy of the Reshape procedure. Patients undergoing the procedure were found to have a decreased 25.1% %EWL compared with 11.3% for the control group (intention-to-treat). Additional findings included a 27.9% %EWL for completed cases and a decrease of 2.7 BMI units compared with 1.3 for the control group. Further improvements in comorbidities included significant changes in HbA1c, systolic and diastolic blood pressures, and high- and low-density lipoproteins that persisted at 48 weeks after treatment. Adverse effects included nausea, vomiting, and abdominal pain after implantation that resolved within 1 week with medications and fluids. Gastric ulcers were initially observed in 39% of patients due to pressure from the device tip, but modifications to the device resulted in a reduction in ulcer frequency to 10% and a reduction in ulcer size from 1.6 to 0.8 cm. These ulcers were small, inconsequential, and not clinically significant. Additional studies are needed to better understand the role of the Reshape system in clinical practice.

#### *Obalon IGB*

The Obalon Gastric Balloon (OGB; Obalon Therapeutics Inc., Carlsbad, CA, USA) is a gas-filled balloon with a fill volume of 250 ml with up



**Figure 4.** Endoscopic sleeve gastropasty.  
Source: Jirapinyo and Thompson.<sup>9</sup>

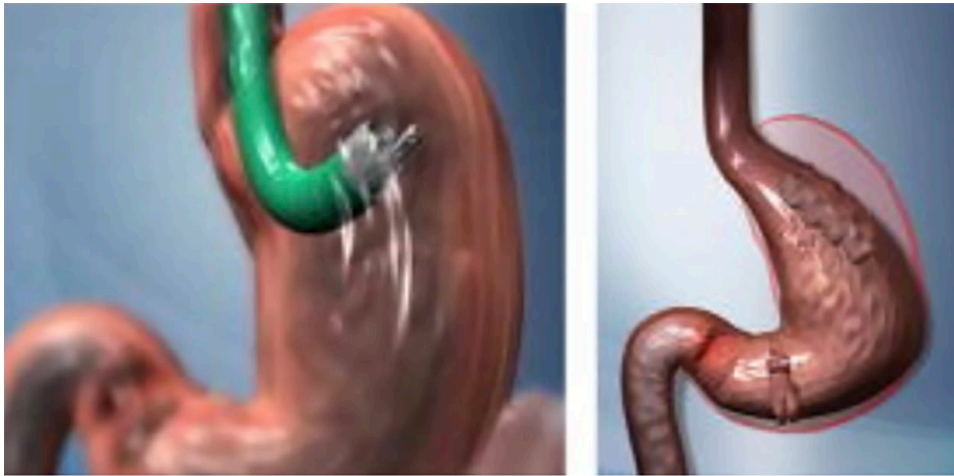
to three balloons placed over a 3-month period. It is a swallowed capsule delivery device but requires endoscopy for deflation and removal. It was approved by the FDA in 2016 for patients with a BMI between 30 and 40 kg/m<sup>2</sup>. Mion and colleagues conducted a prospective, multicenter, pilot feasibility study in Europe that was published in 2013. A total of 17 patients were included in the study and had a %EWL of 36% and a 5.0-kg weight loss at 12 weeks with no SAEs.<sup>23</sup> A randomized controlled trial with 15 centers in the United States randomized patients to receive three Obalon balloon capsules or three sugar-filled sham capsules. All subjects underwent lifestyle counseling every 3 weeks by a registered dietitian. Results included subjects who swallowed at least two capsules and completed 18 weeks of therapy. Patients in the treatment group had a %TBWL of  $6.81 \pm 5.1\%$  compared with  $3.59 \pm 5.0\%$  in the control group. The responder rate was 64.3% in the treatment group and defined as a %TBWL >5%. Minor adverse events such as nausea and abdominal pain occurred in most subjects, with only one SAE being gastric ulcer due to a patient having taken a nonsteroidal anti-inflammatory drug against study protocol.<sup>24</sup> The Obalon is a new IGB, and further randomized controlled studies are needed.

#### *Endoscopic sleeve gastropasty*

The increased burden of surgical procedures, complications, and cost has led to emerging developments in endoscopy-based intraluminal therapies. Endoscopic sleeve gastropasty (ESG) is a minimally invasive procedure that uses a full-thickness

endoscopic suturing device to create a restrictive sleeve that reduces the size of the gastric reservoir (Overstitch; Apollo Endosurgery, Austin, TX, USA) (Figure 4). This procedure has been recognized for its ability to promote weight loss with very low complications and improvements in obesity-related comorbidities. Abu Dayyeh and colleagues<sup>25</sup> introduced this novel technique reproducing the anatomical manipulations of surgical sleeve surgeries and verified the technical feasibility of this procedure in 2013. A recently published meta-analysis by Li and colleagues reviewed 1542 patients from nine studies who underwent ESG. After ESG, the tendency of %TBWL gradually increased, from 8.78% at 1 month to 16.09% at 12 months. In addition, the tendency of %EWL also gradually increased from 31.16% at 1 month to 59.08% at 12 months.<sup>26</sup> Some patients were discharged on the same day of the procedure or after 24–48 h.<sup>27,28</sup> Minor adverse events included abdominal pain and nausea but were treated with conservative management. A study by Alqahtani and colleagues<sup>29</sup> of 1000 patients found the mean %TWL at 6, 12, and 18 months to be  $13.7 \pm 6.8\%$ ,  $15.0 \pm 7.7\%$ , and  $14.8 \pm 8.5\%$ , respectively. Abdominal pain and nausea were the most common complaint that resolved within the first week of the procedure. No patients required emergency intervention and there were no mortalities. A review by Storm and Abu Dayyeh<sup>30</sup> reported data on 1607 cases reported from large multicenter studies to provide evidence for the safety and efficacy of this procedure. They found %TWL across these studies at 6, 12, and 18 months or more to be 15.8, 17.1, and 17.3, respectively. In total, SAE rates were 1.1% with a total of 18 events and no





**Figure 5.** Primary obesity surgery endoluminal.  
Source: Jirapinyo and Thompson.<sup>9</sup>

deaths. Obesity-related comorbidities such as hypertension, diabetes, and hypertriglyceridemia have also been shown to be decreased in patients undergoing ESG.<sup>31</sup>

Both ESG and laparoscopic sleeve gastrectomy (LSG) are restrictive procedures that lead to weight loss by reducing the size of the stomach. LSG involves surgical resection of two-thirds of the stomach to provide increased satiety and decreased appetite. ESG uses plications to create a sleeve-shaped stomach. Decreasing the stomach size leads to decreased consumption of food, early stomach distention, and satiety. Studies comparing ESG with LSG and laparoscopic band found that patients undergoing ESG had significantly lower rates of morbidity, decreased length of stay, decreased adverse events, and decreased gastrointestinal reflux.<sup>32–34</sup> LSG is noted to have greater weight loss compared with ESG, specifically in patients with BMI >40 kg/m<sup>2</sup>. ESG has been shown to be an effective and safe alternative to traditional bariatric surgeries.

#### *Primary obesity surgery endoluminal*

Primary obesity surgery endoluminal (POSE) uses the incisionless operating platform (IOP; USGI Medical, San Clemente, CA, USA) to create full-thickness plications in the gastric fundus to reduce gastric volume (Figure 5). It will also limit gastric fundal accommodation to meals and facilitate earlier and prolonged satiety in patients. It is hypothesized that antral dysmotility will prolong satiety by inducing an earlier and longer

feeling of gastric distention.<sup>27</sup> Espinós and colleagues<sup>35</sup> published initial outcomes in patients undergoing POSE surgery in Spain with 6-month mean EWL of 49.4% and TBWL of 15.5 %. Additional studies with continued 1-year follow-up found that patients who underwent POSE surgery continued to have decreased weight loss with a mean %TWL of 15% and %EWL of 45%.<sup>36</sup> Furthermore, a randomized sham control trial, the ESSENTIAL Trial, conducted by Sullivan and colleagues evaluated weight loss, comorbidities, quality of life, and adverse effects of POSE. At 12 months, the mean TBWL was  $4.95 \pm 7.04\%$  for patients undergoing POSE and  $1.38 \pm 5.58\%$  for the sham group. Patients had statistically significant improvement in diabetes with decreased number of medications and trends of reduced hypertension, systolic blood pressure, total cholesterol, and low-density lipoprotein. They reported that the most common adverse events included pain, nausea, and vomiting that resolved with supportive care, including pain control, antiemetics, and intravenous fluids.<sup>37</sup> The results of the ESSENTIAL Trial and several other studies confirm the safety and efficacy of this procedure as an alternative option to more invasive bariatric surgeries for patients seeking additional treatment options for weight loss.

#### *Gelesis100*

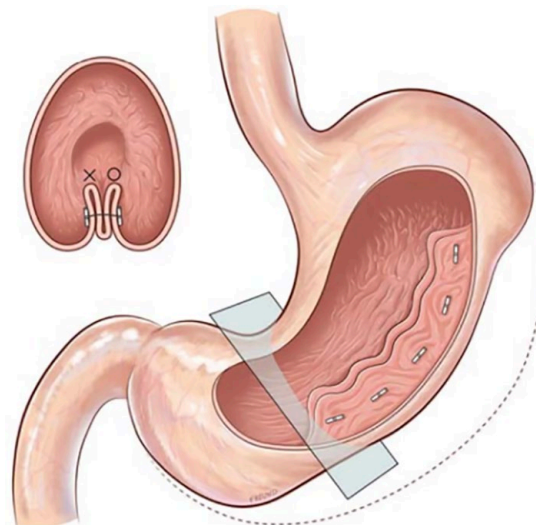
Gelesis100 (Gelesis, Boston, MA, USA) is a super-absorbent hydrogel, which is made from two naturally derived building blocks, modified cellulose cross-linked with citric acid, that create a

three-dimensional matrix. It is orally administered in capsules with water before a meal. Gelesis100 particles rapidly absorb water in the stomach and mix with ingested foods. When hydrated, the recommended dose of Gelesis100 occupies about one-fourth of the average stomach volume. It creates thousands of small individual gel pieces. Gelesis100 maintains its three-dimensional structure and mechanical properties during transit through the small intestine. Once it arrives in the large intestine, the hydrogel is partially broken down by enzymes and loses its three-dimensional structure along with most of its absorption capacity. The released water is reabsorbed, and the remaining cellulosic material is expelled in the feces.

In the Gelesis Loss of Weight (GLOW) study, Greenway and colleagues conducted a multicenter, randomized, double-blind, placebo-controlled study in patients with BMI  $\geq 27$  and  $\leq 40$  kg/m<sup>2</sup> and fasting plasma glucose  $\geq 90$  and  $\leq 145$  mg/dl. Gelesis100 treatment caused greater weight loss over placebo (6.4% *versus* 4.4%,  $p=0.0007$ ). Importantly, 59% of Gelesis100-treated patients achieved weight loss of  $\geq 5\%$  and 27% achieved weight loss of  $\geq 10\%$  *versus* 42% and 15% in the placebo group. Gelesis100-treated patients had twice the odds of achieving  $\geq 5\%$  and  $\geq 10\%$  of weight loss *versus* placebo [adjusted odds ratio (OR): 2.0,  $p=0.0008$ ; OR: 2.1,  $p=0.0107$ , respectively], with 5% responders having a mean weight loss of 10.2%. Patients with prediabetes or drug-naïve type 2 diabetes (T2DM) had six times the odds of achieving  $\geq 10\%$  of weight loss. Gelesis100 treatment had no apparent increased safety risks. Gelesis100 is a promising new nonsystemic therapy for overweight and obese patients with a highly desirable safety and tolerability profile.<sup>38</sup>

#### Endomina suturing system

The Endomina suturing system (Endo Tools Therapeutics, SA-ETT, Gosselies, Belgium) is a single-use device attached to the endoscope that aims to reduce the volume of the stomach and its distensibility (Figure 6). It uses a triangulation platform to perform large plications with transmural sutures and serosa-to-serosa apposition. Huberty and colleagues conducted the first, multicenter, prospective trial evaluating the safety and efficacy of the Endomina technique. Included patients had class 1 or class 2 obesity with an average BMI of 35.1 kg/m<sup>2</sup> [standard deviation (SD)=3.0]. They showed EWL and TBWL at 1 year to be 29%



**Figure 6.** Endomina suturing system.

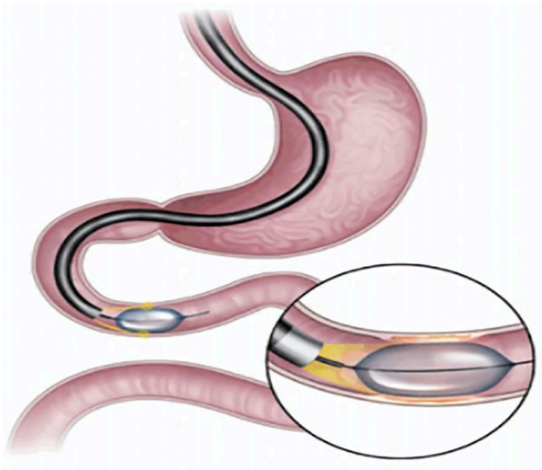
Source: Huberty and colleagues.<sup>39</sup>

(SD=28) and 7.4% (SD=7), respectively.<sup>39</sup> Mild adverse events included abdominal discomfort which resolved within 5 days without intervention, and no other adverse or serious events were recorded. Further clinical trials are ongoing to evaluate the safety and efficacy of this device.

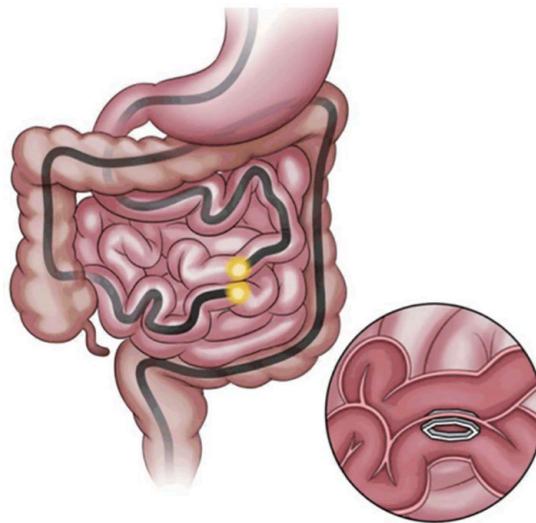
#### Small-bowel EBMTs (duodenal mucosal resurfacing, endoluminal magnetic partial jejunal diversion, duodenal-jejunal bypass liner)

##### Duodenal mucosal resurfacing

Duodenal mucosal resurfacing (DMR; Fractyl, Lexington, MA, USA) is a novel, minimally invasive procedure that involves a catheter-based hydrothermal ablation of the duodenal mucosa with subsequent regeneration of healthy new mucosa (Figure 7). The duodenum is important for regulating metabolic homeostasis, and alterations in the mucosa may affect glycemic metabolism by an insulin sensitization effect.<sup>41</sup> The DMR is used for patients with T2DM on at least one oral antidiabetic medication and with an HbA1c  $\geq 7.5\%$ . Rajagopalan and colleagues<sup>42</sup> conducted the first-in-human clinical study in a total of 39 patients using the DMR procedure as a treatment option for patients with T2DM. In the first 6 months, patients' HbA1c was reduced by at least 1.2% in the entire cohort with greater reductions in the long-segment DMR. The major adverse event noted was duodenal stenosis in three patients but was treated with endoscopic balloon dilatation. Further advances in



**Figure 7.** Duodenal mucosal resurfacing.  
Source: Gong and Kim.<sup>40</sup>



**Figure 8.** Endoluminal magnetic partial jejunal diversion.  
Source: Gong and Kim.<sup>40</sup>

the catheter have been developed to help reduce the risk of stenosis. Recent studies in the past few years have found favorable outcomes with reductions in glycemic control.<sup>43,44</sup> The first international, multicenter, open-label, prospective study demonstrated about a 1% reduction in HbA1c at 1 year compared with baseline.<sup>43</sup> Additional findings included improvements in fasting plasma glucose ( $-1.7 \pm 0.5$  mmol/l) and Homeostatic Model Assessment of Insulin Resistance (HOMA-IR,  $-2.9 \pm 1.1$ ). Mild adverse events such as nausea, abdominal pain, malaise, and fatigue were noted but resolved without intervention and disruption of daily activity. DMR may be a reasonable alternative to the management of diabetes and a potential adjunct to oral medications.

#### *Endoluminal magnetic partial jejunal diversion*

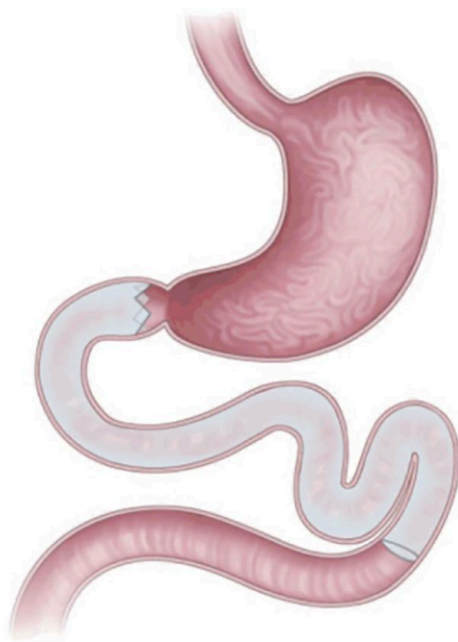The incisionless magnetic anastomotic system (IMAS; GI Windows, West Bridgewater, MA, USA) is a novel self-assembling magnetic device that allows for side-to-side anastomosis with enteral diversion (Figure 8). The magnets are deployed in the jejunum and ileum that form an anastomosis through necrosis of adjacent tissue. Partial jejunal diversion (PJD) allows foods and nutrients to bypass most of the small bowel and enter directly into the ileum. This allows for increased secretions of gut hormones such as peptide YY (PYY) and glucagon-like peptide-1 (GLP-1) that promote weight loss and improvements in glucose homeostasis. The first open, prospective, single-arm pilot study was conducted at the University Hospital of Ostrava, Ostrava,

Czech Republic, and published in 2017. They evaluated the clinical outcomes, safety, and efficacy of IMAS placement and creation of a PJD in a total of 10 patients. At 12 months, patients had a TWL of 14.6%, an excess weight loss of 40.2%, and a decrease in HbA1c of 1.9% and a decrease in fasting glucose levels of 37% in diabetic patients. Furthermore, they identified a significant increase in PYY activity at 2 months and reductions in postprandial insulin and glucose levels at 2 and 6 months. Mild side effects included nausea and diarrhea that resolved with supportive care, nutritional counseling, and a short course of loperamide. Patients had vitamin D, iron, vitamin B12, and magnesium deficiencies but were treated with oral supplementation.<sup>45</sup> The outcomes in this study were promising and further studies are needed to confirm and support its use as an alternative for weight loss and glycemic control.

#### *Duodenal-jejunal bypass liner*

The duodenal-jejunal bypass liner (DJBL; EndoBarrier Gastrointestinal Liner; GI Dynamics Inc., Lexington, MA, USA) is a single-use sleeve-like implant deployed into the duodenum for a maximum of 12 months (Figure 9). It works by allowing food particles to enter from stomach and pass into the jejunum, avoiding contact with pancreatic juices and digestive enzymes that have entered through the duodenum. It creates an artificial bypass until the chyme will exit the sleeve into the jejunum and therefore mimics the bypass





**Figure 9.** Duodenal-jejunal bypass liner.  
Source: Gong and Kim.<sup>40</sup>

portion of the Roux-en-Y gastric bypass. The most common theories for weight loss and glyce-mic control include enteric hormonal modulation and incretin theory, alterations in the gut micro-biota, and bile flow changes.<sup>46</sup> The first study was conducted by Rodriguez-Grunert and colleagues in Las Condes, Santiago de Chile. They per-formed a 12-patient prospective, open-label, sin-gle-center, 12-week study. The average percentage of excess weight loss was 23.6%, and all diabetic patients had improvements in diabetes with nor-mal fasting plasma glucose levels and decreased hypoglycemic medications.<sup>47</sup> A meta-analysis and systematic review by Jirapinyo and colleagues reviewed a total of 17 articles analyzing the effects of DJBL. Primary outcomes included glycemic control in obese patients with T2DM, and sec-ondary outcomes included weight loss and changes in gut hormones. On average, the device was implanted for 8 months with a decrease in HbA1c of 1.3%, and HOMA-IR decreased by 4.6 and fasting glucose decreased by 44.6 mg/dl. Additional outcomes included a BMI reduction of 4.1 kg/m<sup>2</sup>, a TWL of about 19%, and an excess weight loss of 37%. Changes in hormone regula-tion were elevations in GLP-1, PYY, and ghrelin and decreases in glucose-dependent insulintropic polypeptide (GIP). The most common SAEs noted were gastrointestinal bleeding and hepatic abscesses but were treated with supportive care.<sup>48</sup>

Further studies have evaluated the safety profile and adverse effects regarding the DJBL.<sup>49–51</sup> The FDA conducted a multicenter double-blind sham control trial in 2016 that was stopped early after a 3.5% incidence of hepatic abscess was diagnosed in the study population. A systematic review by Betzel and colleagues reviewed a total of 38 studies. In a total of 1056 patients, 891 experienced adverse events ranging from mild (76%), moderate (20%), to severe (4%). Approximately 25% of patients required early removal of the DJBL due to adverse events or inability to tolerate the device. The SAEs were hepatic abscess ( $n = 11$ ), gastrointestinal hemor-rhage ( $n = 8$ ), and esophageal perforation ( $n = 4$ ). It is believed that the anchor of the DJBL was responsible for a total 85% of SAEs.<sup>51</sup> Reported failure rates of early explantation have varied from 15% to 38%.<sup>52</sup> Therefore, it has yet to be approved in the United States but is commer-cially available in other countries.

### Conclusion

Endoscopic bariatric metabolic therapies have been proven to be safe and effective treatment options for patients with obesity. Additional endoscopic procedures are continuing to be developed and innovations in existing proce-dures have allowed for improved outcomes and decreased adverse effects. As advances in the field continue to emerge, further research stud-ies and randomized controlled trials are needed to better understand the safety profile and effi-cacy of these procedures. This review article summarizes the current evidence-based research studies and includes the outcomes and adverse effects of many of the EBMTs used throughout the world. Many of these procedures have shown to be effective for weight loss and in the reduc-tion of obesity-related comorbidities. These pro-cedures, in combination with lifestyle modifi-cations and dietary changes, can be promising alternatives to bariatric surgery for patients who have not had the opportunity to explore surgical weight loss options.

### Authorship

All authors worked in all four aspects of author-ship as per ICMJE guidelines.

### Funding

The authors received no financial support for the research, authorship, and/or publication of this article.



### Conflict of interest statement

The authors declared the following potential conflicts of interest with respect to the research, authorship, and/or publication of this article: Michel Kahaleh has done consulting work for Boston Scientific, Interscope Med, and Abbvie. He has received research grants from Boston Scientific, Emcision, Conmed, Pinnacle, Cook, Gore, Merit, and Olympus. The other authors have no conflict of interest to report.

### ORCID iD

Michel Kahaleh  <https://orcid.org/0000-0003-0836-6114>


### References

- Hales CM, Carroll MD, Fryar CD, *et al.* Prevalence of obesity among adults and youth: United States, 2015-2016. *NCHS Data Brief* 2017; 288: 1-8.
- Fock KM and Khoo J. Diet and exercise in management of obesity and overweight. *J Gastroenterol Hepatol* 2013; 28(Suppl. 4): 59-63.
- Aronne LJ, Wadden TA, Peterson C, *et al.* Evaluation of phentermine and topiramate versus phentermine/topiramate extended-release in obese adults. *Obesity* 2013; 21: 2163-2171.
- Torgerson JS, Hauptman J, Boldrin MN, *et al.* XENical in the prevention of diabetes in obese subjects (XENDOS) study: a randomized study of orlistat as an adjunct to lifestyle changes for the prevention of type 2 diabetes in obese patients. *Diabetes Care* 2004; 27: 155-161.
- Allison DB, Gadde KM, Garvey WT, *et al.* Controlled-release phentermine/topiramate in severely obese adults: a randomized controlled trial (EQUIP). *Obesity* 2012; 20: 330-342.
- Smith SR, Weissman NJ, Anderson CM, *et al.* Multicenter, placebo-controlled trial of lorcaserin for weight management. *N Engl J Med* 2010; 363: 245-256.
- Apovian CM, Aronne L, Rubino D, *et al.* A randomized, phase 3 trial of naltrexone SR/bupropion SR on weight and obesity-related risk factors (COR-II). *Obesity* 2013; 21: 935-943.
- Pi-Sunyer X, Astrup A, Fujioka K, *et al.* A randomized, controlled trial of 3.0 mg of liraglutide in weight management. *N Engl J Med* 2015; 373: 11-22.
- Jirapinyo P and Thompson CC. Endoscopic bariatric and metabolic therapies: surgical analogues and mechanisms of action. *Clin Gastroenterol Hepatol* 2017; 15: 619-630.
- Sullivan S, Edmundowicz SA and Thompson CC. Endoscopic bariatric and metabolic therapies: new and emerging technologies. *Gastroenterology* 2017; 152: 1791-1801.
- Sullivan S, Stein R, Jonnalagadda S, *et al.* Aspiration therapy leads to weight loss in obese subjects: a pilot study. *Gastroenterology* 2013; 145: 1245.e1-1252.e1.
- Thompson CC, Abu Dayyeh BK, Kushner R, *et al.* Percutaneous gastrostomy device for the treatment of class II and class III obesity: results of a randomized controlled trial. *Am J Gastroenterol* 2017; 112: 447-457.
- Nyström M, Machytka E, Norén, *et al.* Aspiration therapy as a tool to treat obesity: 1- to 4-year results in a 201-patient multi-center post-market European Registry Study. *Obes Surg* 2018; 28: 1860-1868.
- Mathus-Vliegen EMH and de Groot GH. Fasting and meal-induced CCK and PP secretion following intragastric balloon treatment for obesity. *Obes Surg* 2013; 23: 622-633.
- Mion F, Napoléon B, Roman S, *et al.* Effects of intragastric balloon on gastric emptying and plasma ghrelin levels in non-morbid obese patients. *Obes Surg* 2005; 15: 510-516.
- Gleysteen JJ. A history of intragastric balloons. *Surg Obes Relat Dis* 2016; 12: 430-435.
- ASGE Bariatric Endoscopy Task Force and ASGE Technology Committee, Abu Dayyeh BK, Kumar N, *et al.* ASGE Bariatric Endoscopy Task Force systematic review and meta-analysis assessing the ASGE PIVI thresholds for adopting endoscopic bariatric therapies. *Gastrointest Endosc* 2015; 82: 425-438.
- Courcoulas A, Abu Dayyeh BK, Eaton L, *et al.* Intragastric balloon as an adjunct to lifestyle intervention: a randomized controlled trial. *Int J Obes* 2017; 41: 427-433.
- Genco A, Bruni T, Doldi SB, *et al.* BioEnterics intragastric balloon: the Italian experience with 2,515 patients. *Obes Surg* 2005; 15: 1161-1164.
- Imaz I, Martínez-Cervell C, García-Alvarez EE, *et al.* Safety and effectiveness of the intragastric balloon for obesity. A meta-analysis. *Obes Surg* 2008; 18: 841-846.
- Goldstein DJ. Beneficial health effects of modest weight loss. *Int J Obes Relat Metab Disord* 1992; 16: 397-415.
- Vyas D, Deshpande K and Pandya Y. Advances in endoscopic balloon therapy for weight loss and

- its limitations. *World J Gastroenterol* 2017; 23: 7813–7817.
23. Mion F, Ibrahim M, Marjoux S, *et al.* Swallowable Obalon® gastric balloons as an aid for weight loss: a pilot feasibility study. *Obes Surg* 2013; 23: 730–733.
24. Sullivan S, Swain JM, Woodman G, *et al.* 812d The Obalon swallowable 6-month balloon system is more effective than moderate intensity lifestyle therapy alone: results from a 6-month randomized sham controlled trial. *Gastroenterology* 2016; 150: S1267.
25. Abu Dayyeh BK, Rajan E and Gostout CJ. Endoscopic sleeve gastropasty: a potential endoscopic alternative to surgical sleeve gastrectomy for treatment of obesity. *Gastrointest Endosc* 2013; 78: 530–535.
26. Li P, Ma B, Gong S, *et al.* Efficacy and safety of endoscopic sleeve gastropasty for obesity patients: a meta-analysis. *Surg Endosc* 2020; 34: 1253–1260.
27. Lopez-Nava G, Galvão MP, Bautista-Castaño I, *et al.* Endoscopic sleeve gastropasty for obesity treatment: two years of experience. *Arq Bras Cir Dig* 2017; 30: 18–20.
28. López-Nava Breviere G, Bautista-Castaño I, Fernández-Corbelle JP, *et al.* Endoscopic sleeve gastropasty (the Apollo method): a new approach to obesity management. *Rev Esp Enferm Dig* 2016; 108: 201–206.
29. Alqahtani A, Al-Darwish A, Mahmoud AE, *et al.* Short-term outcomes of endoscopic sleeve gastropasty in 1000 consecutive patients. *Gastrointest Endosc* 2019; 89: 1132–1138.
30. Storm AC and Abu Dayyeh BK. Endoscopic sleeve gastropasty for obesity: defining the risk and reward after more than 1600 procedures. *Gastrointest Endosc* 2019; 89: 1139–1140.
31. Sharaiha RZ, Kumta NA, Saumoy M, *et al.* Endoscopic sleeve gastropasty significantly reduces body mass index and metabolic complications in obese patients. *Clin Gastroenterol Hepatol* 2017; 15: 504–510.
32. Novikov AA, Afaneh C, Saumoy M, *et al.* Endoscopic sleeve gastropasty, laparoscopic sleeve gastrectomy, and laparoscopic band for weight loss: how do they compare? *J Gastrointest Surg* 2018; 22: 267–273.
33. Fayad L, Adam A, Schweitzer M, *et al.* Endoscopic sleeve gastropasty versus laparoscopic sleeve gastrectomy: a case-matched study. *Gastrointest Endosc* 2019; 89: 782–788.
34. Fiorillo C, Quero G, Vix M, *et al.* 6-month gastrointestinal quality of life (QoL) results after endoscopic sleeve gastropasty and laparoscopic sleeve gastrectomy: a propensity score analysis. *Obes Surg* 2020; 30: 1944–1951.
35. Espinós JC, Turró R, Mata A, *et al.* Early experience with the Incisionless Operating Platform™ (IOP) for the treatment of obesity: the primary obesity surgery endolumenal (POSE) procedure. *Obes Surg* 2013; 23: 1375–1383.
36. López-Nava G, Bautista-Castaño I, Jimenez A, *et al.* The primary obesity surgery endolumenal (POSE) procedure: one-year patient weight loss and safety outcomes. *Surg Obes Relat Dis* 2015; 11: 861–865.
37. Sullivan S, Swain JM, Woodman G, *et al.* Randomized sham-controlled trial evaluating efficacy and safety of endoscopic gastric plication for primary obesity: the ESSENTIAL trial. *Obesity* 2017; 25: 294–301.
38. Greenway FL, Aronne LJ, Raben A, *et al.* A randomized, double-blind, placebo-controlled study of gelesis100: a novel nonsystemic oral hydrogel for weight loss. *Obesity* 2019; 27: 205–216.
39. Huberty V, Machytka E, Boškoski I, *et al.* Endoscopic gastric reduction with an endoluminal suturing device: a multicenter prospective trial with 1-year follow-up. *Endoscopy* 2018; 50: 1156–1162.
40. Gong EJ and Kim DH. Small bowel endoscopic bariatric therapies. *Clin Endosc* 2018; 51: 425–429.
41. Breen DM, Rasmussen BA, Kokorovic A, *et al.* Jejunal nutrient sensing is required for duodenal-jejunal bypass surgery to rapidly lower glucose concentrations in uncontrolled diabetes. *Nat Med* 2012; 18: 950–955.
42. Rajagopalan H, Cherrington AD, Thompson CC, *et al.* Endoscopic duodenal mucosal resurfacing for the treatment of type 2 diabetes: 6-month interim analysis from the first-in-human proof-of-concept study. *Diabetes Care* 2016; 39: 2254–2261.
43. van Baar ACG, Holleman F, Crenier L, *et al.* Endoscopic duodenal mucosal resurfacing for the treatment of type 2 diabetes mellitus: one year results from the first international, open-label, prospective, multicentre study. *Gut* 2020; 69: 295–303.
44. Hadeji A, Huberty V, Lemmers A, *et al.* Endoscopic duodenal mucosal resurfacing for the treatment of type 2 diabetes. *Dig Dis* 2018; 36: 322–324.

45. Machytka E, Bužga M, Zonca P, *et al.* Partial jejunal diversion using an incisionless magnetic anastomosis system: 1-year interim results in patients with obesity and diabetes. *Gastrointest Endosc* 2017; 86: 904–912.
46. Ruban A, Ashrafian H and Teare JP. The EndoBarrier: duodenal-jejunal bypass liner for diabetes and weight loss. *Gastroenterol Res Pract* 2018; 2018: 7823182.
47. Rodriguez-Grunert L, Galvao Neto MP, Alamo M, *et al.* First human experience with endoscopically delivered and retrieved duodenal-jejunal bypass sleeve. *Surg Obes Relat Dis* 2008; 4: 55–59.
48. Jirapinyo P, Haas AV and Thompson CC. Effect of the duodenal-jejunal bypass liner on glycemic control in patients with type 2 diabetes with obesity: a meta-analysis with secondary analysis on weight loss and hormonal changes. *Diabetes Care* 2018; 41: 1106–1115.
49. Quezada N, Muñoz R, Morelli C, *et al.* Safety and efficacy of the endoscopic duodenal-jejunal bypass liner prototype in severe or morbidly obese subjects implanted for up to 3 years. *Surg Endosc* 2018; 32: 260–267.
50. Forner PM, Ramacciotti T, Farey JE, *et al.* Safety and effectiveness of an endoscopically placed duodenal-jejunal bypass device (EndoBarrier®): outcomes in 114 patients. *Obes Surg* 2017; 27: 3306–3313.
51. Betzel B, Drenth JPH and Siersema PD. Adverse events of the duodenal-jejunal bypass liner: a systematic review. *Obes Surg* 2018; 28: 3669–3677.
52. Maggi U, Formiga A and Lauro R. Hepatic abscess as a complication of duodenal-jejunal bypass sleeve system and review of the literature. *Surg Obes Relat Dis* 2016; 12: e47–e50.

Visit SAGE journals online  
[journals.sagepub.com/  
 home/cmg](http://journals.sagepub.com/home/cmg)

 SAGE journals