

Treatment Strategies and Challenges to Avoid Cerebrospinal Fluid Shunting for Pediatric Hydrocephalus

Young-Soo PARK¹

¹*Department of Neurosurgery and Children's Medical Center, Nara Medical University, Kashihara, Nara, Japan*

Abstract

Treatment for pediatric hydrocephalus aims not only to shrink the enlarged ventricle morphologically but also to create an intracranial environment that provides the best neurocognitive development and to deal with various treatment-related problems over a long period of time. Although the primary diseases that cause hydrocephalus are diverse, the ventricular peritoneal shunt has been introduced as the standard treatment for several decades. Nevertheless, complications such as shunt infection and shunt malfunction are unavoidable; the prognosis of neurological function is severely affected by such factors, especially in newborns and infants.

In recent years, treatment concepts have been attempted to avoid shunting, mainly in the context of pediatric cases. In this review, the current role of neuroendoscopic third ventriculostomy for noncommunicating hydrocephalus is discussed and a new therapeutic concept for post intraventricular hemorrhagic hydrocephalus in preterm infants is documented. To avoid shunt placement and achieve good neurodevelopmental outcomes for pediatric hydrocephalus, treatment modalities must be developed.

Keywords: pediatric hydrocephalus, VP shunt, neuroendoscopy, fibrinolytic therapy, ventricular lavage

Introduction

Hydrocephalus is the most common disease in the field of pediatric neurosurgery and requires surgical treatment in most cases. Treatment for pediatric hydrocephalus aims not only to maintain intracranial pressure within the normal physiological range but also to create an intracranial environment that provides good neurocognitive development. Furthermore, various related problems must be appropriately treated over a long period postsurgery.

Many different types of diseases cause hydrocephalus, but almost all cases can be treated via a ventriculoperitoneal (VP) shunt surgery, regardless of the cause. A VP shunt has been used as the standard treatment for several decades.¹⁾

Nevertheless, shunt-related complications such as shunt dysfunction and shunt infection are unavoidable, and the neurological functional outcome is severely affected by these complications, particularly in neonates and infants.²⁻⁴⁾

In recent years, new treatment concepts have been at-

tempted to prevent the introduction of a VP shunt, mainly in pediatric cases.⁵⁻⁷⁾ In this paper, the current practices and unsolved problems in pediatric hydrocephalus are discussed. The study was conducted according to the research ethics committee guidance, and informed consent was obtained from all the participants.

Can a VP Shunt Be Considered the Gold Standard to Treat Pediatric Hydrocephalus?

Most cases of pediatric hydrocephalus can be treated with a VP shunt, with the only exception of pan-peritonitis caused, for example, by gastrointestinal perforation. Therefore, can we simply think that a VP shunt should be considered the gold standard to treat pediatric hydrocephalus? In our opinion, the treatment best suited for the growth and development of a child's brain should be considered. Certainly, the surgical procedure of placing the VP shunt is not a difficult technique, but maintaining shunt function for long periods of time is complicated and difficult.

Received March 29, 2022; Accepted June 14, 2022

Copyright © 2022 The Japan Neurosurgical Society

This work is licensed under a Creative Commons Attribution-NonCommercial-NoDerivatives International License.

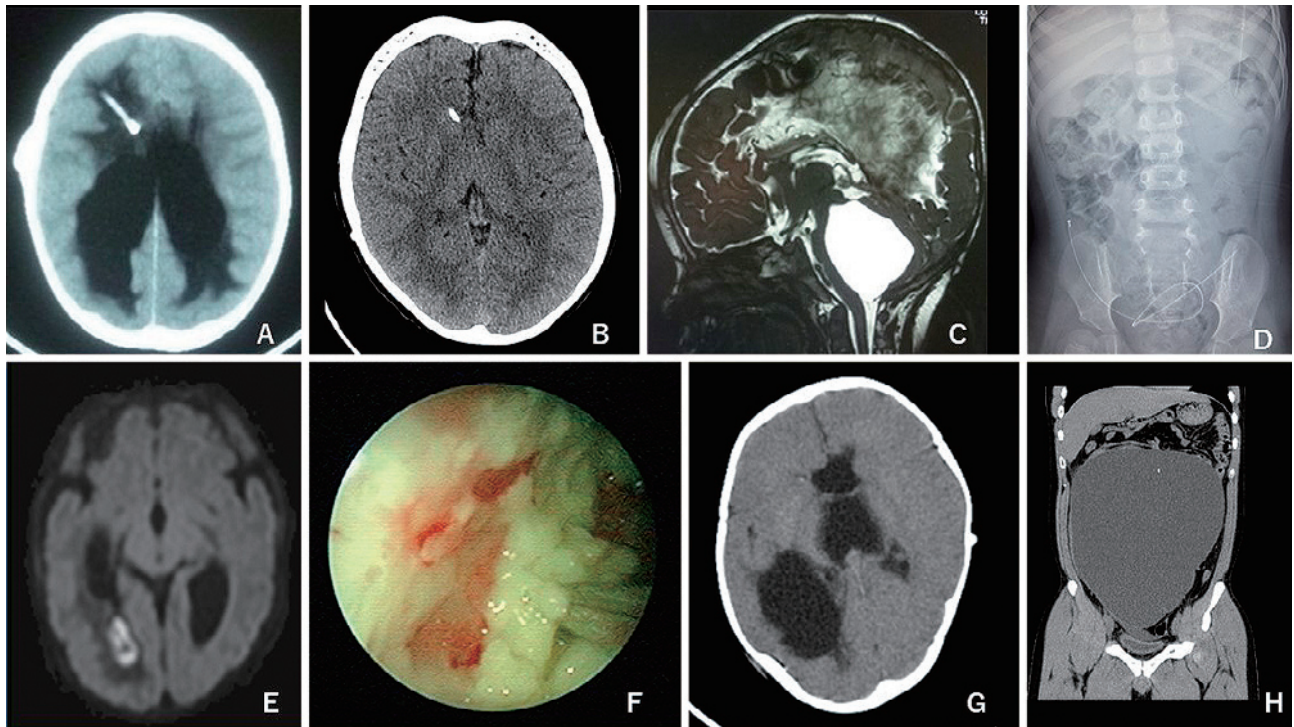


Fig. 1 Shunt-related complications.

A: shunt malfunction due to ventricular catheter occlusion.

B: slit ventricle syndrome.

C: isolated fourth ventricle dilatation.

D: shunt malfunction due to damaged peritoneal catheter.

E: ventricle abscess associated with shunt infection.

F: neuroendoscopic surgery image for intraventricular abscess caused by shunt infection.

G: multilobulated hydrocephalus after shunt infection.

H: shunt malfunction due to a large peritoneal cyst.

The incidence of shunt-related complications is not negligible in children, especially infants, and each complication incurs brain damage (Fig. 1).^{2-4,8-11} Additionally, as several clinical cases have shown, shunt infection in infancy often causes irreversible and catastrophic brain damage. Even in the case of Sylvian aqueduct stenosis, which should yield good neurocognitive outcomes, shunt infection and subsequent repeated revision surgeries cause severe mental retardation (Fig. 2).

Based on past clinical studies, shunt dysfunction in childhood hydrocephalus has been reported to affect 40% of cases within 1 year and 50% of cases within 2 years. The famous retrospective study of a total of 1719 patients treated at the Hospital for Sick Children (Toronto) and l'Hôpital des Enfants Malades (Paris) reported that the incidence of predicted shunt dysfunction (excluding shunt infections) would reach 81%, 12 years after shunting.²⁾

Importantly, in routine clinical practice, diagnosing shunt dysfunction in pediatric cases is challenging.^{12,13)} Nonspecific symptoms are often caused by shunt dysfunction. The possibility of shunt dysfunction should always be kept in mind when assessing pediatric patients with a VP

shunt placement. A misdiagnosis carries the risk of permanent neurological deficits and death in the worst scenario.^{8,10,14)} Delaying the identification of shunt dysfunction when common cold and gastroenteritis are diagnosed is not uncommon in routine clinical practice.

By contrast, the frequency of shunt infections varies from hospital to hospital but is generally approximately 5%-10%.¹⁵⁾ Shunt infection rates are even higher in children, especially in newborns and infants. Shunt infections lead to the need for additional multiple surgical treatments and long-term hospitalizations. The development of an intraventricular empyema derived from shunt infection not only causes serious damage to the brain parenchyma but also forms a complex multilocular ventricle.

Additionally, there are peculiar types of shunt-related complications that are difficult to treat. Isolated fourth ventricle and slit ventricle syndrome are rare complications in adults but may be encountered in pediatric cases.

The most important issue to consider in shunt-related complications is that shunt dysfunction can lead to progressive impairment of consciousness and, in the worst scenario, can result in sudden death.^{8,10,14,16)} Patients, espe-

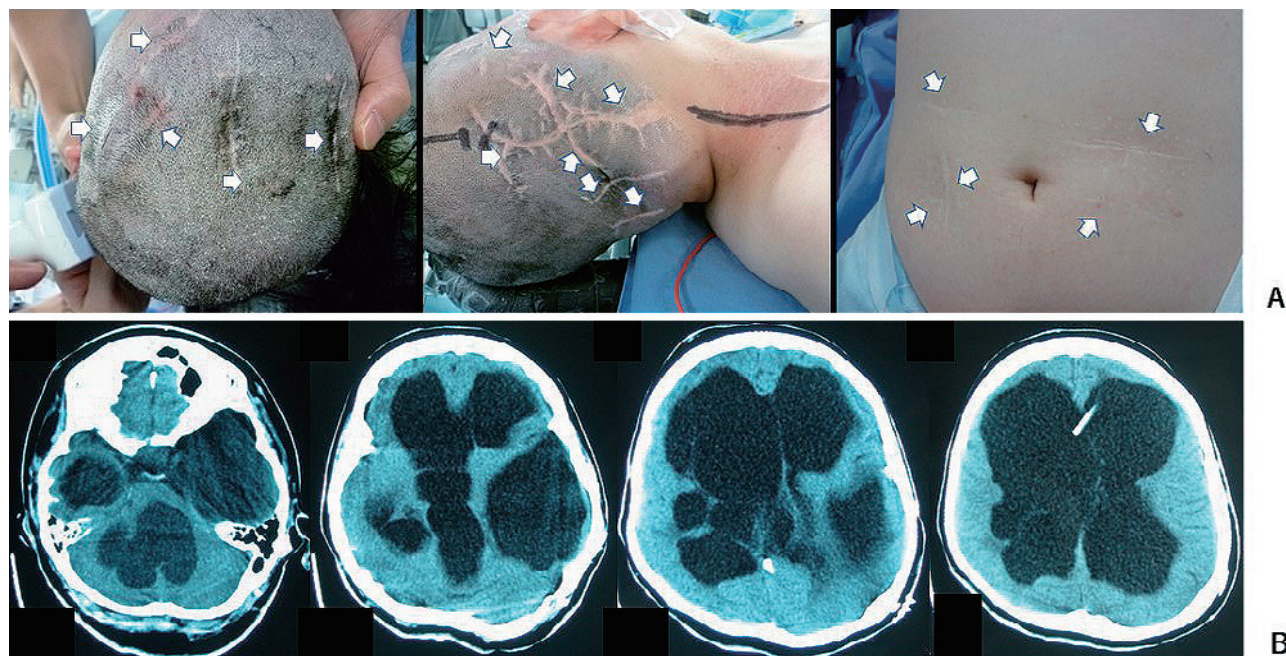


Fig. 2 A 34-year-old woman, diagnosed with congenital Sylvian aqueduct stenosis, received a VP shunt at 3 months old. **A:** Multiple surgeries have been carried out due to repeated shunt-related complications, including shunt infections. Arrows indicate wound sites during surgery. **B:** Head CT reveals complicated ventricles. Consequently, she suffers from severe mental retardation.

cially those who underwent a VP shunt surgery decades ago without any problems, are not aware that shunt dysfunction could lead to such a worst-case scenario. In a report studying deaths during a long-term follow-up in pediatric patients with a VP shunt, 23 of the 53 deaths were shunt-related deaths, 18 were shunt infections, and five were cases of acute deterioration resulting from shunt dysfunction.¹⁴⁾

Placing a foreign substance into a living body for a lifetime causes various physical problems and mental stress. For example, it is not uncommon for children who have undergone VP shunt surgeries for hydrocephalus to grow into adults while maintaining good neurodevelopmental function. Furthermore, attention should be paid to shunt management during pregnancy in female patients.¹⁷⁾ Even if a peritoneal catheter is placed, giving birth safely with careful management is possible; however, there remains a certain risk of shunt dysfunction during pregnancy. Several studies have reported cases of VP shunt dysfunction due to increased intra-abdominal pressure during pregnancy.¹⁸⁻²⁰⁾

As mentioned above, the placement of a VP shunt as a treatment for pediatric hydrocephalus raises concerns regarding various shunt-related adverse events in the long-term. Even with the development of shunt catheters made of new materials and shunt valves such as antigravity systems and antisiphon devices,²¹⁾ shunt-related complications are impossible to eradicate. Hence, a new alternative method to avoid shunt dysfunction is genuinely required

in the treatment of pediatric hydrocephalus. Specifically, "No shunt is the best shunt."

Neuroendoscopic Third Ventriculostomy for Pediatric Hydrocephalus

1. Historical review of endoscopic ventriculostomy

Neuroendoscopy has its origins in 1910 when the urologist Lespinasse, using a cystoscope, made the first attempt to treat hydrocephalus by destroying the choroid plexus.²²⁾ Later, in 1922, Dandy attempted to relieve hydrocephalus via the subfrontal approach to the anterior wall (lamina terminalis) of the third ventricle using a small cystoscope.²³⁾ Around the same time, Mixter performed the first-ever third ventriculostomy in the treatment of a non-communicating hydrocephalus via ureteroscopy in 1923. Guio performed the now common endoscopic method of opening the floor of the third ventricle in 1962. The endoscope allowed Guiot to clearly visualize a tumor that was attached to the foramen of Monro, alongside providing a clear view of the lateral ventricle. Using a soft spatula, he was able to push the tumor into the third ventricle and perforate its floor. The next generation of neuroendoscopy emerged in the 1970s based on a major contribution by Hopkins whose innovative work paved the path for the development of rigid and flexible endoscopes used today. Around the same time, Griffith recommended the endoscopic procedure as "a first-line treatment for childhood hydrocephalus." He used Hopkins' rigid endoscope to per-

form a third ventriculostomy as well as choroid plexus coagulation to treat hydrocephalus.^{24,25)}

In the last 10 years, high-resolution endoscopic images have further extended the usefulness of endoscopic third ventricle fenestration (ETV). A major turning point was the concept of the ETV success score (ETVSS) proposed by Kulkarni et al.^{6,26)} Based on this concept, neurosurgeons can now perform ETV surgery with confidence. Consequently, we have made great strides in neuroendoscopic treatment for pediatric hydrocephalus.

Furthermore, Warf et al. reported a combination of both ETV and choroid plexus cauterization (CPC) to achieve better results in the treatment of hydrocephalus.²⁷⁻²⁹⁾

Thus, neuroendoscopic treatment for pediatric hydrocephalus reached a new milestone.

2. Therapeutic effects of ETV for hydrocephalus

To avoid VP shunt placement and successfully treat pediatric hydrocephalus with ETV, the pathophysiology of hydrocephalus must be well understood. Three factors have been classically considered for decades: cerebrospinal fluid (CSF) production, circulation, and absorption. Nevertheless, the recent accumulation of knowledge about hydrodynamic theory for hydrocephalus has laid forth more complex pathologies.³⁰⁾

In the latest paper, Thomale simplified the concept based on seven factors of CSF dynamics. The seven factors, including pulsatility, CSF production, major CSF pathways, minor CSF pathways, CSF absorption, venous outflow, and respiration, may have different degrees of relevance and may also overlap for the individual hydrocephalic condition.³¹⁾ The effect of ETV is to solve the problems related to the CSF major pathways and pulsatility. Specifically, ETV has two main effects, i.e., restoring CSF communication between the ventricle and the subarachnoid space and reducing transmantle pulsatile stress by increasing the compliance of the ventricular wall.^{31,32)}

3. Endoscopic treatment for hydrocephalus based on ETV success scores

ETV surgery has been established and detailed procedures are left to other surgical textbooks, but effective surgical results depend on how adequately the Liliequist membrane is opened and the naked basilar artery visualized.³³⁾

It is largely because of the concept of the ETVSS that we can actively conduct ETV for the treatment of pediatric hydrocephalus with confidence. Of course, ETVSS does not determine the indication for surgery, but it is an extremely practical rule that can predict the success rate of surgery based on only three factors, namely, age, cause of hydrocephalus, and history of shunt surgery.⁶⁾

The results of the intergroup comparison of treatment survival between ETV and VP shunt in each score group were as follows. For the high ETVSS group (score ≥ 80),

ETV appeared to have a low risk of failure early after surgery; for the moderate ETVSS group (score 50-70), ETV appeared to have a high initial failure rate. However, after approximately 3 months, the instantaneous risk of ETV failure became slightly lower than shunt failure, and for the low ETVSS group (score ≤ 40), the initial risk of ETV failure was much higher than the risk of VP shunt failure; moreover, the instantaneous risk of ETV failure was lower than the risk of shunt failure at approximately 6 months following surgery. In all three score groups, the risk of ETV failure gradually decreased compared with the risk of VP shunt failure as the time from surgery increased. In the best candidate (ETVSS ≥ 80), the risk of ETV failure was lower than the risk of VP shunt failure immediately after surgery, whereas for the less-than-ideal candidates (ETVSS ≤ 70), the risk of ETV failure was initially higher than the risk of VP shunt failure and only became lower after a period of 3-6 months following the surgery.

Kulkarni thereafter confirmed the reliability of ETVSS by comparing it to the actual success rate in 322 cases of 15 papers reported in the last 20 years. The predicted ETVSS for each paper was very consistent with the actual ETV success rate reported in each paper. The overall mean predicted ETVSS was 57.9%, which was almost the same as the actual ETV success rate of 59.2%.²⁶⁾

Later, a series of papers discussing the effectiveness of ETVSS were published, highlighting the utility of ETV in the treatment of pediatric hydrocephalus.

4. Factors reducing the success rate of ETV

The factors that reduce the success rate of ETV include infants under 6 months of age, postinfection, and intraventricular hemorrhage (IVH);⁶⁾ it is necessary to understand why ETV results in unsuccessful outcomes.

As is widely known, ETV during infancy for noncommunicating hydrocephalus due to cerebral aqueduct stenosis and obstruction of the outlet of the fourth ventricle does not yield the same effect as in older children. The most obvious anatomical difference in infancy is the soft calvaria cavity with an open fontanelle that allows for elastic volume changes in the cranial compartment, which primarily disappears in the first year of life. Additionally, arachnoid granulation is not present in early infancy, which means that CSF absorption is primarily responsible for the minor pathway.^{30,31,34)} As mentioned earlier, the effect of ETV is both to restore CSF communication and to reduce transmantle pulsatile stress; hence, early infancy is a period of special circumstances in which neither is achieved.

Next, postinfectious hydrocephalus impairs the effectiveness of ETV mainly due to tough adhesive arachnoiditis in the basal cistern. Similarly, in hydrocephalus that occurs after IVH, arachnoid thickening in the basal cistern is remarkable. ETV is unlikely to be successful because of multiple arachnoid adhesions in the prepontine cistern. Al-

though not listed on the ETVSS, the success rate of ETV is low even when malignant brain tumors are disseminated for the same reason.

5. Upward herniation following ETV

ETV has been widely introduced as an effective and safe treatment for obstructive hydrocephalus associated with posterior fossa and pineal tumors.³⁵⁻³⁷⁾ One of the characteristics of pediatric brain tumors is that tumors are likely to develop at these sites. In such cases, hydrocephalus can be cured by removing the tumor by emergency surgery and releasing the obstruction mechanism of the CSF tract;^{38,39)} however, performing highly invasive tumor removal surgery as an emergency operation is often difficult. CSF management by external ventricular drainage is a simple treatment method; nevertheless, in younger children, there is a risk of excessive drainage of CSF due to crying and anger; moreover, sedating children for a long period of time is challenging.

Certainly, careful surgical intervention is required, but ETV can avoid these risks and improve obstructive hydrocephalus. Nonetheless, tumors more than 4 cm in diameter that extend near the tentorial notch and severe hydrocephalus are at risk of ascending hernia,³⁵⁾ and high malignancy tumors such as AT/RT (atypical teratoid/rhabdoid tumor) can cause intratumoral hemorrhage by exacerbating the condition of ascending hernia further (Fig. 3).

Basilar artery injury and hypothalamic damage are generally known as serious complications of ETV, but this dangerous complication is less well known in cases of severe hydrocephalus associated with posterior fossa tumor.

6. Late rapid deterioration following ETV

The placement of a VP shunt for childhood hydrocephalus requires careful follow-up for long-term shunt-related complications, especially in the acute phase. In general, patients and caregivers are repeatedly informed regarding the sudden changes that can occur when the shunt system is occluded.

By contrast, the risk of rapid deterioration in the late stage after successful ETV is not widely recognized. Three deaths due to late rapid deterioration after ETV were first reported by Hader and Drake et al. in 2002,⁴⁰⁾ followed by an international collaborative study in 2006, for a total of 16 cases.⁴¹⁾ The outcome was extremely poor; 13 patients died, one patient was in a vegetative state, one patient was mildly disabled, and one was alive and well. Late rapid deterioration is a rare but lethal complication of ETV. The mechanism remains unclear, but the main cause may be due to the formation of a gliotic scar over the stoma.⁴¹⁾ Clinical deterioration can occur long after ETV surgery (Fig. 4).

Patients and caregivers should be educated about this potential complication. Neurosurgeons must be aware that late rapid deterioration is an even more important issue,

as patients and caregivers of children treated with ETV are less concerned about complications as compared with the period during VP shunt placement.⁴²⁾ Although placing a ventricular access device at the same time as the ETV procedure may be an effective measure,⁴¹⁾ the ventricular access device is not placed for rare contingencies in most cases.

7. Functional outcomes of ETV-treated pediatric hydrocephalus

Since the purpose of treatment for pediatric hydrocephalus is to create an intracranial environment that provides the best neurocognitive development while discussing the success or failure of ETV, it makes no sense to purely discuss the fact that the progression of ventricular enlargement is suppressed without the need for additional treatment.

Usually, the decrease in ventricular size is smaller and slower following ETV as compared with a VP shunt. Moreover, it is not uncommon for morphological changes to cease with a slight reduction in ventricular size. This is a significant difference compared with VP shunt treatment. Nevertheless, it is more important to determine whether good neurocognitive function can be obtained in such a condition.⁴³⁾

In a report assessing the quality of life after ETV and VP shunt by Kulkarni,^{44,45)} treatment by ETV was associated with significantly higher scores in physical, cognitive, and social-emotional health, without adjustment for any confounders. Additionally, there was no significant difference in any outcome measure after multivariable adjustment. The researchers concluded that treatment via ETV or CSF shunts did not appear to be associated with a substantial difference in quality of life results after adjusting for prognostic factors. The average age at the time of surgery was 66.9 months for ETV and 17 months for VP shunt, and the patients undergoing ETV had more cerebral aqueduct shunts and brain tumors, whereas those undergoing VP shunt surgeries had myelomeningocele (MMC) and premature IVH; this should be considered when examining the functional treatment outcomes.

In a randomized study limited to patients with aqueduct stenosis who underwent surgery at younger than 24 months, the overall health and quality of life were found to be high, with no significant differences between those treated initially with ETV or VP shunts.⁴⁶⁾

Presently, there are no large-scale reports of long-term functional prognosis in various diseases other than aqueduct stenosis; therefore, ETV should be actively performed only in cases with high ETVSS.

8. CPC as further advanced treatment

Given that the choroid plexus was removed in the early history of hydrocephalus treatment,²²⁾ it is interesting that CPC is drawing attention once again. Several prospective

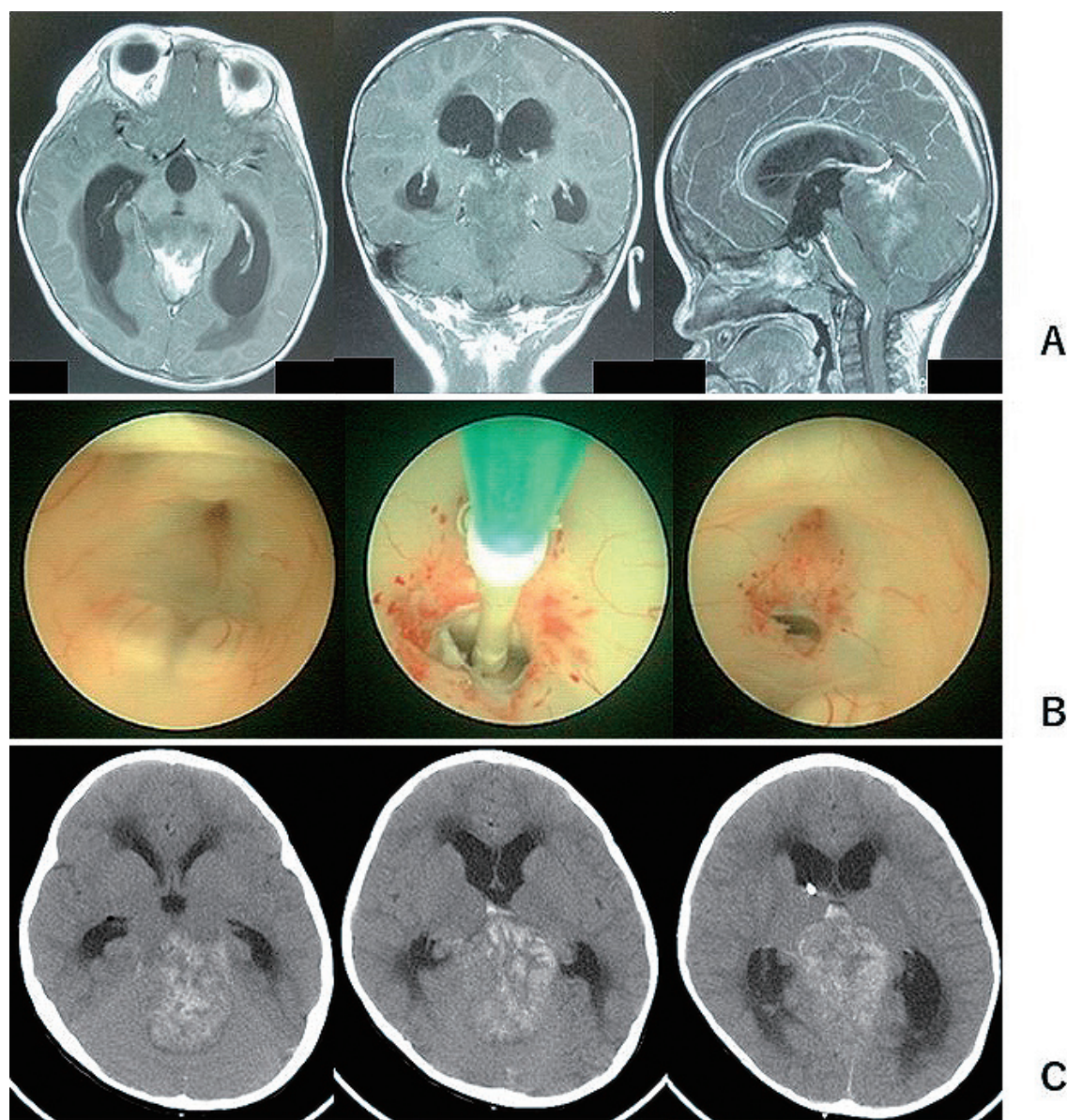


Fig. 3 A 1-year-and-9-month-old child with AT/RT.

A: The posterior fossa tumor with hydrocephalus; ETVSS was 80.

B: ETV minimized the outflow of CSF and was completed without any problems.

C: Consciousness impairment occurred after ETV, and head CT revealed upward herniation with intratumoral hemorrhage.

studies have already been conducted to discuss the effectiveness of CPC treatment besides ETV.⁷⁾

One of the most famous reports mentioning CPC includes the documentation of endoscopic treatment for infant hydrocephalus in Uganda.²⁷⁻²⁹⁾ As is widely known, Warf has practiced a great number of endoscopic surgeries for pediatric hydrocephalus with various pathologies. In cases in which ETV alone did not work, he has been aggressively trying to append CPC at the same time. To assess the results of CPC combined with ETV (CPC + ETV) and ETV alone, he conducted a prospective study in which 266 participants received the ETV + CPC combination pro-

cedure and 284 received only ETV. Overall, the success rate of ETV + CPC (66%) was superior to that of ETV alone (47%) among infants under 1 year of age. The ETV + CPC combined procedure was superior in patients with an MMC (76% compared with 35% success) and those with non-postinfectious hydrocephalus (70% compared with 38% success). Although there was no difference between the two procedures in patients aged at least 1 year, ETV + CPC was more successful than ETV alone in infants under 1 year of age.²⁷⁾

Further clinical studies have been conducted to consider whether treatment results in special circumstances, such

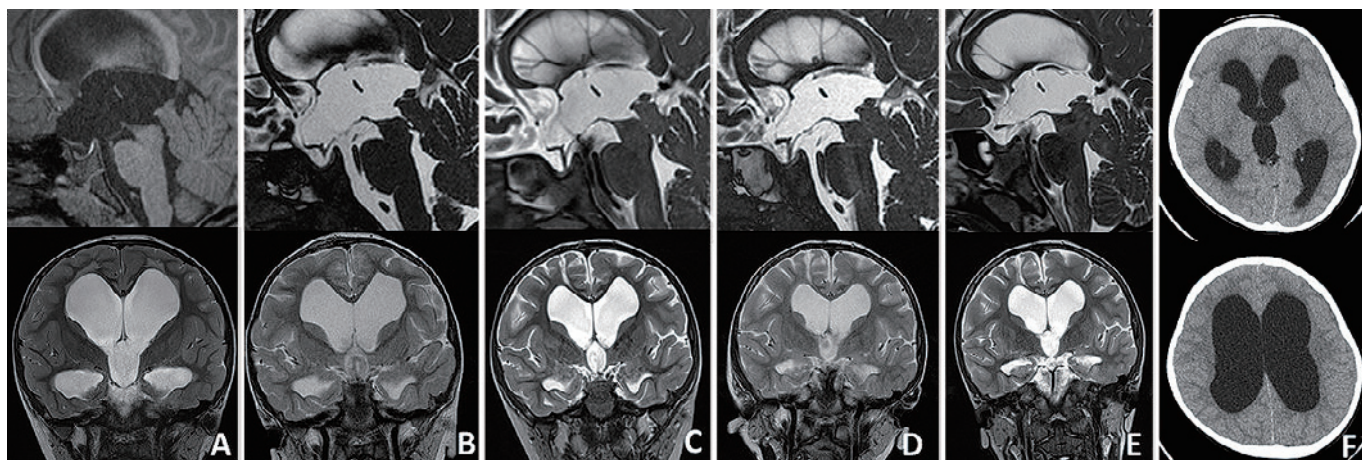


Fig. 4 A 5-year-old girl with slowly progressing hydrocephalus.

A: MRI scan reveals a marked triventriculomegaly, diagnosing noncommunicating hydrocephalus due to Sylvian aqueduct stenosis; ETVSS was 80.

B: One week following ETV, ventricular enlargement improved, and stoma patency was confirmed.

C: Three months after ETV, the patency of the stoma became somewhat obscure, but ventricular enlargement further improved.

D: Nine months after ETV, no patency of stoma was confirmed on MRI images, but ventricular enlargement did not worsen.

E: Twenty months after ETV, no patency of the stoma was confirmed in the same way, but the size of the ventricles remained unchanged. Although morphological patency of the stoma cannot be confirmed on MRI images, the function of the stoma might have remained slightly.

F: Two years and three months after the ETV surgery, she was fine until lunch, but after vomiting many times from around 6 pm onward, she suddenly fell into a coma. Hydrocephalus was rapidly progressing and worsening. She passed away without the effect of emergency treatment.

as an inadequate supply of medical resources and difficulty in obtaining opportunities for reoperation and regular outpatient treatment, are as applicable as in North American countries.⁴⁷⁾

A prospective study conducted by the Hydrocephalus Clinical Research Network reported that ETV + CPC was found to have significantly higher failure rates than shunt placement, and ETV + CPC had a similar failure rate to that of ETV alone.⁷⁾ Given the fact that half of the patients had ETVSS < 50 and more than half had MMC or IVH as the cause of hydrocephalus, there might be subgroups who would benefit from the addition of CPC.⁴⁸⁾ A systematic review and meta-analysis based on five studies, including two prospective and three retrospective studies, representing a total of 963 patients, failed to find any overall benefit to the addition of CPC to ETV. Overall, there was no significant difference in success rates between ETV and ETV + CPC.⁴⁹⁾

After analyzing the above clinical reports, it can be concluded that performing ETV based on the principles of ETVSS is logically and ethically acceptable. Nevertheless, it might be reckless to proactively try additional CPC treatment without considering the reliable effects of the VP shunt.

Indication for CPC should be considered only for special pathological conditions such as hydranencephaly, where good brain function development cannot be expected, in

cases where there is excessive production of CSF from the choroid plexus, and in cases where it is impossible to place a catheter due to infection.

Furthermore, how the artificial destruction of the physiological CSF production function in early childhood could influence an individual over the course of their entire lifetime has not been fully understood; this perspective remains a major unanswered issue.^{50,51)}

9. Removal of previous CSF shunts and ETV

Recently, active attempts to withdraw from CSF shunt dependence have become possible, even in the case of pediatric hydrocephalus with longstanding shunt placement.⁵²⁻⁵⁶⁾ ETV may be a useful strategy for shunt dysfunction in carefully selected pediatric patients, which can boast similar effectiveness to initial ETV.⁵⁴⁾ Besides ETV being adapted as an emergency procedure for shunt dysfunction, it can be used intentionally.^{52,53)} Specifically, ETV can be used instead of shunt revision surgery following abdominal catheter shortening. In the case of long-term CSF shunt placement for pediatric hydrocephalus, it is traditionally accepted that CSF absorption is completely shunt dependent; however, hydrocephalus can be controlled via ETV alone in not a few cases, including in patients who were previously shunted for decades.⁵⁷⁾

In infancy, CSF shunts have been inevitably selected for hydrocephalus associated with aqueductal stenosis and

myelomeningocele. Shunt removal consideration by pediatric neurosurgeons generally occurs during school age. Permanent placement of foreign materials in the body can induce psychological stress as pediatric patients grow up and may increase the risk of complications during pregnancy for female patients.

However, not all patients can successfully withdraw from shunt placement, so it is imperative to understand the pathophysiology of each individual hydrocephalus case to ensure that removal is feasible. The presence of CSF flow obstruction on MRI must be assessed. Additional laborious management, such as external drainage conversion of the abdominal catheter, may also be required to properly evaluate hydrocephalus. Furthermore, it is necessary to understand the concept of an adaptation period after ETV.^{52,58)}

Challenging Attempts to Treat Post Intraventricular Hemorrhagic Hydrocephalus (PIVHH) in Neonates

1. Germinal matrix hemorrhage

IVH occurs mainly in premature infants but rarely in full-term infants. Particularly, IVH occurs predominantly in very low-birth-weight infants (VLBWIs; <1500 g at birth) and extremely low-birth-weight infants (ELBWIs; <1000 g at birth) within 72 h after delivery.⁵⁹⁻⁶¹⁾ The pathophysiological factors of IVH in preterm infants are multifactorial and complex.^{59,61,62)} IVH is primarily caused by unstable alterations in cerebral blood flow to the microvasculature in the germinal matrix (GM). The GM microvasculature is fragile and easily vulnerable to hemorrhage. The hemorrhaged blood easily penetrates into the lateral ventricle and is clinically recognized as IVH.⁶³⁾ Subsequent progressive ventricular dilation after IVH causes hydrocephalus and requires neurosurgical treatment.^{61,64)}

Temporary treatments include repeated lumbar punctures, repeated tapping through a ventricular access device, external ventricular drain (EVD), and a ventriculosubgaleal (VS) shunt. However, these modalities ultimately require permanent VP shunt placement in 60%-87% of clinical cases in LBWIs.⁶⁵⁻⁶⁷⁾

Presently, there are two challenging treatment modalities for PIVHH in neonates as an advanced treatment concept to avoid CSF shunts and improve neurological prognosis. The first one is fibrinolytic therapy, and the other is endoscopic ventricular lavage.

This chapter provides an overview of each treatment method.

2. Fibrinolytic therapy that changed from tPA to urokinase

Although the guidelines published in 2014 indicated that intraventricular thrombolytic agents, including tissue plasminogen activator (tPA), urokinase (UK), or streptokinase

(SK), are not recommended as methods to reduce the need for VP shunt placement in premature infants with PIVHH,⁶⁸⁾ the latest clinical study reports demonstrate the need to reconsider the usefulness of fibrinolytic therapy. To discuss the usefulness of fibrinolytic therapy, the specific contents of the treatment and its transition must be understood.

The first fibrinolytic treatment for PIVHH in preterm infants was reported by Whitelaw et al. using SK,⁶⁹⁾ who sought to carry out an epoch-making fibrinolytic clinical study called the DRIFT (drainage, irrigation, and fibrinolytic therapy) using tPA.⁷⁰⁻⁷²⁾ In the Phase 1 DRIFT trial, they reported a significant reduction in shunt requirements and good functional outcomes at 12 months. Seventeen of 23 survivors (74%) did not require a VP shunt. Of the 19, eight were normal, seven (37%) had a single disability, and four (21%) had multiple disabilities affecting their prognosis of developing a neurodevelopmental disorder.⁷⁰⁾ Nevertheless, a following prospective randomized control study revealed that the incidence of shunt surgery and death was not reduced in the DRIFT group compared with the standard treatment group (44% vs 50%), and a high incidence of secondary IVH (35%) was observed as a fundamental factor undermining the utility of fibrinolysis therapy.⁷¹⁾ The third report assessed functional outcomes at 2 years of age. The incidence of death or severe disability was significantly lower in the DRIFT group compared with the standard treatment group (54% vs 72%). Additionally, the incidence of severe cognitive disability was significantly reduced (31% vs 59%). The Median Mental Development Index was 68 with DRIFT and 50 with standard care. A trend toward a reduction in severe sensorimotor disability was observed, but this clinical improvement did not reach statistical significance.⁷²⁾ To summarize the DRIFT trial, no significant effect was obtained on VP shunt avoidance, but it was shown to be effective in improving the neurological functional prognosis.⁷³⁾ The problem to be solved remains on how best to control secondary IVH. Nevertheless, for a long time, it has been established that fibrinolytic therapy has been ignored because of the unacceptable adverse events of secondary IVH in the DRIFT trial.

Conversely, there have been few reports of fibrinolytic therapy with UK. Hudgins reported that shunt requirements were reduced in the low-dose group, and they also observed a decrease in the requirements for shunt revision surgery.⁷⁴⁾ According to Hansen's report, all infants required shunt surgery, but fibrinolysis with UK was considered a safe treatment without serious complications.⁷⁵⁾ Although there are limited data on UK therapy, the risk of secondary bleeding remains low.

After a long silence, a preliminary clinical study was reported reconsidering the utility of fibrinolytic therapy. Park et al. selected UK as a fibrinolytic agent instead of tPA, prioritizing the concept of minimizing hemorrhagic complications, and reported a unique treatment of intermittent

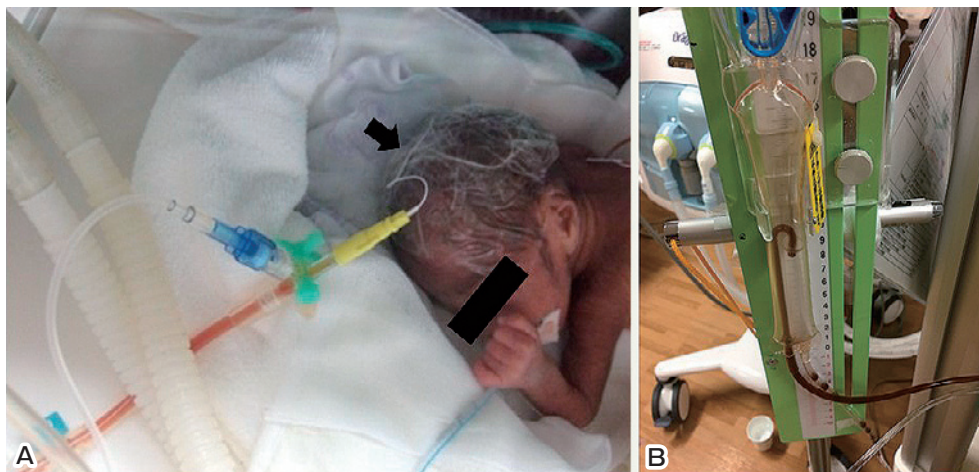

Fig. 5 Fibrinolytic therapy with urokinase.

A: A very thin catheter is used for external ventricular drainage (EVD; indicated by the arrow). Urokinase infusion syringe pump is connected to a three-way cock.

B: Dissolution of the hematoma by fibrinolytic therapy and excretion through the cerebrospinal fluid.

administration at low doses of UK combined with continuous ventricular drainage in 2021⁷⁶⁾ (Fig. 5). Their therapy consisted of continuous EVD management using a small-diameter catheter and fibrinolytic therapy combined with UK (single dose 6000 UI) injection into the lateral ventricle. The frequency of UK injection was initially limited to four times a day for a maximum of 5 days. After the safety of fibrinolysis with UK was confirmed in serial cases, the frequency was increased to eight times per day, and the fibrinolytic treatment was continued for up to 14 days in severe cases.⁷⁶⁾

Park et al. reported to have significantly reduced shunt requirements and improved neurodevelopmental outcomes without secondary IVH or infection. Eighteen of the 21 (86%) premature infants who underwent EVD management of early-onset IVH and actively received fibrinolysis with intraventricular administration of UK did not require a VP shunt. Additionally, all of these cases were Grade 4 IVH, and most of them were ELBWIs. More notably, the treatment group had no serious complications including secondary bleeding and infection. A good outcome was achieved in the early treatment group with fibrinolytic therapy (13/17, 76.5%).⁷⁶⁾

Note that intraventricular administration of UK is an off-label use, so deliberation and approval by the Institutional Ethics Committee are essential.

As in adults, regaining physiological CSF circulation by dissolving and removing intraventricular hematomas and fibrin debris from the early stages of IVH onset should improve hydrocephalus without shunt placement. Furthermore, it might be important to prevent adhesions and fibrosis in the subarachnoid spaces such as basal cisterns.⁶¹⁾

3. Neuroendoscopic lavage (NEL)

NEL procedures have been conducted mainly for purulent meningitis and intraventricular empyema and are sometimes applied for IVH in adults but not in infants. NEL for the treatment of PIVHH in neonates was first reported in 2014 by Schulz and Thomale et al.⁷⁷⁾

The primary advantage of NEL is that the progress of hematoma removal and control of the bleeding site are directly visible. Residual hematomas and floating degradation products can then be removed via irrigation or active aspiration. Undoubtedly, NEL is the most effective method in terms of effectively removing hematomas. This has been introduced in adult IVH and intraventricular abscess surgery. As most of the infants treated are VLBWI and in some cases ELBWIs, NEL treatment requires careful and experienced neuroendoscopic surgery and staff from an advanced surgical team.

In the first report,⁷⁷⁾ 19 neonates with PIVHH underwent NEL for the removal of intraventricular blood remnants. The average body weight at birth was 1036 g (500-3460 g) and the average weight at surgery was 1475 g (750-3645 g). Regarding the severity of IVH, two cases were grade II, 12 cases were grade III, and three cases were grade IV. Eleven of 19 (58%) infants required a later shunt insertion, as compared with 100% of infants who were conventionally treated. They then increased the number of cases to 45 and reported neurocognitive results 2 years after treatment.⁷⁸⁾ One died, and two were lost to follow-up. A total of 26 of 44 patients (59%) became shunt dependent. Additionally, 30% of patients revealed a fairly normal neurocognitive development, and 78% were able to walk independently or with minimal assistance. Based on MR volume measurements, a greater brain volume was positively correlated with better neurocognitive functional outcomes.

Table 1 Summary of fibrinolytic therapy and neuroendoscopic lavage

	Author	Year	Country	Number of patients	Mean GA (weeks)	Mean BW (g)	IVH grade (II, III, IV)	Fibrinolytic agent	VP shunt requirement (%)	Infection (%)	Hemorrhage (%)	Cognitive disability (%)
Fibrinolytic therapy	Richard et al., ⁸⁵⁾	2001	Turkey	17	29.2	1318	II: 2, III: 58, IV: 4	t-PA: 12, urokinase: 4	23.5%	21.8%	11.8%	NL
	Yapicioglu et al., ⁸⁶⁾	2003	France	6	28.7	1164	III: 2, IV: 4	streptokinase	50.0%	0.0%	0.0%	NL
	Whitelaw et al., ⁷⁰⁾	2003	United Kingdom	24	28	1150	III: 8, IV: 16	t-PA	26.1%	8.3%	8.3%	21.0%
	Whitelaw et al., ⁷¹⁾	2007	United Kingdom	34	27	1066	NL	t-PA	38.2%	0.0%	35.3%	NL
	Whitelaw et al., ⁷²⁾	2010	United Kingdom	39	27	1050	III: 19, IV: 20	t-PA	41.0%	NL	NL	31.0%
	Park et al., ⁷⁶⁾	2021	Japan	21	27	899	IV: 21	urokinase	14.3%	0.0%	0.0%	20.0%
Neuroendoscopic lavage	Schulz et al., ⁷⁷⁾	2014	Germany	19	27	1036	II: 2, III: 13, IV: 3	-	54.5%	10.5%	0.0%	NL
	d'Arcangues et al., ⁷⁹⁾	2018	Germany	56	27	1523	II: 5, III: 23, IV: 28	-	56.6%	3.6%	8.9%	NL
	Etus et al., ⁸²⁾	2018	Turkey	23	NL	NL	III and IV	-	60.8%	4.3%	0.0%	NL
	Tirado-Caballero et al., ⁸⁰⁾	2020	Spain	46	30	1672	III: 28, IV: 18	-	58.7%	21.7%	6.5%	46.7%
	Behrens et al., ⁷⁸⁾	2020	Germany	42	27	1169	II: 4, III: 17, IV: 21	-	61.9%	14.3%	NA	44.0%
	Honeyman et al., ⁸¹⁾	2022	United Kingdom	26	29.6	1409	II: 1, III: 8, IV: 17	-	65.4%	7.7%	3.8%	46.7%

GA: gestational age, BW: birthweight, IVH: intraventricular hemorrhage, NL: not listed

AED treatment, the presence of comorbidities, and cerebellar pathology were identified as relevant risk factors.

To date, six clinical articles on NEL have been reported,⁷⁷⁻⁸²⁾ with an average birth weight of 1361 g (1036-1672) for infants, IVH grade II at 21.4%, III at 39.7%, and IV at 38.8%. The average requirement for permanent VP shunts was 59.6% (55.0-65.4), with almost constant results in each report. As adverse events, infection occurred in 10.4% and secondary hemorrhage occurred in 3.8%. Presently, the TROPHY registry has been established to collect international multicenter prospective data on the surgical management of neonatal PIVHH. The results of its large data clinical studies are expected.⁸³⁾

4. Best treatment strategy for PIVHH in preterm infants

As mentioned above, fibrinolytic therapy and NEL are two promising treatments for PIVHH that primarily affects extremely premature infants.⁸⁴⁾ Since 2000, six clinical trials for fibrinolytic therapy^{70-72,76,85,86)} and six clinical trials for NEL⁷⁷⁻⁸²⁾ have been published, and the results of each are

shown in Table 1. Although it can be said that the treatment results are comparable with each other according to the meta-analysis of the clinical evidence about the role of blood product removal in the IVH of prematurity by Kandula in 2022,⁸⁷⁾ NEL seems to have technical restrictions on the timing of treatment indication since the target cases are extremely premature newborn neonates.

Considering current medical technology, the best treatment strategy for severe type of PIVHH (mainly IVH grade 4) in premature infants might be considered as follows (Fig. 6).⁶¹⁾

The first-line treatment method is EVD management combined with fibrinolytic therapy. Since adverse events of secondary bleeding occurred at a high rate in the DRIFT trial, the use of tPA was considered dangerous, and UK should be applied as a fibrinolytic therapy drug. The accurate placement of a small-diameter catheter in the ventricle is not difficult under ultrasound guidance. If the lateral diameter of the anterior horn of the lateral ventricle is at least as large as 5 mm, the EVD catheter placement procedure can be performed without any complications; even if

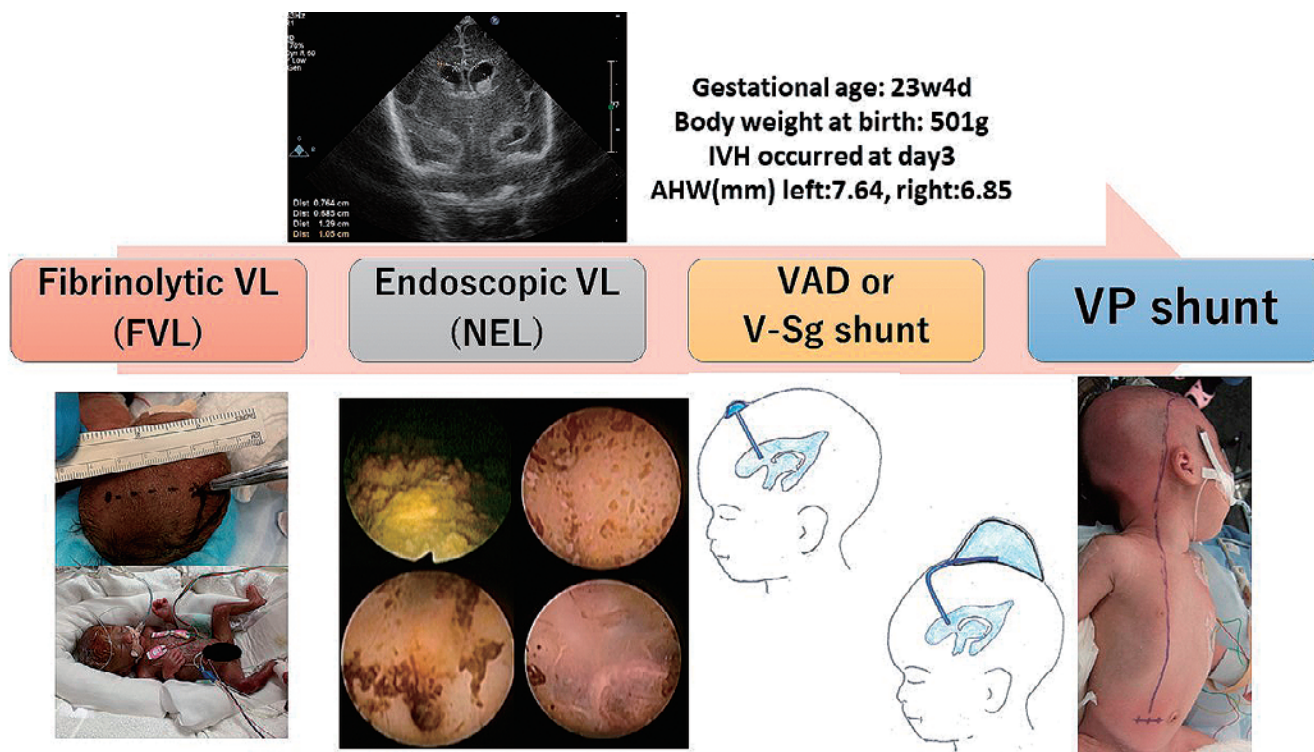


Fig. 6 The best treatment strategy for PIVHH in preterm infants.

AHW: anterior horn width, VL: ventricular lavage, FVL: fibrinolytic ventricular lavage, NEL: neuroendoscopic ventricular lavage, VAD: ventricular access device, V-Sg shunt; ventriculosubgaleal shunt, VP shunt: ventriculoperitoneal shunt

the newborn weighs less than 500 g, it can be attempted. In fact, based on our series,⁷⁶⁾ in all recent cases, the catheter could be reliably placed in the anterior horn with a single puncture operation.

As the second-line treatment method, NEL, which has been actively introduced in these years,⁷⁷⁻⁸³⁾ can be considered. There is no doubt that flushing the hematoma and its degradation products under direct vision is quite ideal, but it is highly invasive and dangerous when applied to extremely small infants. Therefore, NEL should be adapted to when the infant's weight has grown to 1500 g. The outer diameters of endoscopes with multi-side channels required for NEL procedures are 6.8 mm (LOTA[®], KARL STORZ) and 8.6 mm (MINOP[®], AESCULAP), respectively. A key point to be aware of is that, first and foremost, NEL should be carried out solely by surgeons with advanced surgical skills in neuroendoscopic surgery. Surgical iatrogenic damage is likely to occur in the fragile brain of extremely premature infants, and secondary brain damage must be absolutely avoided since the purpose of an aggressive treatment is to yield good neurodevelopmental outcomes.

The third-line treatment methods are intermittent CSF puncturing after placement of the ventricular reservoir or the VS shunt, which have been performed for several decades. Unfortunately, as historical meta-analyses have demonstrated, these methods ultimately require permanent VP

shunt placement in the majority of cases.⁶⁵⁻⁶⁷⁾

In milder cases (IVH grades 2 and 3), treatment with intermittent CSF excretion by placing a ventricular access device might be safe and appropriate if the hematoma is spontaneously dissolved early.

When progressive PIVHH cannot be controlled by the above treatment methods, a VP shunt is performed as the final recourse. Nevertheless, at the same time, we must accept the possibility of various shunt-related complications that may occur during the entire life of the preterm infants.^{88,89)} Furthermore, if shunt-related problems occur, additional treatment should be given promptly and appropriately. Additionally, it should be recognized that in most cases, good neurodevelopmental outcomes cannot be expected.⁸⁹⁾ The incidence of shunt-related complications, including shunt infections, is extremely high in post-IVH hydrocephalus in ELBWIs.^{2-4,8-11,89)}

5. How to reduce periventricular white matter damage and improve neurodevelopmental outcomes?

Mortality rates in preterm infants with high-grade IVH have been improving, but neurodevelopmental outcomes remain poor and have hardly improved.⁹⁰⁾ Permanent neurological deficits result from periventricular white matter damage. Indeed, the pathophysiology of white matter damage is complicated. Numerous unfavorable factors are correlated with white matter damage.^{61,64)} The most obvious

pathology is ischemic change resulting from highly dilated ventricles. The progressive accumulation of CSF changes the shape of the lateral ventricles from a slit to a balloon. Ultimately, the brain mantle becomes as thin as paper. The expanding ventricles distort the developing brain, and intracranial pressure eventually starts to rise. The developing brain may be impaired not only by morphological damage but also by ischemic damage due to reduced cerebral perfusion pressure.

Moreover, the damaging factors of the hematoma and its lysates remain important. Free iron is a potential source of free radicals, and the presence of free iron inside the immature brain for months may be another important mechanism underlying progressive white matter injury.⁹¹⁾ Additionally, proinflammatory cytokines have been implicated in white matter injury and subsequent cerebral palsy.⁹²⁾ Therefore, IVH and PIVHH cause progressive periventricular white matter injury over the course of several months as a consequence of pressure, distortion, free radical injury, and inflammation.^{61,64,73)}

In principle, the VP shunt must be delayed until the weight of the newborn increases to 1800-2000 g; during that period, PIVHH gradually and firmly leads to periventricular white matter damage.

VP shunt surgery and its management in fragile preterm infants frequently yield challenging complications. Undoubtedly, a shunt infection causes catastrophic brain damage. Additionally, shunt-related complications are not uncommon, and the isolated fourth ventricle is recognized as a unique and difficult to treat complication.

As a result of analyzing how to improve the neurodevelopmental outcome, key points can be summarized in the following five therapeutic concepts:^{61,64,73,76)} 1) continuous intracranial pressure control from early PIVHH stages; 2) recovery of brain mantle volume as soon as possible; in other words, morphologically restore the brain; 3) prompt hematoma dissolution and washout; 4) inflammatory cytokines and free radical reduction; and 5) prevention of permanent VP shunt placement. These treatment approaches will contribute to minimizing white matter damage around the ventricles.

To date, the main purpose of treatment for IVH and subsequent PIVHH has been to reduce mortality because the patient is a fragile premature infant and thereafter perform VP shunt surgery. The next core concern has been to avoid the need for a permanent VP shunt placement. Neurosurgeons should actively work on reducing the risk of periventricular white matter damage and improve neurodevelopmental outcomes.^{61,64,72,73,76)}

Conclusion

In the treatment of pediatric hydrocephalus, VP shunts have played an important role as a standard treatment for several decades. It is evident that many children have been

saved and have undergone healthy brain development and growth trajectories due to VP shunt placement. Nevertheless, the incidence of shunt-related complications is not negligible, and it is hoped that treatment modalities to avoid shunt placement and achieve good neurodevelopmental outcomes will be developed.

ETV for noncommunicating hydrocephalus has already been established, but there remain issues that must be resolved. Although the development of treatment for PIVHH in premature infants is still underway, recent reports suggest that fibrinolytic therapy and NEL might be alternative promising treatment concepts.

Acknowledgments

I would like to express my sincere gratitude to Andrew Whitelaw (Professor Emeritus, Bristol University) for his valuable advice and show deep respect for his many years of outstanding achievement.

Conflicts of Interest Disclosure

The author has no conflicts of interest to declare.

References

- 1) Drake JM, Kestle JR, Tuli S: CSF shunts 50 years on--past, present and future. *Childs Nerv Syst* 16: 800-804, 2000
- 2) Sainte-Rose C, Piatt JH, Renier D, et al.: Mechanical complications in shunts. *Pediatr Neurosurg* 17: 2-9, 1991-1992
- 3) Di Rocco C, Massimi L, Tamburrini G: Shunts vs endoscopic third ventriculostomy in infants: are there different types and/or rates of complications? A review. *Childs Nerv Syst* 22: 1573-1589, 2006
- 4) Hanak BW, Bonow RH, Harris CA, Browd SR: Cerebrospinal fluid shunting complications in children. *Pediatr Neurosurg* 52: 381-400, 2017
- 5) Limbrick DD Jr, Baird LC, Klimo P Jr, Riva-Cambrin J, Flannery AM: Pediatric Hydrocephalus Systematic Review and Evidence-Based Guidelines Task Force: Pediatric hydrocephalus: systematic literature review and evidence-based guidelines. Part 4: Cerebrospinal fluid shunt or endoscopic third ventriculostomy for the treatment of hydrocephalus in children. *J Neurosurg Pediatr* 14: 30-34, 2014
- 6) Kulkarni AV, Drake JM, Kestle JR, et al.: Predicting who will benefit from endoscopic third ventriculostomy compared with shunt insertion in childhood hydrocephalus using the ETV Success Score. *J Neurosurg Pediatr* 6: 310-315, 2010
- 7) Kulkarni AV, Riva-Cambrin J, Rozzelle CJ, et al.: Endoscopic third ventriculostomy and choroid plexus cauterization in infant hydrocephalus: a prospective study by the Hydrocephalus Clinical Research Network. *J Neurosurg Pediatr* 21: 214-223, 2018
- 8) Acakpo-Satchivi L, Shannon CN, Tubbs RS, et al.: Death in shunted hydrocephalic children: a follow-up study. *Childs Nerv Syst* 24: 197-201, 2008
- 9) Tuli S, Drake J, Lawless J, Wigg M, Lamberti-Pasculli M: Risk factors for repeated cerebrospinal shunt failures in pediatric patients with hydrocephalus. *J Neurosurg* 92: 31-38, 2000

- 10) Tuli S, Tuli J, Drake J, Spears J: Predictors of death in pediatric patients requiring cerebrospinal fluid shunts. *J Neurosurg* 100: 442-446, 2004
- 11) Riva-Cambrin J, Kestle JR, Holubkov R, et al.: Risk factors for shunt malfunction in pediatric hydrocephalus: a multicenter prospective cohort study. *J Neurosurg Pediatr* 17: 382-390, 2016
- 12) Razmara A, Jackson EM: Clinical indicators of pediatric shunt malfunction: a population-based study from the nationwide emergency department sample. *Pediatr Emerg Care* 37: e764-e766, 2021
- 13) Hari-Raj A, Malthaner LQ, Shi J, Leonard JR, Leonard JC: United States emergency department visits for children with cerebrospinal fluid shunts. *J Neurosurg Pediatr* 27: 23-29, 2020
- 14) Gmeiner M, Wagner H, Zacherl C, et al.: Long-term mortality rates in pediatric hydrocephalus-a retrospective single-center study. *Childs Nerv Syst* 33: 101-109, 2017
- 15) Tamber MS, Klimo P Jr, Mazzola CA, Flannery AM; Pediatric Hydrocephalus Systematic Review and Evidence-Based Guidelines Task Force: Pediatric hydrocephalus: systematic literature review and evidence-based guidelines. Part 8: Management of cerebrospinal fluid shunt infection. *J Neurosurg Pediatr* 14: 60-71, 2014
- 16) Bryant MJ, McEniery J, Walker DG, et al.: Preliminary study of shunt related death in paediatric patients. *J Clin Neurosci* 11: 614-615, 2004
- 17) Liakos AM, Bradley NK, Magram G, Muszynski C: Hydrocephalus and the reproductive health of women: the medical implications of maternal shunt dependency in 70 women and 138 pregnancies. *Neurol Res* 22: 69-88, 2000
- 18) Cusimano MD, Meffe FM, Gentili F, Sermer M: Ventriculoperitoneal shunt malfunction during pregnancy. *Neurosurgery* 27: 969-971, 1990
- 19) Cusimano MD, Meffe FM, Gentili F, Sermer M: Management of pregnant women with cerebrospinal fluid shunts. *Pediatr Neurosurg* 17: 10-13, 1991-1992
- 20) Kleinman G, Sutherland W, Martinez M, Tabsh K: Malfunction of ventriculoperitoneal shunts during pregnancy. *Obstet Gynecol* 61: 753-754, 1983
- 21) Tomei KL: The evolution of cerebrospinal fluid shunts: advances in technology and technique. *Pediatr Neurosurg* 52: 369-380, 2017
- 22) Grant JA: Victor Darwin Lespinasse: a biographical sketch. *Neurosurgery* 39: 1232-1233, 1996
- 23) Dandy WE: An operative procedure for hydrocephalus. *Bull Johns Hopkins Hosp* 33: 189-190, 1992
- 24) Demerdash A, Rocque BG, Johnston J, et al.: Endoscopic third ventriculostomy: a historical review. *Br J Neurosurg* 31: 28-32, 2017
- 25) Schmitt PJ, Jane JA Jr: A lesson in history: the evolution of endoscopic third ventriculostomy. *Neurosurg Focus* 33: E11, 2012
- 26) Kulkarni AV, Riva-Cambrin J, Browd SR: Use of the ETV success score to explain the variation in reported endoscopic third ventriculostomy success rates among published case series of childhood hydrocephalus. *J Neurosurg Pediatr* 7: 143-146, 2011
- 27) Warf BC: Comparison of endoscopic third ventriculostomy alone and combined with choroid plexus cauterization in infants younger than 1 year of age: a prospective study in 550 African children. *J Neurosurg* 103: 475-481, 2005
- 28) Warf BC, Campbell JW: Combined endoscopic third ventriculostomy and choroid plexus cauterization as primary treatment of hydrocephalus for infants with myelomeningocele: long-term results of a prospective intent-to-treat study in 115 East African infants. *J Neurosurg Pediatr* 2: 310-316, 2008
- 29) Warf B, Ondoma S, Kulkarni A, et al.: Neurocognitive outcome and ventricular volume in children with myelomeningocele treated for hydrocephalus in Uganda. *J Neurosurg Pediatr* 4: 564-570, 2009
- 30) Oi S, Di Rocco C: Proposal of "evolution theory in cerebrospinal fluid dynamics" and minor pathway hydrocephalus in developing immature brain. *Childs Nerv Syst* 22: 662-669, 2006
- 31) Thomale UW: Integrated understanding of hydrocephalus - a practical approach for a complex disease. *Childs Nerv Syst* 37: 3313-3324, 2021
- 32) Greitz D: Radiological assessment of hydrocephalus: new theories and implications for therapy. *Neurosurg Rev* 27: 145-165; discussion 166-167, 2004
- 33) Kulkarni AV, Riva-Cambrin J, Holubkov R, et al.: Endoscopic third ventriculostomy in children: prospective, multicenter results from the Hydrocephalus Clinical Research Network. *J Neurosurg Pediatr* 18: 423-429, 2016
- 34) Reikate HL: Hydrocephalus in infants: the unique biomechanics and why they matter. *Childs Nerv Syst* 36: 1713-1728, 2020
- 35) El-Gaidi MA, El-Nasr AH, Eissa EM: Infratentorial complications following preresection CSF diversion in children with posterior fossa tumors. *J Neurosurg Pediatr* 15: 4-11, 2015
- 36) Ruggiero C, Cinalli G, Spennato P, et al.: Endoscopic third ventriculostomy in the treatment of hydrocephalus in posterior fossa tumors in children. *Childs Nerv Syst* 20: 828-833, 2004
- 37) Di Rocco F, Jucá CE, Zerah M, Sainte-Rose C: Endoscopic third ventriculostomy and posterior fossa tumors. *World Neurosurg* 79: S18.e15-S18.e19, 2013
- 38) Fritsch MJ, Doerner L, Kienke S, Mehdorn HM: Hydrocephalus in children with posterior fossa tumors: role of endoscopic third ventriculostomy. *J Neurosurg* 103: 40-42, 2005
- 39) Morelli D, Pirotte B, Lubansu A, et al.: Persistent hydrocephalus after early surgical management of posterior fossa tumors in children: is routine preoperative endoscopic third ventriculostomy justified? *J Neurosurg* 103: 247-252, 2005
- 40) Hader WJ, Drake J, Cochrane D, Sparrow O, Johnson ES, Kestle J: Death after late failure of third ventriculostomy in children. Report of three cases. *J Neurosurg* 97: 211-215, 2002
- 41) Drake J, Chumas P, Kestle J, et al.: Late rapid deterioration after endoscopic third ventriculostomy: additional cases and review of the literature. *J Neurosurg* 105: 118-126, 2006
- 42) Kulkarni AV, Shams I, Cochrane DD, McNeely PD: Does treatment with endoscopic third ventriculostomy result in less concern among parents of children with hydrocephalus? *Childs Nerv Syst* 26: 1529-1534, 2010
- 43) Azab WA, Mijalcic RM, Nakhi SB, Mohammad MH: Ventricular volume and neurocognitive outcome after endoscopic third ventriculostomy: is shunting a better option? A review. *Childs Nerv Syst* 32: 775-780, 2016
- 44) Kulkarni AV, Shams I, Cochrane DD, McNeely PD: Quality of life after endoscopic third ventriculostomy and cerebrospinal fluid shunting: an adjusted multivariable analysis in a large cohort. *J Neurosurg Pediatr* 6: 11-16, 2010
- 45) Kulkarni AV, Drake JM, Kestle JR, et al.: Endoscopic third ventriculostomy vs cerebrospinal fluid shunt in the treatment of hydrocephalus in children: a propensity score-adjusted analysis. *Neurosurgery* 67: 588-593, 2010
- 46) Kulkarni AV, Sgouros S, Leitner Y, Constantini S: International Infant Hydrocephalus Study Investigators: International Infant Hydrocephalus Study (IIHS): 5-year health outcome results of a prospective, multicenter comparison of endoscopic third ventriculostomy (ETV) and shunt for infant hydrocephalus. *Childs Nerv Syst* 34: 2391-2397, 2018

- 47) Kulkarni AV, Riva-Cambrin J, Browd SR, et al.: Endoscopic third ventriculostomy and choroid plexus cauterization in infants with hydrocephalus: a retrospective Hydrocephalus Clinical Research Network study. *J Neurosurg Pediatr* 14: 224-229, 2014
- 48) Riva-Cambrin J, Kestle JRW, Rozzelle CJ, et al.: Predictors of success for combined endoscopic third ventriculostomy and choroid plexus cauterization in a North American setting: a Hydrocephalus Clinical Research Network study. *J Neurosurg Pediatr* 24: 128-138, 2019
- 49) Ellenbogen Y, Brar K, Yang K, Lee Y, Ajani O: Comparison of endoscopic third ventriculostomy with or without choroid plexus cauterization in pediatric hydrocephalus: a systematic review and meta-analysis. *J Neurosurg Pediatr* 26: 371-378, 2020
- 50) Damkier HH, Brown PD, Praetorius J: Cerebrospinal fluid secretion by the choroid plexus. *Physiol Rev* 93: 1847-1892, 2013
- 51) Stopa EG, Berzin TM, Kim S, et al.: Human choroid plexus growth factors: what are the implications for CSF dynamics in Alzheimer's disease? *Exp Neurol* 167: 40-47, 2001
- 52) Nishiyama K, Mori H, Tanaka R: Changes in cerebrospinal fluid hydrodynamics following endoscopic third ventriculostomy for shunt-dependent noncommunicating hydrocephalus. *J Neurosurg* 98: 1027-1031, 2003
- 53) Iannelli A, Rea G, Di Rocco C: CSF shunt removal in children with hydrocephalus. *Acta Neurochir* 147: 503-507, 2005
- 54) Hader WJ, Walker RL, Myles ST, Hamilton M: Complications of endoscopic third ventriculostomy in previously shunted patients. *Neurosurgery* 63: 168-174, 2008
- 55) O'Brien DF, Javadpour M, Collins DR, Spennato P, Mallucci CL: Endoscopic third ventriculostomy: an outcome analysis of primary cases and procedures performed after ventriculoperitoneal shunt malfunction. *J Neurosurg* 103: 393-400, 2005
- 56) Spennato P, Spennato P, Ruggiero C, et al.: Third ventriculostomy in shunt malfunction. *World Neurosurg* 79: S22.e21-S22.e26, 2013
- 57) Kita D, Hayashi Y, Fukui I, Oishi M, Nakada M: Simultaneous ventriculoperitoneal shunt removal and endoscopic third ventriculostomy for three patients previously treated for intracranial germ cell tumors more than 20 years ago. *Childs Nerv Syst* 32: 1543-1547, 2016
- 58) Cinalli G, Spennato P, Ruggiero C, et al.: Intracranial pressure monitoring and lumbar puncture after endoscopic third ventriculostomy in children. *Neurosurgery* 58: 126-136; discussion 126-136, 2006
- 59) Robinson S: Neonatal posthemorrhagic hydrocephalus from prematurity: pathophysiology and current treatment concepts. *J Neurosurg Pediatr* 9: 242-258, 2012
- 60) Shooman D, Portess H, Sparrow O: A review of the current treatment methods for posthaemorrhagic hydrocephalus of infants. *Cerebrospinal Fluid Res* 6: 1, 2009
- 61) Park YS: Intraventricular hemorrhage in the newborn, congenital and developmental cranial anomalies, in Alexiou G, Prodromou N (eds): *Pediatric Neurosurgery for Clinicians*. Springer, 2022, pp 51-65
- 62) Ballabh P: Pathogenesis and prevention of intraventricular hemorrhage. *Clin Perinatol* 41: 47-67, 2014
- 63) McCrea HJ, Ment LR: The diagnosis, management, and postnatal prevention of intraventricular hemorrhage in the preterm neonate. *Clin Perinatol* 35: 777-792, 2008
- 64) Whitelaw A, Aquilina K: Management of posthaemorrhagic ventricular dilatation. *Arch Dis Child Fetal Neonatal Ed* 97: F229-F223, 2012
- 65) Limbrick DD Jr, Mathur A, Johnston JM, et al.: Neurosurgical treatment of progressive posthemorrhagic ventricular dilation in preterm infants: a 10-year single-institution study. *J Neurosurg Pediatr* 6: 224-230, 2010
- 66) Wang JY, Amin AG, Jallo GI, Ahn ES: Ventricular reservoir versus ventriculostomy for posthemorrhagic hydrocephalus in preterm infants: infection risks and ventriculoperitoneal shunt rate. *J Neurosurg Pediatr* 14: 447-454, 2014
- 67) Wellons JC, Shannon CN, Kulkarni AV, et al.: A multicenter retrospective comparison of conversion from temporary to permanent cerebrospinal fluid diversion in very low birth weight infants with posthemorrhagic hydrocephalus. *J Neurosurg Pediatr* 4: 50-55, 2009
- 68) Mazzola CA, Choudhri AF, Auguste KI, et al.: Pediatric hydrocephalus: systematic literature review and evidence-based guidelines. Part 2: Management of posthemorrhagic hydrocephalus in premature infants. *J Neurosurg Pediatr* 14: 8-23, 2014
- 69) Whitelaw A, Rivers RP, Creighton L, Gaffney P: Low dose intraventricular fibrinolytic treatment to prevent posthaemorrhagic hydrocephalus. *Arch Dis Child* 67: 12-14, 1992
- 70) Whitelaw A, Pople I, Cherian S, Evans D, Thoresen M: Phase 1 trial of prevention of hydrocephalus after intraventricular hemorrhage in newborn infants by drainage, irrigation, and fibrinolytic therapy. *Pediatrics* 111: 759-765, 2003
- 71) Whitelaw A, Evans D, Carter M, et al.: Randomized clinical trial of prevention of hydrocephalus after intraventricular hemorrhage in preterm infants: brain-washing versus tapping fluid. *Pediatrics* 119: e1071-e1078, 2007
- 72) Whitelaw A, Jary S, Kmita G, et al.: Randomized trial of drainage, irrigation and fibrinolytic therapy for premature infants with posthemorrhagic ventricular dilatation: developmental outcome at 2 years. *Pediatrics* 125: e852-e858, 2010
- 73) Luyt K, Jary SL, Lea CL, et al.: Drainage, irrigation and fibrinolytic therapy (DRIFT) for posthaemorrhagic ventricular dilatation: 10-year follow-up of a randomised controlled trial. *Arch Dis Child Fetal Neonatal Ed* 105: 466-473, 2020
- 74) Hudgins RJ, Boydston WR, Hudgins PA, Morris R, Adler SM, Gilreath CL: Intrathecal urokinase as a treatment for intraventricular hemorrhage in the preterm infant. *Pediatr Neurosurg* 26: 281-287, 1997
- 75) Hansen AR, Volpe JJ, Goumnerova LC, Madsen JR: Intraventricular urokinase for the treatment of posthemorrhagic hydrocephalus. *Pediatr Neurol* 17: 213-217, 1997
- 76) Park YS, Kotani Y, Kim TK, et al.: Efficacy and safety of intraventricular fibrinolytic therapy for post-intraventricular hemorrhagic hydrocephalus in extreme low birth weight infants: a preliminary clinical study. *Childs Nerv Syst* 37: 69-79, 2021
- 77) Schulz M, Bühner C, Pohl-Schickinger A, Haberl H, Thomale UW: Neuroendoscopic lavage for the treatment of intraventricular hemorrhage and hydrocephalus in neonates. *J Neurosurg Pediatr* 13: 626-635, 2014
- 78) Behrens P, Tietze A, Walch E, et al.: Neurodevelopmental outcome at 2 years after neuroendoscopic lavage in neonates with posthemorrhagic hydrocephalus. *J Neurosurg Pediatr* 26: 495-503, 2020
- 79) d'Arcangues C, Schulz M, Bühner C, Thome U, Krause M, Thomale UW: Extended experience with neuroendoscopic lavage for posthemorrhagic hydrocephalus in neonates. *World Neurosurg* 116: e217-e224, 2018
- 80) Tirado-Caballero J, Rivero-Garvia M, Arteaga-Romero F, Herreria-Franco J, Lozano-Gonzalez Á, Marquez-Rivas J: Neuroendoscopic lavage for the management of posthemorrhagic hydrocephalus in preterm infants: safety, effectivity, and lessons learned. *J Neuro-*

- surg Pediatr* 26: 237-246, 2020
- 81) Honeyman SI, Boukas A, Jayamohan J, Magdum S: Neuroendoscopic lavage for the management of neonatal post-haemorrhagic hydrocephalus: a retrospective series. *Childs Nerv Syst* 38: 115-121, 2022
 - 82) Etus V, Kahilogullari G, Karabagli H, Unlu A: Early endoscopic ventricular irrigation for the treatment of neonatal posthemorrhagic hydrocephalus: a feasible treatment option or not? A multicenter study. *Turk Neurosurg* 28: 137-141, 2018
 - 83) Thomale UW, Cinalli G, Kulkarni AV, et al.: TROPHY registry study design: a prospective, international multicenter study for the surgical treatment of posthemorrhagic hydrocephalus in neonates. *Childs Nerv Syst* 35: 613-619, 2019
 - 84) Chari A, Mallucci C, Whitelaw A, Aquilina K: Intraventricular haemorrhage and posthaemorrhagic ventricular dilatation: moving beyond CSF diversion. *Childs Nerv Syst* 37: 3375-3383, 2021
 - 85) Richard E, Cinalli G, Assis D, Pierre-Kahn A, Lacaze-Masmonteil T: Treatment of post-haemorrhage ventricular dilatation with an Ommaya's reservoir: management and outcome of 64 preterm infants. *Childs Nerv Syst* 17: 334-340, 2001
 - 86) Yapicioglu H, Narli N, Satar M, Soyupak S, Altunbasak S: Intraventricular streptokinase for the treatment of posthaemorrhagic hydrocephalus of preterm. *J Clin Neurosci* 10: 297-299, 2003
 - 87) Kandula V, Mohammad LM, Thirunavu V, et al.: The role of blood product removal in intraventricular hemorrhage of prematurity: a meta-analysis of the clinical evidence. *Childs Nerv Syst* 38: 239-252, 2022
 - 88) Rocque BG, Waldrop RP, Shamblin I, et al.: Shunt failure clusters: an analysis of multiple, frequent shunt failures. *J Neurosurg Pediatr* 27: 287-293, 2020
 - 89) Mohamed M, Mediratta S, Chari A, et al.: Post-haemorrhagic hydrocephalus is associated with poorer surgical and neurodevelopmental sequelae than other causes of infant hydrocephalus. *Childs Nerv Syst* 37: 3385-3396, 2021
 - 90) McCluggage SG, Laskay NMB, Donahue BN, et al.: Functional outcomes at 2 years of age following treatment for posthemorrhagic hydrocephalus of prematurity: what do we know at the time of consult? *J Neurosurg Pediatr* 25: 453-461, 2020
 - 91) Savman K, Nilsson UA, Blennow M, Kjellmer I, Whitelaw A: Non-protein-bound iron is elevated in cerebrospinal fluid from preterm infants with posthemorrhagic ventricular dilatation. *Pediatr Res* 49: 208-212, 2001
 - 92) Szepecht D, Wiak K, Braszak A, Szymankiewicz M, Gadzinowski J: Role of selected cytokines in the etiopathogenesis of intraventricular hemorrhage in preterm newborns. *Childs Nerv Syst* 32: 2097-2103, 2016

Corresponding author: Young-Soo Park, MD, PhD

Department of Neurosurgery and Children's Medical Center, Nara Medical University, 840 Shijo-cho, Kashihara city, Nara 634-8522, Japan.

e-mail: park-y-s@naramed-u.ac.jp