

# Different MRI patterns in MS worsening after stopping fingolimod

Caterina Lapucci, MD, Damiano Baroncini, MD, Maria Cellerino, MD, Giacomo Boffa, MD, Ilaria Callegari, MD, Matteo Pardini, MD, PhD, Giovanni Novi, MD, Maria Pia Sormani, PhD, Giovanni Luigi Mancardi, MD, Angelo Ghezzi, MD, Mauro Zaffaroni, MD, Antonio Uccelli, MD, Matilde Inglese, MD, PhD, and Luca Roccatagliata, MD, PhD

**Correspondence**  
Dr. Lapucci  
lapuccicate@gmail.com

*Neurol Neuroimmunol Neuroinflamm* 2019;6:e566. doi:10.1212/NXI.0000000000000566

## Abstract

### Objective

To analyze MRI images in patients with MS who experienced worsening of neurologic status (WNS) after stopping fingolimod (FTY).

### Methods

In this retrospective study, demographic, clinical, and radiologic data of patients with MS who experienced WNS after stopping FTY were retrospectively collected. We introduced the “ $\delta$ Expanded Disability Status Scale (EDSS)-ratio” to identify patients who, after FTY withdrawal, showed an inflammatory flare-up exceeding the highest lifetime disease activity level. Patients with  $\delta$ EDSS-ratio  $> 1$  were enrolled in the study.

### Results

Eight patients were identified. The mean (SD) age of the 8 (7 female) patients was 35.3 (4.9) years. The mean FTY treatment duration was 3.1 (0.8) years. The mean FTY discontinuation–WNS interval was 4 (0.9) months. The 4 patients with  $\delta$ EDSS-ratio  $\geq 2$  developed severe monophasic WNS (EDSS score above 8.5), characterized by clinical features and MRI findings not typical of MS, which we classified as “tumefactive demyelination pattern” (TDL) and “Punctuated pattern” (PL). Conversely, patients whose  $\delta$ EDSS-ratio was between 1 and 2 had clinical features and brain MRI compatible with a more typical, even if aggressive, MS relapse. In patients with TDL and PL, the flare-up of inflammatory activity led to severe tissue damage resulting in T2 but also T1 lesion volume increase at 6-month follow-up.

### Conclusions

Peculiar MRI features (TDL and PL), different from a typical MS flare-up, might occur in some patients who experienced WNS after stopping FTY. Further studies, also involving immunologic biomarkers, are necessary to investigate TDL or PL pathophysiology.

M. Inglese and L. Roccatagliata are co-last authors.

From the Department of Neuroscience, Rehabilitation, Ophthalmology, Genetics (C.L., M.C., G.B., M.P., G.N., G.L.M., A.U., M.I.), Maternal and Child Health (DiNOGMI), University of Genoa; Multiple Sclerosis Centre (D.B., A.G., M.Z.), Gallarate Hospital, ASST of Valle Olona, Gallarate; Department of Neurology (M.C., G.B., M.P., G.L.M., A.U.), Ospedale Policlinico San Martino—Sistema Sanitario Regione Liguria-Istituto di Ricovero e Cura a Carattere Scientifico per l'Oncologia; IRCCS Foundation C. Mondino National Neurological Institute (I.C.), Pavia; Department of Health Sciences (DISSAL) (M.P.S., L.R.), Ospedale Policlinico San Martino IRCCS, Genoa, Italy; Department of Radiology and Neuroscience (M.I.), Icahn School of Medicine at Mount Sinai, New York; and Department of Neuroradiology (L.R.), Ospedale Policlinico San Martino IRCCS, Genoa, Italy.

Funding information and disclosures are provided at the end of the article. Full disclosure form information provided by the authors is available with the full text of this article at [Neurology.org/NN](http://Neurology.org/NN).

The Article Processing Charge was funded by the authors.

This is an open access article distributed under the terms of the Creative Commons Attribution-NonCommercial-NoDerivatives License 4.0 (CC BY-NC-ND), which permits downloading and sharing the work provided it is properly cited. The work cannot be changed in any way or used commercially without permission from the journal.

## Glossary

**CL** = classic MS pattern; **EDSS** = expanded disability status scale; **FTY** = fingolimod; **FU** = follow-up; **LV** = lesion volume; **PL** = punctuated pattern; **TDL** = tumefactive demyelination pattern; **WNS** = worsening of neurologic status.

Fingolimod (FTY) is an oral sphingosine-1-phosphate receptor (S1P1) modulator approved for MS. In the past few years, worsening of neurologic status (WNS) has been described in a small series of patients after FTY discontinuation.<sup>1</sup> This phenomenon remains controversial and regarded as MS “reactivation”<sup>2</sup> or considered a distinct “rebound” phenomenon.<sup>3</sup> Nevertheless, WNS after stopping FTY can lead to severe disability or can even be life-threatening, and thus the Food and Drug Administration recently issued a warning on this topic.<sup>4</sup> We report a retrospective series of 8 patients who developed WNS after FTY withdrawal focusing on the different MRI patterns in the acute phase. The aim of the study was to analyze MRI images in patients with MS who experienced WNS after stopping FTY.

## Methods

### Standard protocol approvals, registrations, and patient consent

A written informed consent was obtained from all patients.

### Patients

From the systematic revision of clinical records of patients, we collected clinical-radiological data of patients with MS who developed WNS after FTY withdrawal between November 2013 and November 2017.

### Clinical data analysis

We defined WNS by calculating the “post-FTY withdrawal  $\delta$ Expanded Disability Status Scale (EDSS)/pre-FTY withdrawal  $\delta$ EDSS ratio” (from now on called “ $\delta$ EDSS-ratio”), where

1. post-FTY-withdrawal  $\delta$ EDSS is the highest EDSS score change ( $\delta$ ) occurred after FTY withdrawal
2. pre-FTY-withdrawal  $\delta$ EDSS is the highest EDSS score change ( $\delta$ ) occurred during the whole previous MS course (i.e., worst lifetime relapse).

Patients with  $\delta$ EDSS-ratio  $> 1$  were enrolled in the study.

WNS after FTY discontinuation was distinguished as monophasic (one or more relapses, but with less than 1 month between relapses), biphasic (2 relapses occurring at least 1 month apart), and multiphasic ( $\geq 3$  relapses).

### MRI acquisition and analysis

T2/FLAIR, TSE-T1 (before and after Gadolinium [Gd] administration), and DWI, performed before FTY withdrawal, during the WNS, and at 6-month follow-up (FU), were analyzed to obtain T2 and T1 lesion volume (LV), number and

pattern of Gd-enhancing lesions and volume of tissue with restricted diffusion.

Data are reported as mean  $\pm$  SD.

### Data availability

Raw data are available upon appropriate request.

## Results

We identified 8 patients. Seven patients were women. The mean age was  $35.3 \pm 4.9$  years. The mean duration of FTY treatment was  $3.1 \pm 0.8$  years. The most common cause of FTY discontinuation was the attempt to become pregnant (6 out of 7 female patients). The mean FTY discontinuation–WNS interval was  $4 \pm 0.9$  months.

We stratified patients according to the  $\delta$ EDSS ratio:

1.  $\delta$ EDSS-ratio  $\geq 2$  (Pt.1–Pt.4)
2.  $>1\delta$ EDSS-ratio  $< 2$  (Pt.5–Pt.8).

### Clinical features

The 4 patients with a  $\delta$ EDSS-ratio  $\geq 2$ , developed a monophasic WNS and reached EDSS scores of up to 9, 8.5 and 9.5 (Pt.1, Pt.3, and Pt.4); one patient (Pt.2) died. Pt.1, Pt.2, and Pt.4 developed tetraplegia and multiple cranial nerve involvement with decrease in consciousness rapidly resulting in coma. Pt.3 presented a marked cognitive impairment associated with motor disability.

The 4 patients with  $\delta$ EDSS-ratio between 1 and 2, showed multiphasic (Pt.5), biphasic (Pt.6 and Pt.7), and monophasic (Pt.8) courses, characterized by multifocal neurologic deficits, without altered state of consciousness.

At 2-year FU, for patients with  $\delta$ EDSS-ratio  $\geq 2$ , disability worsened when compared to patients with  $>1\delta$ EDSS-ratio  $< 2$  (increase in mean EDSS points:  $3 \pm 2.9$  vs  $1.1 \pm 1.2$ ) (figure 1).

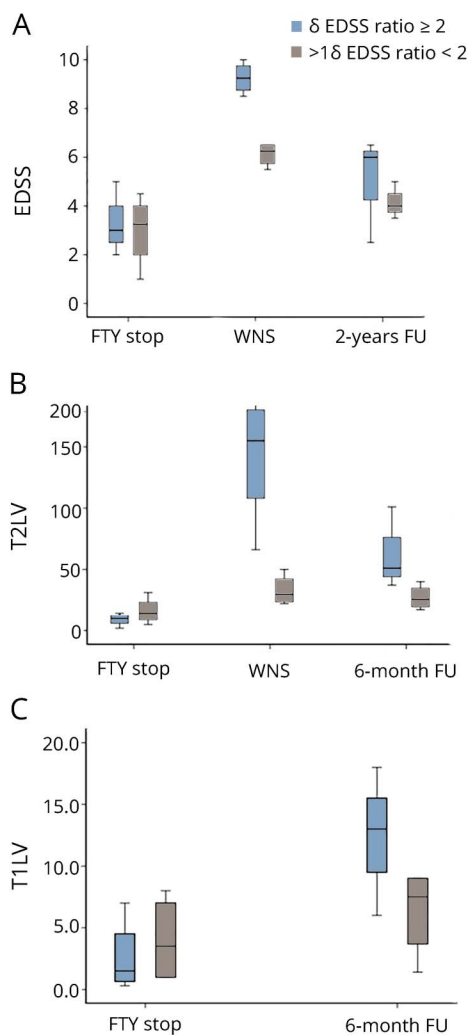
Demographic and clinical features and treatment performed are detailed in the table.

### MRI features

The 4 patients with a  $\delta$ EDSS-ratio  $\geq 2$  showed MRI features that we defined as “*tumefactive demyelination pattern*” (TDL) (Pt.2–Pt.4) and “*punctuated pattern*” (PL) (Pt.3) (figure 2, figure e-1, [links.lww.com/NXI/A109](https://links.lww.com/NXI/A109)).

TDL was characterized by large T2/FLAIR hyperintense lesions surrounded by marked edema, mass effect on adjacent

**Figure 1** EDSS score (A), T2LV (B) and T1LV (C) courses in patients who experienced WNS after FTY withdrawal



(A) EDSS scores were reported at FTY stop, WNS and 2-year follow-up. Patients with  $\delta$ EDSS-ratio  $\geq 2$  reached very high EDSS scores at WNS and accumulated more disability at 2-year follow-up when compared to patients with  $>1$   $\delta$ EDSS-ratio  $>2$ . (B) T2LV was calculated at FTY stop, WNS and 6-month FU. At the 6-month follow-up, all patients and particularly those with  $\delta$ EDSS-ratio  $\geq 2$ , had a T2LV increase compared to the pre-FTY suspension MRI, although decreased with respect to the MRI scan at WNS, likely due to the resolution of a portion of T2 hyperintensity, probably reflecting oedema. (C) T1LV was calculated at FTY stop and 6-month FU to consider chronic black holes. At 6-month follow-up all patients, and particularly those with  $\delta$ EDSS-ratio  $\geq 2$ , showed a T1LV increase with respect to the MRI scan at WNS. EDSS = expanded disability status scale; FTY = fingolimod; FU = follow-up; T1LV = T1 lesion volume; T2LV = T2 lesion volume; WNS = worsening of neurologic status;  $\delta$ EDSS-ratio = post-FTY withdrawal  $\delta$ EDSS/pre-FTY withdrawal  $\delta$ EDSS ratio.

structures, and multiple enhancing lesions with an open ring (40%), nodular (30%), or closed ring (30%) enhancement. A large proportion of lesions had areas of restricted diffusion (up to 30%) (figure 2). PL presented innumerable small T2/FLAIR hyperintense lesions, mostly associated with contrast enhancement and restricted diffusion (15%) (figure 2).

The 4 patients with the  $\delta$ EDSS-ratio between 1 and 2 showed MRI features that we defined as “classic MS pattern” (figure 2, figure e-1, [links.ww.com/NXI/A109](https://www.ww.com/NXI/A109)). Brain MRIs showed

T2/FLAIR lesions with no edema nor mass effect, some with nodular/ring enhancement and only a small volume of tissue with restricted diffusion.

At the 6-month FU, all patients exhibited a T2LV increase compared to the pre-FTY suspension MRI, although it decreased according to the MRI scan at WNS, likely due to the partial resolution of T2 hyperintensity. This finding was more evident for patients with a  $\delta$ EDSS-ratio  $\geq 2$ , particularly with TDL.

T1LV increased in all patients at the 6-month FU. Patients who showed a higher volume of tissue characterized by restricted diffusion at WNS had a higher T1LV % increase at 6-month FU (figure 1).

MRI data are detailed in the table.

## Discussion

Severe WNS occurring in patients with MS after FTY withdrawal is a rare and not completely understood phenomenon. Although a recent post-hoc analysis of FREEDOMS-FREEDOMS II trials found no difference in the development of the so-called rebound between patients discontinuing FTY and the placebo group,<sup>5</sup> a small series reported increases in clinical and radiologic disease activity after FTY cessation in 10.9%–25.8% of patients.<sup>1,6</sup> Furthermore, a recent study confirmed that the “rebound” phenomenon after FTY suspension does exist, with a risk estimated at 5%<sup>7</sup> and recently FDA issued a warning about severe MS worsening after stopping FTY.<sup>4</sup> Cast aside the controversy regarding the frequency, it is relevant to consider that the “rebound” phenomenon leads to permanent severe disability, may be life-threatening or even fatal, as occurred to one patient of our cohort.

We retrospectively identified 8 patients who experienced, after FTY withdrawal, a WNS exceeding the highest lifetime level of MS activity, calculating the  $\delta$ EDSS-ratio to stratify WNS severity. All patients were clinically stable during FTY treatment, with 6 patients well enough to decide to plan pregnancy.

Patients with  $\delta$ EDSS-ratio  $\geq 2$  developed severe monophasic WNS (EDSS score above 8.5), characterized by clinical features (i.e., tetraplegia resulting in coma) and MRI findings not typical of MS. Large T2/FLAIR lesions with edema, ring/nodular enhancement, and restricted diffusion characterized TDL, while PL showed innumerable millimetric enhancing lesions and a high rate of tissue with restricted diffusion. Conversely, patients with  $>1$   $\delta$ EDSS-ratio  $< 2$  had clinical features and brain MRI compatible with a more typical, even if aggressive, MS relapse.

In patients with TDL and PL, the flare-up of inflammatory activity led to severe tissue damage resulting in T2 but also T1LV increase at 6 months; moreover, they demonstrated larger areas of tissue with restricted diffusion, which may

**Table** Clinical and MRI features of patients with MS who experienced WNS after FTY withdrawal

	Pt.1	Pt.2	Pt.3	Pt.4	Pt.5	Pt.6	Pt.7	Pt.8
<b>Demographics</b>								
<b>Sex</b>	F	F	F	F	F	F	F	M
<b>Age</b>	40	26	35	33	30	33	39	46
<b>Clinical data</b>								
<b>MS type at withdrawal</b>	SPMS	RRMS	RRMS	RRMS	RRMS	RRMS	RRMS	SPMS
<b>MS duration at FTY stop (y)</b>	19	9	13	19	9	18	13	12
<b>FTY duration (y)</b>	4	2	4	3	3	3	3	4
<b>Relapses and/or MRI activity during FTY</b>	No	No	No	Yes	No	No	No	No
<b>Cause of FTY withdrawal</b>	Progressive course	Pregnancy attempt	Pregnancy attempt	Pregnancy attempt	Pregnancy attempt	Pregnancy attempt	Pregnancy attempt	Progressive course
<b>FTY stop-WNS (m)</b>	3	4	4	3	3	5	5	5
<b>Pregnancy outcome</b>	NA	Therapeutic abortion to treat WNS	Miscarriage 1 wk before WNS	Therapeutic abortion 1 wk before WNS	Unsuccessful pregnancy attempt	Unsuccessful pregnancy attempt	Unsuccessful pregnancy attempt	NA
<b>Gestational age at therapeutic abortion/miscarriage (wk)</b>	NA	30	8	7	NA	NA	NA	NA
<b>Clinical features at WNS</b>	Tetraplegia cranial n. deficits (locked-in), coma	Tetraplegia cranial n. deficits (locked-in), coma	Severe cognitive and motor impairment	Tetraplegia cranial n. deficits (locked-in) coma	Left hypoesthesia (I), paraparesis (II), monoparesis (III) <sup>a</sup>	Cerebellar (I), sensori-motor syndrome (II) <sup>a</sup>	Motor (I), cognitive impairment (II) <sup>a</sup>	Right sensori-motor syndrome
<b>Spine involvement</b>	Yes	No	Yes	Yes	Yes	No	No	No
<b>EDSS at WNS</b>	9	10	8.5	9.5	6.5	6.5	5.5	6
<b>ΔEDSS ratio</b>	2	3.5	3.2	2.1	1.8	1.2	1.2	1.5
<b>WNS course</b>	Monophasic	Monophasic	Monophasic	Monophasic	Multiphasic	Biphasic	Biphasic	Monophasic
<b>WNS therapy</b>	CTS, PEX, AHSCT	CTS, CYC	CTS, PEX, RTX	CTS, PEX, RTX	CTS, ALEM	CTS, AHSCT	CTS, RTX	CTS, NAT
<b>FTY stop-2 y FU EDSS increase</b>	1	7	0.5	3.5	3	0.5	0.5	0.5
<b>MRI data</b>								
<b>Pattern</b>	PL	TDL	TDL	TDL	CL	CL	CL	CL

Continued

**Table** Clinical and MRI features of patients with MS who experienced WNS after FTY withdrawal (continued)

	Pt.1	Pt.2	Pt.3	Pt.4	Pt.5	Pt.6	Pt.7	Pt.8
<b>T2 LV<sup>b</sup> (mL)</b>								
<b>FTY stop</b>	14	10	2	10	5	15	31	13
<b>WNS</b>	66	200	160	150	22 <sup>c</sup>	34 <sup>c</sup>	50 <sup>c</sup>	25
<b>6-mo FU</b>	51	NA (exitus)	37	101	22	17	40	29
<b>% Increase WNS-FTY stop</b>	264	1900	7,900	1,400	340 <sup>c</sup>	126 <sup>c</sup>	61 <sup>c</sup>	92
<b>% Increase 6 mo FU-WNS</b>	253	NA (exitus)	1750	910	340 <sup>c</sup>	13 <sup>c</sup>	29 <sup>c</sup>	124
<b>Gd + lesions at WNS (n)</b>	>50	>50	>50	35	3 (I), 3(II), 6(III) <sup>d</sup>	10 (I), 2(II) <sup>d</sup>	8 (I), 20 (II) <sup>d</sup>	6
<b>Hypointense lesions at WNS (ADC) (% of Gd lesions)</b>	Yes (≈15%) <sup>e</sup>	Yes (≈25%) <sup>e</sup>	Yes (≈30%) <sup>e</sup>	Yes (15%)	Yes (8%)	Yes (2%)	Yes (1%)	Yes (1%)
<b>LV restricted diffusion<sup>f</sup> (mL)</b>	2.4	4.2	5.8	2.8	0.6	0.3	0.3	0.1
<b>T1 LV<sup>b</sup> (mL)</b>								
<b>FTY stop</b>	1	7	2	0.3	1	6	8	1
<b>6-months FU</b>	18	NA (exitus)	13	6	6	9	9	1.4
<b>% Increase 6 month FU-FTY stop</b>	1700	NA (exitus)	550	1900	500	50	12	40

Abbreviations: ADC = apparent diffusion coefficient maps; AHSCT = autologous hematopoietic stem cells transplantation; ALEM = alemtuzumab; CL = Classic MS pattern; CTS = corticosteroids; CYC = cyclophosphamide; EDSS = expanded disability status scale; FTY = fingolimod; FU = follow-up; LV = lesion volume; NA = not applicable; NAT = natalizumab; PEX = plasma exchange; PL = punctuated pattern; Pt = patient; RRMS, relapsing-remitting MS; RTX = rituximab; SPMS, secondary progressive MS; T1LV = T1 lesion volume; T2LV = T2 lesion volume; TDL = tumefactive demyelinating pattern; WNS = worsening of neurologic status;  $\delta$ EDSS ratio = post-FTY withdrawal  $\delta$ EDSS/pre-FTY withdrawal  $\delta$ EDSS ratio.

<sup>a</sup> For patients who experienced biphasic and multiphasic WNS, clinical features of each relapse are reported.

<sup>b</sup> Obtained by using a manual segmentation technique on 3-mm-slice thickness (Analyze, version 12.0).

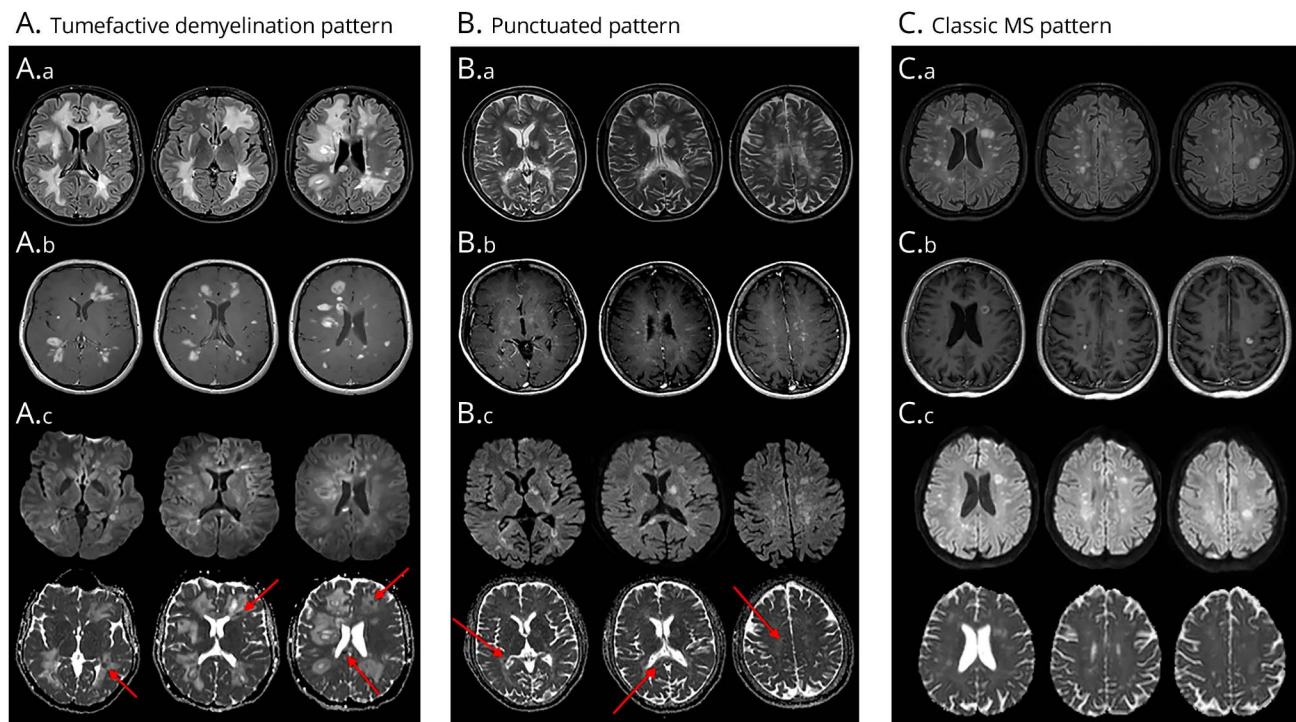
<sup>c</sup> For Pt.5, Pt.6, and Pt.7, who experienced multiphasic and biphasic WNS, the highest T2LV was reported and used for the analysis.

<sup>d</sup> For Pt.5, Pt.6, and Pt.7, who experienced multiphasic and biphasic WNS, Gd enhancing lesions number of each relapse (I, II, III) was reported.

<sup>e</sup> For Pt.1, Pt.2, Pt.3, who had >50 Gd enhancing lesions, a maximum number of 50 Gd enhancing lesions was considered to calculate the rate of hypointense lesions on ADC maps.

<sup>f</sup> Defined by ADC values  $<620 \times 10^{-6} \text{ mm}^2/\text{s}$ .





(A) Tumefactive demyelination pattern (TDL), Pt.3. (A.a) Axial T2/FLAIR images, showing large and edematous lesions, causing mass effect on adjacent structures; (A.b) Axial TSE-T1 after Gd administration images, showing multiple ring and nodular enhancing lesions; (A.c) axial DWI (on the left) and correspondent ADC maps (on the right) images, showing hyperintense lesions on DWI with correspondent hypointense signal on ADC maps (red arrows), expression of restricted diffusion. (B) Punctuated pattern (PL), Pt.1, SPMS patient. (B.a) axial TSE-T2 images, medium in size (already detectable in previous scans) and new small hyperintense lesions, with no edema and mass effect; (B.b) axial TSE-T1 after gadolinium administration images, showing innumerable millimetric enhancing lesions, both in infratentorial and supratentorial areas. (B.c) axial DWI (on the left) and correspondent ADC maps (on the right) images, showing hyperintense lesions on DWI with correspondent hypointense signal on ADC maps (red arrows), expression of restricted diffusion. (C) Classic MS pattern (CL), (Pt.6) (C.a) Axial FLAIR images, showing medium in size lesions, with no edema and mass effect; (B.b) axial TSE-T1 after gadolinium administration images, showing nodular and ring enhancing lesions. (C.c) Axial DWI (on the left) and correspondent ADC maps (on the right) images, showing hyperintense lesions on DWI with correspondent hyperintense signal on ADC maps ("T2-shine through effect").

suggest that cytotoxic edema and/or high inflammatory cells density within acute lesions resulted in more profound brain tissue damage.<sup>8</sup>

The pathophysiology of the "rebound" phenomenon is still unclear. Brain histologic examination of the patient who died (reported in a separate publication) revealed prominent astrocytic gliosis, with large hypertrophic reactive astrocytes showing intense S1P1 expression.<sup>9</sup> The role of astrocytes in modulating the influx of leukocytes into the CNS has been demonstrated in a model of experimental autoimmune encephalitis<sup>10</sup> and warrants further investigation in the context of FTY withdrawal. MRI features similar to the TDL and PL patterns that we described have been reported in patients with evidence of B cell hyper-repopulation after alemtuzumab treatment.<sup>11</sup>

The small size of our cohort represents a limitation of the study. We used the  $\delta$ EDSS-ratio as a method to stratify the patients who worsened after FTY suspension and its role as a predictor of the outcome after WNS is unknown. Interestingly, patients with worse clinical course and outcome were those who showed peculiar MRI features that we defined

TDL and PL, different from a typical MS flare-up. Further studies are necessary to investigate whether specific cellular subsets play a role in patients who develop a severe WNS after FTY cessation.

## Study funding

This study did not receive any funding support.

## Disclosure

C. Lapucci reports no disclosures. D. Baroncini received travel grants from Genzyme, Novartis, and Merck for participation at national and international congresses; he received personal compensation from Almirall for scientific publication and honoraria from Sanofi for participating in an advisory board. M. Cellerino, G. Boffa, and I. Callegari report no disclosures. M. Pardini received research support from Novartis and personal fees from Teva and Merck. G. Novi reports no disclosures. M.P. Sormani received consulting fees from Biogen Idec, Merck Serono, Teva, Genzyme, Roche, Novartis, GeNeuro, and Medday; G.L. Mancardi received honoraria for lecturing, travel expenses for attending meetings, and financial support for research from Bayer Schering, Biogen Idec, Sanofi-Aventis, Merck Serono Pharmaceuticals, Novartis,

Genzyme, and Teva. A. Ghezzi received honoraria for speaking and consultancy by Novartis, Genzyme, Roche, Merck Serono, Teva, and Mylan. M. Zaffaroni received honoraria for consultancy and participation in advisory boards or travel grants from Genzyme, Biogen Idec, Merck Serono, Sanofi-Aventis, Teva, and Novartis. A. Uccelli received grants and contracts from FISM, Novartis, Fondazione Cariplo, Italian Ministry of Health; received honoraria and consultation fees from Biogen, Roche, Teva, Merck, Genzyme, and Novartis. M. Inglese received research grants from NIH, DOD, NMSS, FISM, and Teva Neuroscience. L. Roccatagliata received research grants from FISM. Disclosures available: [Neurology.org/NN](http://Neurology.org/NN).

## Publication history

Received by *Neurology: Neuroimmunology & Neuroinflammation* February 26, 2019. Accepted in final form March 5, 2019.

## Appendix Authors

Name	Location	Role	Contribution
<b>Caterina Lapucci, MD</b>	DINOEMI, University of Genoa	Author (corresponding author)	Designed and conceptualized study; analyzed the data; and drafted the manuscript for intellectual content
<b>D. Baroncini, MD</b>	Multiple Sclerosis Centre, Gallarate Hospital, ASST of Valle Olona, Gallarate, Italy	Author	Acquisition of data; and revised the manuscript for intellectual content
<b>M. Cellerino, MD</b>	DINOEMI, University of Genoa	Author	Acquisition of data; and revised the manuscript for intellectual content
<b>G. Boffa, MD</b>	DINOEMI, University of Genoa	Author	Acquisition of data; and revised the manuscript for intellectual content
<b>I. Callegari, MD</b>	IRCCS Foundation C. Mondino National Neurological Institute, Pavia, Italy	Author	Acquisition of data; and revised the manuscript for intellectual content
<b>M. Pardini, MD, PhD</b>	DINOEMI, University of Genoa	Author	Analyzed the data; and revised the manuscript for intellectual content
<b>G. Novi, MD</b>	DINOEMI, University of Genoa	Author	Acquisition of data; and revised the manuscript for intellectual content

## Appendix (continued)

Name	Location	Role	Contribution
<b>M.P. Sormani, PhD</b>	Ospedale Policlinico	Author	Revised the manuscript for intellectual content
<b>G.L. Mancardi, MD</b>	DINOEMI, University of Genoa	Author	Revised the manuscript for intellectual content
<b>A. Ghezzi, MD</b>	Multiple Sclerosis Centre, Gallarate Hospital, ASST of Valle Olona, Gallarate, Italy	Author	Revised the manuscript for intellectual content
<b>M. Zaffaroni, MD</b>	Multiple Sclerosis Centre, Gallarate Hospital, ASST of Valle Olona, Gallarate, Italy	Author	Revised the manuscript for intellectual content
<b>A. Uccelli, MD</b>	Department of Neurosciences, Rehabilitation, Ophthalmology, Genetics, Maternal and Child Health Unit, Center of Excellence for Biomedical Research, University of Genoa, Genoa, Italy; Ospedale Policlinico San Martino-IRCCS, Genoa, Italy	Author	Revised the manuscript for intellectual content
<b>M. Inglese, MD, PhD</b>	DINOEMI, University of Genoa; Icahn School of Medicine, Mount Sinai, NY	Author	Designed and conceptualized the study; and revised the manuscript for intellectual content
<b>L. Roccatagliata, MD, PhD</b>	Ospedale Policlinico San Martino IRCCS, Genoa	Author	Designed and conceptualized the study; analyzed the data; and revised the manuscript for intellectual content

## References

- Hatcher SE, Waubant E, Nourbakhsh B, et al. Rebound syndrome in patients with multiple sclerosis after cessation of fingolimod treatment. *JAMA* 2016;73:790–794.
- Berger B, Baumgartner A, Rauer S, et al. Severe disease reactivation in four patients with relapsing-remitting multiple sclerosis after fingolimod cessation. *J Neuroimmunol* 2015;282:118–122.
- Havla JB, Pellkofer HL, Meinl I, et al. Rebound of disease activity after withdrawal of fingolimod (FTY720) treatment. *Arch Neurol* 2012;69:262–264.
- FDA. Gilenya (Fingolimod): Drug Safety Communication-Severe Worsening of Multiple Sclerosis After Stopping the Medicine. 2018. Available at: [fda.gov/Safety/MedWatch/SafetyInformation/SafetyAlertsforHumanMedicalProducts/ucm626264.htm](http://fda.gov/Safety/MedWatch/SafetyInformation/SafetyAlertsforHumanMedicalProducts/ucm626264.htm). Accessed November 21, 2018.

5. Vermersch P, Radue EW, Putzki N, et al. A comparison of multiple sclerosis disease activity after discontinuation of fingolimod and placebo. *Mult Scler J Exp Transl Clin* 2017;3:2055217317730096.
6. Uygunoglu U, Tutuncu M, Altintas A, et al. Factors predictive of severe multiple sclerosis disease reactivation after fingolimod cessation. *Neurologist* 2018;23:12–16.
7. Frau J, Sormani MP, Signori A, et al. Clinical activity after fingolimod cessation: disease reactivation or rebound?. *Eur J Neurol* 2018;25:1270–1275.
8. Abdoli M, Chakraborty S, MacLean HJ, et al. The evaluation of MRI diffusion values of active demyelinating lesions in multiple sclerosis. *Mult Scler Relat Disord* 2016;10: 97–102.
9. Giordana MT, Cavalla P, Uccelli A, et al. Overexpression of sphingosine-1-phosphate receptors on reactive astrocytes drives neuropathology of multiple sclerosis rebound after fingolimod discontinuation. *Mult Scler* 2018;24: 1133–1137.
10. Voskuhl RR, Peterson RS, Song B, et al. Reactive astrocytes form scar-like perivascular barriers to leukocytes during adaptive immuneinflammation of the CNS. *J Neurosci* 2009;29:11511–11522.
11. Wehrum T, Beume LA, Stich O, et al. Activation of disease during therapy with alemtuzumab in 3 patients with multiple sclerosis. *Neurology* 2018;90: e601–e605.



# Neurology® Neuroimmunology & Neuroinflammation

## **Different MRI patterns in MS worsening after stopping fingolimod**

Caterina Lapucci, Damiano Baroncini, Maria Cellerino, et al.

*Neurol Neuroimmunol Neuroinflamm* 2019;6;

DOI 10.1212/NXI.0000000000000566

**This information is current as of April 16, 2019**

*Neurol Neuroimmunol Neuroinflamm* is an official journal of the American Academy of Neurology. Published since April 2014, it is an open-access, online-only, continuous publication journal. Copyright © 2019 The Author(s). Published by Wolters Kluwer Health, Inc. on behalf of the American Academy of Neurology.. All rights reserved. Online ISSN: 2332-7812.



<b>Updated Information &amp; Services</b>	including high resolution figures, can be found at: <a href="http://nn.neurology.org/content/6/4/e566.full.html">http://nn.neurology.org/content/6/4/e566.full.html</a>
<b>References</b>	This article cites 10 articles, 1 of which you can access for free at: <a href="http://nn.neurology.org/content/6/4/e566.full.html##ref-list-1">http://nn.neurology.org/content/6/4/e566.full.html##ref-list-1</a>
<b>Subspecialty Collections</b>	This article, along with others on similar topics, appears in the following collection(s): <b>Autoimmune diseases</b> <a href="http://nn.neurology.org/cgi/collection/autoimmune_diseases">http://nn.neurology.org/cgi/collection/autoimmune_diseases</a> <b>Burden of disease</b> <a href="http://nn.neurology.org/cgi/collection/burden_of_disease">http://nn.neurology.org/cgi/collection/burden_of_disease</a> <b>Clinical neurology examination</b> <a href="http://nn.neurology.org/cgi/collection/clinical_neurology_examination">http://nn.neurology.org/cgi/collection/clinical_neurology_examination</a>  <b>MRI</b> <a href="http://nn.neurology.org/cgi/collection/mri">http://nn.neurology.org/cgi/collection/mri</a> <b>Multiple sclerosis</b> <a href="http://nn.neurology.org/cgi/collection/multiple_sclerosis">http://nn.neurology.org/cgi/collection/multiple_sclerosis</a>
<b>Permissions &amp; Licensing</b>	Information about reproducing this article in parts (figures,tables) or in its entirety can be found online at: <a href="http://nn.neurology.org/misc/about.xhtml#permissions">http://nn.neurology.org/misc/about.xhtml#permissions</a>
<b>Reprints</b>	Information about ordering reprints can be found online: <a href="http://nn.neurology.org/misc/addir.xhtml#reprintsus">http://nn.neurology.org/misc/addir.xhtml#reprintsus</a>

*Neurol Neuroimmunol Neuroinflamm* is an official journal of the American Academy of Neurology. Published since April 2014, it is an open-access, online-only, continuous publication journal. Copyright Copyright © 2019 The Author(s). Published by Wolters Kluwer Health, Inc. on behalf of the American Academy of Neurology.. All rights reserved. Online ISSN: 2332-7812.

