

# Prophylactic effect of brimonidine to minimize the incidence of subconjunctival hemorrhage in the early postoperative period after 23G pars plana vitrectomy

Mari Carmen Desco, Julio Cesar Molina Martín, Jorge Mataix-Boronat, Isabel Pascual-Camps, Elena Palacios-Pozo, Marisa Barón-García, David P Piñero<sup>ID</sup> and Amparo Navea-Tejerina

*Ther Adv Ophthalmol*

2021, Vol. 13: 1–7

DOI: 10.1177/  
25158414211045753

© The Author(s), 2021.  
Article reuse guidelines:  
sagepub.com/journals-  
permissions

## Abstract

**Background:** Several studies have investigated and demonstrated the prophylactic effect of brimonidine drops in preventing subconjunctival hemorrhage in some microincisional ophthalmic surgeries, such as intravitreal injections or cataract surgery. However, there are no previous studies investigating this prophylactic effect after 23G microincisional vitreoretinal surgery.

**Aim:** The aim of the current study was to determine whether subconjunctival hemorrhage after 23G pars plana vitrectomy (PPV) could be prevented with the use of prophylactic topical brimonidine.

**Methods:** This was a phase III, prospective, interventional, randomized, controlled single-center clinical trial with a follow-up of 2 weeks. A total of 77 eyes (mean age:  $68.4 \pm 10.7$  years) undergoing 23G PPV were included and randomized into two groups: group 1 including 41 patients receiving prophylactic preoperative treatment with brimonidine, and group 2 (control group) including 36 patients not receiving this prophylactic treatment. Differences in terms of number of conjunctival quadrants affected with subconjunctival hemorrhage were evaluated in each of the follow-up visits.

**Results:** The presence of subconjunctival hemorrhage was similar in both groups the first days after surgery ( $p > 0.05$ ). At the last visit (10–14 days after surgery), this condition was significantly more frequent in control group where there was a significant difference, being more frequent in the control group (7.3% vs 28.6%,  $p = 0.022$ ). The number of conjunctival quadrants affected was also similar in both groups, except for the last visit in which most of the patients treated with brimonidine (92.7%) showed no bleeding compared to 71.4% in control group. No effect on the efficacy of brimonidine treatment of the presence of blood hypertension, diabetes, and antiplatelet or anticoagulant treatment was observed.

**Conclusion:** Brimonidine seems to be a useful option to decrease subconjunctival hemorrhage after microincisional vitreoretinal surgery or improve its resolution during the first postoperative week. This finding should be mainly due to the vasoconstrictor effect of brimonidine.

**Trial registration:** EudraCT, 2012-002895-15 (registered 19 December 2012); <https://www.clinicaltrialsregister.eu/ctr-search/search?query=2012-002895-15>

**Keywords:** brimonidine, conjunctiva, pars plana vitrectomy, subconjunctival hemorrhage, vitreoretinal surgery

Correspondence to:  
**Mari Carmen Desco**  
FISABIO Oftalmología  
Médica, Av. Pío Baroja 12,  
46035 Valencia, Spain.  
[carmen.desco@uv.es](mailto:carmen.desco@uv.es)

**David P Piñero**  
Department of Optics,  
Pharmacology and  
Anatomy, University  
of Alicante, Crta San  
Vicente del Raspeig s/n,  
San Vicente del Raspeig,  
Alicante 03690, Spain.  
[david.pinyero@ua.es](mailto:david.pinyero@ua.es)

**Julio Cesar Molina Martín**  
**Jorge Mataix-Boronat**  
**Isabel Pascual-Camps**  
**Elena Palacios-Pozo**  
**Marisa Barón-García**  
FISABIO Oftalmología  
Médica, Valencia, Spain

**Amparo Navea-Tejerina**  
Instituto de la Retina,  
Valencia, Spain

Received: 23 December 2020; revised manuscript accepted: 24 August 2021.

## Introduction

Brimonidine tartrate is a selective alpha 2 adrenergic receptor agonist that is used for the treatment of ocular hypertension. It binds to alpha 2 adrenergic receptors located in the ciliary body and iris, reducing the production of aqueous humor and increasing uveoscleral drainage.<sup>1</sup> Alpha 2 receptors are predominantly expressed in the veins, and it is possible that alpha 2 receptor agonists for ocular use may have a lower potential for tachyphylaxis and rebound redness.<sup>2</sup> The alpha 1 receptors agonists appear predominantly expressed in the arteries, and therefore the sustained use of highly selective alpha 1 receptor agonists could produce vasoconstrictor-induced tissue ischemia and release of vasodilators.<sup>3</sup> Due to its high binding affinity with alpha 2 receptors, the appearance of mydriasis is rare with the use of topical brimonidine. This effect is fundamentally associated with drugs with high affinity for alpha 1 receptor agonists.<sup>4</sup> Systemic alpha 2 receptor agonists have been studied pharmacologically for their sedative properties and cardiovascular effects. In previous studies with the use of topical brimonidine at concentrations of up to 0.2%, the reported cardiovascular effects are minimal, although fatigue and drowsiness have been reported, especially in pediatric patients.<sup>3</sup> Cases of allergic ocular surface disease have been reported in association with the use of high doses of brimonidine.<sup>5</sup>

Brimonidine has been approved by the US Food and Drug Administration (FDA) as a 0.15% and 0.2% ophthalmic solution that reduces intraocular pressure (IOP) in patients with open angle glaucoma or ocular hypertension.<sup>6</sup> It is also available as a 0.33% topical ointment for treating non-transient facial erythema in adults with rosacea.<sup>7</sup> In addition, it has shown its vasoconstrictor efficacy at low doses (0.025–0.2%), with the potential of reducing bleeding during ophthalmic surgery<sup>4,8,9</sup> or intravitreal injections,<sup>10</sup> and consequently promoting a conjunctival whitening<sup>2,11</sup> prior to any eye surgery. Brimonidine's cosmetic eye whitening effect has also been recently approved by the FDA.<sup>12</sup>

Several studies have already investigated the prophylactic effect of brimonidine drops in preventing subconjunctival hemorrhage in some microincisional ophthalmic surgeries, such as intravitreal injections, cataract surgery, laser in situ keratomileusis (LASIK), or strabismus surgery.<sup>4,8–11</sup> To this date, there are no studies reported investigating this prophylactic effect

after 23G microincisional vitreoretinal surgery. It should be considered that a decrease in the incidence of subconjunctival hemorrhage or postoperative hyperemia after this surgical procedure may significantly improve the postoperative discomfort and the aesthetic result of this surgery. The hypothesis of the current research is that, given the vasoconstriction effect of this drug, its use may be beneficial to diminish the risk of conjunctival vascular damage during surgery, reducing the intra- and postoperative bleeding.

## Methods

### Patients

This study was a single-center, interventional, randomized (1:1), double-blinded, controlled, prospective cohort, phase III clinical trial (EudraCT Eprobri: 2012-002895-15). A total of 77 eyes undergoing 23G microincisional vitreoretinal surgery were included and randomly assigned to one of two groups: group 1 including patients treated with brimonidine drops (2 mg/ml; two drops administered 15 min, and 5 min before surgery) and group 2 (control group) including patients who underwent surgery without previous medication with brimonidine. This concentration of topical brimonidine (2 mg/ml) is the same that is commonly used in the treatment of glaucoma. It has been shown that with this dose, conjunctival whitening is also produced, being the presence of red eye rare when it is used for a very short period. The IOP was measured during the pre- and postoperative evaluation. In all patients, the IOP was considered normal, but the values were not recorded. It should be considered that IOP was not a variable under study in this research.

All surgeries were performed by three experienced surgeons (M.C.D., J.C.M.M., E.P.-P.) that consisted of 23G pars plana vitrectomy (PPV) under peribulbar anesthesia. This type of vitreoretinal surgery was recommended for the treatment of at least one of the following conditions: macular hole, epiretinal membrane, and/or mild vitreous hemorrhage. Scleral indentation was not performed, and additionally sclerotomies were not sutured in any case. There were no differences in surgical time between the two groups.

Inclusion criteria for the clinical trial were men or women older than 18 years, who were going to receive 23G PPV. Exclusion criteria included

other surgeries such as conjunctival incision, known allergy to brimonidine, and subconjunctival hemorrhage in the study eye immediately before surgery. Those patients with antiplatelet or anticoagulant treatment were carefully evaluated preoperatively by an anesthesiology specialist, recommending maintaining both the antiplatelet and anticoagulant treatment as the type of surgery performed (PPV 23G alone without scleral indentation or conjunctival incision) entailed a low risk of bleeding perfectly assumable by an expert surgeon in vitreoretinal interventions.

The sample of 77 eyes was recruited during a period of 52 months, from February 2013 until December 2016. All patients were informed about the nature of the study before their participation, only including those giving written informed consent.

Chronic treatment with topical brimonidine is known to cause red eye. In this case, the patients only received brimonidine promptly 15 min, and 5 min before surgery, and none had a red eye after its instillation. The patients were asked whether they had an allergy to the active ingredient. None of them had previously used it.

### *Clinical protocol*

The current clinical trial included a total of four visits:

- Visit 1: Inclusion visit (0–15 days before surgery). Patients were evaluated to confirm the fulfillment of the inclusion/exclusion criteria.
- Visit 2: Surgery day. Randomization was performed 30 min before surgery and pre-treatment with brimonidine was prescribed in group 1. After surgery, the surgeon performed the first postoperative external evaluation to detect the presence of subconjunctival hemorrhage. The analysis was performed in the four different quadrants, and the area of extension of the hemorrhage was measured if it was present.
- Visit 3: Follow-up (1–3 days after surgery). A biomicroscopic analysis was performed in the four different quadrants, and the area of extension of the hemorrhage was measured if it was present.
- Visit 4: Follow-up (10–14 days after surgery). The same analysis as in visit 3 was conducted.

The principal variable was the number of quadrants affected by subconjunctival hemorrhage in each of the follow-up visits. Measurements of the hemorrhage area were performed with a surgical caliper in visit 2 and using the slit lamp biomicroscope in visits 3 and 4. Secondary variables included presence of blood hypertension, diabetes mellitus, or antiplatelet or anticoagulant treatment.

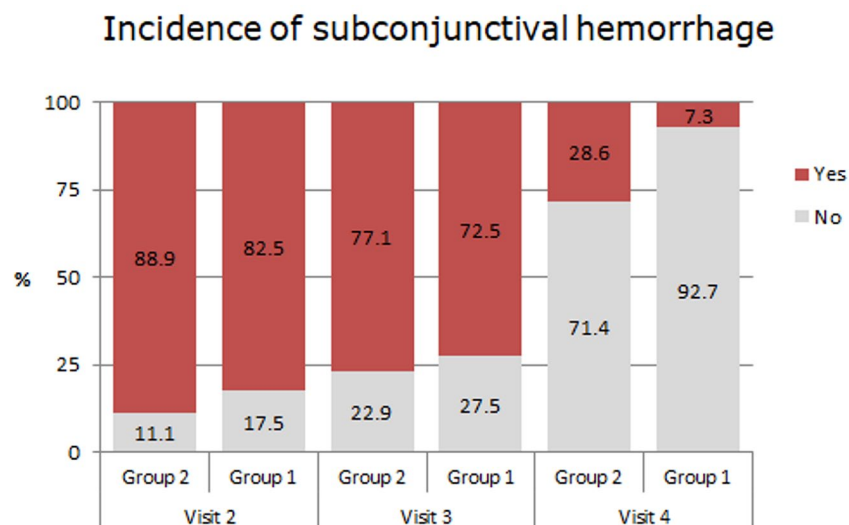
### *Data analysis*

The primary objective of the current clinical trial was to determine whether subconjunctival hemorrhage after 23G PPV could be prevented or whether its extension could be reduced with the preoperative use of brimonidine. The secondary objective was to determine whether individual previous conditions (diabetes mellitus, blood hypertension, or antiplatelet or anticoagulant treatment) could affect this potentially prophylactic effect.

Descriptive and inferential statistical analysis was performed using the SPSS software (IBM Corporation, Armonk, NY, USA). Chi-square independence test was used to evaluate the association between the presence of hemorrhage in each group and in each time-point. The Mann–Whitney test was used to assess the homogeneity in the distribution of the number of affected quadrants and maximum size in each time-point of the follow-up. Differences between treatment and control groups considering demographic and clinical factors were evaluated with the Pearson's chi-square, Fisher's exact, and Student's *t* tests.

### *Results*

The sample evaluated included 77 eyes from 77 patients, with a balanced distribution in terms of gender (male/female, 50.6%/49.4%). Age of patients recruited ranged from 28 to 86 years, with a mean value of  $68.4 \pm 10.7$  years. A total of 41 patients were included in group 1 (patients receiving prophylactic treatment with brimonidine) and 36 patients in group 2 (control group). Both groups were homogeneous in terms of age ( $p = 0.117$ ), gender ( $p = 0.915$ ), treatment with antiplatelet ( $p = 0.962$ ) or anticoagulant drugs ( $p = 0.699$ ), and presence of blood hypertension ( $p = 0.206$ ) and diabetes mellitus types I ( $p = 0.679$ ) and II ( $p = 0.735$ ).



**Figure 1.** Incidence of subconjunctival hemorrhage in groups 1 (brimonidine group) and 2 (control group) of the current study during the follow-up.

Regarding the presence of subconjunctival hemorrhage, the rate of eyes affected in the first post-operative visit (visit 3) was similar in both groups ( $p > 0.05$ ), with a minimal trend of a higher percentage of this condition in the group of untreated patients. In visit 4, a significant difference in the incidence of subconjunctival hemorrhage was found between groups 1 and 2 ( $p = 0.022$ ), with only 7.3% of eyes showing this condition in group 1 and 28.6% of eyes in group 2 (Figure 1). The number of conjunctival quadrants affected by subconjunctival hemorrhage only differed significantly during the follow-up in the last visit ( $p = 0.018$ ). Most patients treated with brimonidine (92.7%) did not show subconjunctival hemorrhage at the end of the follow-up, whereas this percentage was 71.4% in the control group or group 2 (Figure 2). In terms of severity, 8.6% of eyes of group 2 had two or more quadrants affected compared to 4.9% of eyes in group 1 (Figure 2). The maximum diameter of the largest hemorrhage detected in each visit of the study was also measured, but differences between groups did not reach statistical significance (visit 2,  $p = 0.587$ ; visit 3,  $p = 0.685$ ; visit 4,  $p = 0.876$ ).

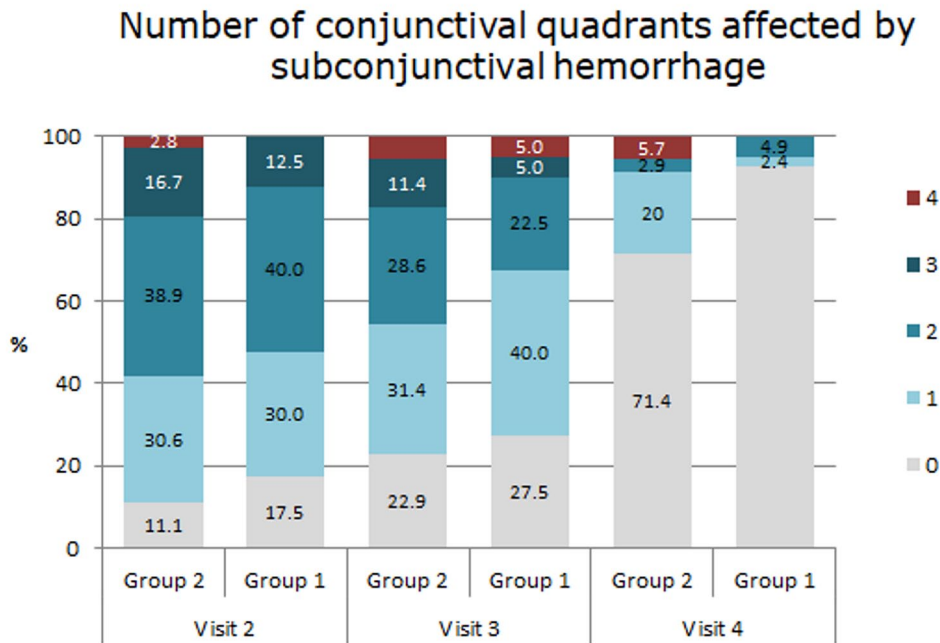
Regarding the effect of antiplatelet and anticoagulant treatments, only six patients in group 2 and seven patients in group 1 referred to take antiplatelet drugs, whereas anticoagulant treatments were prescribed in four patients in group 2 and three patients in group 1. Although there was a

trend to a better hemorrhagic result in eyes in group 1, differences between groups as a function of this type of treatments did not reach statistical significance ( $p = 0.235$ ). The presence of high blood pressure or diabetes mellitus did not produce any relevant effect on the presence and extent of subconjunctival hemorrhage in both groups ( $p \geq 0.065$ ).

No adverse effects or serious adverse effects were recorded throughout the clinical trial.

## Discussion

This is the first study evaluating the potential benefit of the prophylactic use of brimonidine preoperatively in terms of decreasing the risk of conjunctival vascular damage during and after vitreoretinal surgery. Therefore, our results cannot be compared with any previous study. However, some previous research has demonstrated the preventive effect of brimonidine to avoid the occurrence of subconjunctival hemorrhage in other ophthalmic surgeries, such as LASIK, intravitreal injections, strabismus surgery, and phacoemulsification cataract surgery.<sup>4,8-11</sup> Ucar and Cetinkaya<sup>13</sup> recently published a study evaluating the topical use of brimonidine in 22 patients prior to strabismus surgery to determine its efficacy in relation to the reduction of conjunctival bleeding and the possible better visualization of anatomical structures during surgery. These authors concluded that



**Figure 2.** Number of conjunctival quadrants affected by subconjunctival hemorrhage in groups 1 (brimonidine group) and 2 (control group) of the current study during the follow-up.

the use of topical brimonidine before strabismus surgery facilitates clear monitoring of anatomical structures during surgery by effectively controlling hemorrhage. In the postoperative period, it significantly reduces subconjunctival hemorrhage.<sup>13</sup> According to this, brimonidine might allow greater precision when placing and removing the 23G trocar during PPV as well as a better evaluation of the scleral incisions once the surgery is completed. In any case, it should be noted that vitreoretinal surgery is longer in duration and includes more manipulation of the ocular (conjunctiva–sclera–choroid) tissues, especially when introducing microcannulas, than other microincisional surgeries. In a case series study conducted in patients who underwent PPV for epiretinal membrane peeling or macular hole repair, ophthalmic brimonidine tartrate 0.1% (topical solution) was prescribed to be applied twice a day for a week before the surgery.<sup>14</sup> At the time of the surgery, most patients had a vitreous brimonidine concentration greater than 2 nM, and brimonidine at these concentrations is known to activate alpha 2 receptors in animal retinas, playing a neuroprotective role. In addition, the affinity of brimonidine for alpha 2 versus alpha 1 receptor is 790 times greater which allows for a greater and faster vasoconstrictor effect.<sup>8,10</sup>

Desco and colleagues<sup>9</sup> studied the effect of brimonidine in terms of reducing the incidence of subconjunctival hemorrhage after cataract surgery. These authors concluded that the preoperative use of brimonidine could significantly reduce the incidence of this condition in subjects undergoing this surgical procedure. A case-control study was also conducted to evaluate the efficacy of brimonidine to reduce the level of conjunctival and episcleral hyperemia, and postoperative bleeding after pterygium surgery.<sup>4</sup> This clinical research concluded that brimonidine reduced the level of postoperative bleeding in at least 50% of patients using this prophylactic treatment compared to a control group. A possible factor accounting for the fact that only statistically significant differences in subconjunctival hemorrhage were only detected in the visit 4 may be the placement and removal of microcannulas in vitrectomy, which is quite aggressive for the conjunctival tissue in all patients. In summary, our results are consistent with those confirming the potential of brimonidine as a preventive treatment of subconjunctival hemorrhage in other types of ocular surgery. A recent meta-analysis from four clinical trials evaluating the efficacy and safety of 0.025% brimonidine tartrate as a topical vasoconstrictor for eye redness concluded that this pharmacological agent is effective reducing eye redness with a good safety and tolerance



profile and without tachyphylaxis or rebound eye redness.<sup>2</sup>

The level of anxiety in patients requiring vitreoretinal surgery is often high due to the severity of their pathology and the concern about surgery itself.<sup>15</sup> Vitrectomy surgery with the use of microcannulas has shortened the duration of the postoperative period, avoiding the need to use stitches, which has also reduced postoperative discomfort. Postoperative subconjunctival hemorrhage is very striking and is usually a cause of concern in patients and family members. In addition, a subconjunctival blood collection may worsen the ocular surface discomfort associated with this surgery.<sup>8</sup> Therefore, a simple maneuver, with less adverse effects, such as brimonidine instilling, can provide some benefits to patients undergoing vitreoretinal surgery. In the current study, no difference in the prophylactic effect of brimonidine was found between patients taking antiplatelet drugs and those with no medication (control group), as in a previous study evaluating the preventive after another type of ocular surgical intervention.<sup>9</sup> This non-statistically significant result could obviously be related to the significant limitation of the sample size in the group of patients who received antiplatelet therapy. Future studies including larger sample sizes would be necessary to achieve greater number of diabetic and hypertensive patients or under treatment with antiaggregants and anticoagulants, since they are the patients with the highest risk of surgical bleeding, and possibly those who could have the greatest benefit from this prophylactic treatment. Specifically, it should be noted that only six patients in the control group and seven in the treatment group took antiplatelet drugs in the current series.

The main limitation of the current study is the size of the sample that did not allow to achieve a greater number of diabetic and hypertensive patients or patients treated with antiaggregants and anticoagulants, which are the patients with the highest risk of surgical bleeding and possibly those with potential of showing the most relevant benefit with this prophylactic treatment. Furthermore, the standardization of smaller caliber of vitrectomy would change the current state and it would have to be verified with these microcannulas, although the conjunctival aggression at the entrance and exit to the sclera-choroid may be similar.

## Conclusion

In conclusion, the prophylactic use of brimonidine before microincisional vitreoretinal surgery seems to be useful to decrease the incidence of subconjunctival hemorrhage postoperatively and to accelerate its resolution in the first postoperative week, minimizing patient discomfort and aesthetic discomfort. This finding is mainly due to the vasoconstrictor effect of brimonidine. Future studies with larger sample sizes are needed to corroborate these findings.

## Author contributions

M.C.D. contributed to concept, data analysis, data gathering, writing of the manuscript, and supervision; J.C.M.M. contributed to concept, data gathering, critical revision of the manuscript, and supervision; J.M.-B., I.P.-C., E.P.-P., and M.B.-G. helped in data gathering, critical revision of the manuscript, and supervision; D.P.P. contributed to concept, data analysis, critical revision of the manuscript, and supervision; A.N.-T. contributed to concept, data analysis, data gathering, writing of the manuscript, supervision, and coordination. All authors read and approved the final manuscript.

## Conflict of interest statement

The authors declared no potential conflicts of interest with respect to the research, authorship, and/or publication of this article.

## Funding

The authors disclosed receipt of the following financial support for the research, authorship, and/or publication of this article: D.P.P. has been supported by the Ministry of Economy, Industry and Competitiveness of Spain within the program Ramón y Cajal, RYC-2016-20471.

## Ethics statement

This clinical trial was conducted following the current Spanish and European legislation, respecting the standards of good clinical practice and according to the tenets of the Declaration of Helsinki. This study was approved by the Ethics Committee of FISABIO Valencia (EPROBRI-2011; EC41) and was registered in EudraCT (#2012-002895-15; <https://www.clinicaltrialsregister.eu/ctr-search/search?query=2012-002895-15>). All patients were informed about the study prior to their inclusion and signed a written informed consent before being examined.


**ORCID iD**

David P Piñero  <https://orcid.org/0000-0002-1546-4807>

**References**

1. Rahman MQ, Ramaesh K and Montgomery DM. Brimonidine for glaucoma. *Expert Opin Drug Saf* 2010; 9: 483–491.
2. Ackerman SL, Torkildsen GL, McLaurin E, *et al.* Low-dose brimonidine for relief of ocular redness: integrated analysis of four clinical trials. *Clin Exp Optom* 2019; 102: 131–139.
3. Torkildsen GL, Sanfilippo CM, DeCory HH, *et al.* Evaluation of efficacy and safety of brimonidine tartrate ophthalmic solution, 0.025% for treatment of ocular redness. *Curr Eye Res* 2018; 43: 43–51.
4. Ucar F and Cetinkaya S. The results of preoperative topical brimonidine usage in pterygium surgery. *J Ocul Pharmacol Ther* 2020; 36: 234–237.
5. McLaurin E, Cavet ME, Gomes PJ, *et al.* Brimonidine ophthalmic solution 0.025% for reduction of ocular redness: a randomized clinical trial. *Optom Vis Sci* 2018; 95: 264–271.
6. Fudenberg SJ, Batiste C and Katz LJ. Efficacy, safety, and current applications of brimonidine. *Expert Opin Drug Saf* 2008; 7: 795–799.
7. Fowler J Jr, Jackson M, Moore A, *et al.* Efficacy and safety of once-daily topical brimonidine tartrate gel 0.5% for the treatment of moderate to severe facial erythema of rosacea: results of two randomized, double-blind, and vehicle-controlled pivotal studies. *J Drugs Dermatol* 2013; 12: 650–656.
8. Pasquali TA, Aufderheide A, Brinton JP, *et al.* Dilute brimonidine to improve patient comfort and subconjunctival hemorrhage after LASIK. *J Refract Surg* 2013; 29: 469–475.
9. Desco MC, Navea A, Ferrer E, *et al.* Effect of prophylactic brimonidine on bleeding complications after cataract surgery. *Eur J Ophthalmol* 2005; 15: 228–232.
10. Kim CS, Nam KY and Kim JY. Effect of prophylactic topical brimonidine (0.15%) administration on the development of subconjunctival hemorrhage after intravitreal injection. *Retina* 2011; 31: 389–392.
11. Dahlmann-Noor AH, Cosgrave E, Lowe S, *et al.* Brimonidine and apraclonidine as vasoconstrictors in adjustable strabismus surgery. *J AAPOS* 2009; 13: 123–126.
12. US Department of Health & Human Services and Food and Drug Administration. Approval package for: Lumify Ophthalmic Solution, 0.025%, 2017, [https://www.accessdata.fda.gov/drugsatfda\\_docs/nda/2017/208144Orig1s0000Approv.pdf](https://www.accessdata.fda.gov/drugsatfda_docs/nda/2017/208144Orig1s0000Approv.pdf) (accessed 18 August 2019).
13. Ucar F and Cetinkaya S. The results of preoperative use of topical brimonidine in strabismus surgery. *J Ocul Pharmacol Ther* 2021; 37: 230–235.
14. Takamura Y, Tomomatsu T, Matsumura T, *et al.* Vitreous and aqueous concentrations of brimonidine following topical application of brimonidine tartrate 0.1% ophthalmic solution in humans. *J Ocul Pharmacol Ther* 2015; 31: 282–285.
15. Mimouni M, Abualhasan H, Mtanes K, *et al.* Patients' experience of anxiety and pain during retrobulbar injections prior to vitrectomy. *J Ophthalmol* 2019; 2019: 8098765.

Visit SAGE journals online  
[journals.sagepub.com/  
home/oed](https://journals.sagepub.com/home/oed)

 SAGE journals