

Thrombosis and Haemostasis

Carotid Stenosis and Stroke: Medicines, Stents, Surgery – “Wait-and-See” or Protect?

Piotr Musialek, Kenneth Rosenfield, Adnan Siddiqui, Iris Q Grunwald.

Affiliations below.

DOI: 10.1055/a-1952-1159

Please cite this article as: Musialek P, Rosenfield K, Siddiqui A et al. Carotid Stenosis and Stroke: Medicines, Stents, Surgery – “Wait-and-See” or Protect?. *Thromb Haemost* 2022. doi: 10.1055/a-1952-1159

Conflict of Interest: The authors declare that they have no conflict of interest.

Abstract:
no abstract

Corresponding Author:

Piotr Musialek, Jagiellonian University in Kraków Medical College, Dept of Cardiovascular Medicine, John Paul II Hospital, Krakow, Poland, prmusialek@gmail.com

Affiliations:

Piotr Musialek, Jagiellonian University in Kraków Medical College, Dept of Cardiovascular Medicine, John Paul II Hospital, Krakow, Poland
Kenneth Rosenfield, Division of Cardiology, Vascular Medicine and Intervention Section, Massachusetts General Hospital, Boston, United States., Division of Cardiology, Vascular Medicine and Intervention Section, Massachusetts General Hospital, Boston, United States.
Boston, United States

Adnan Siddiqui, Departments of Neurosurgery and Radiology, School of Medicine and Biomedical Sciences, University at Buffalo, State University of New York, Jacobs Institute, Gates Vascular Institute Kaleida Health, Buffalo, New York, USA, Departments of Neurosurgery and Radiology, School of Medicine and Biomedical Sciences, University at Buffalo, State University of New York, Jacobs Institute, Gates Vascular Institute Kaleida Health, Buffalo, New York, USA, Buffalo, United States

Iris Q Grunwald, University of Dundee, Chair of Neuroradiology, Department of Radiology, Ninewells Hospital, Dundee, Scotland, United Kingdom, University of Dundee, Chair of Neuroradiology, Department of Radiology, Ninewells Hospital, Dundee, Scotland, United Kingdom, Dundee, United Kingdom of Great Britain and Northern Ireland

Carotid Stenosis and Stroke: Medicines, Stents, Surgery – “Wait-and-See” or Protect?

Piotr Musialek^{1,2}, Kenneth Rosenfield³, Adnan H Siddiqui⁴, Iris Q Grunwald⁵

¹Jagiellonian University Department of Cardiac and Vascular Diseases, Krakow, Poland

²John Paul II Hospital Thrombectomy-Capable Stroke Centre, Krakow, Poland

³Division of Cardiology, Vascular Medicine and Intervention Section, Massachusetts General Hospital, Boston, United States.

⁴Departments of Neurosurgery and Radiology, School of Medicine and Biomedical Sciences, University at Buffalo, State University of New York, Jacobs Institute, Gates Vascular Institute Kaleida Health, Buffalo, New York, USA

⁵University of Dundee, Chair of Neuroradiology, Department of Radiology, Ninewells Hospital, Dundee, Scotland, United Kingdom

Corresponding Author

Piotr Musialek, MD DPhil

Jagiellonian University Department of Cardiac and Vascular Diseases

John Paul II Hospital

ul. Pradnicka 80, 31-202 Krakow, Poland

e-mail: pmusialek@szpitaljp2.krakow.pl

Carotid Stenosis and Stroke Mechanisms

Stroke, a vascular disease of the brain, is the most common cause of complex disability and a major cause of death worldwide^{1,2,3}. Stroke, with its major negative impact on affected individuals, their families and the society, is one of the most dreaded events in life⁴. Nearly half of stroke survivors will be disabled and dependent, with 1 in 7 requiring permanent institutional care⁴. Because of the profound negative effect of stroke-related mental and physical disabilities upon quality of life, a significant proportion of stroke victims indicate that they would have preferred death over their life after stroke⁴. Only a minority of strokes are preceded by a transient ischaemic attack (TIA), a warning

that enables timely intervention to reduce the risk of permanent brain damage^{5,6}. Over 80% of strokes occur without any clinical warning⁶. Hence there is a fundamental role for effective preventive measures^{6,7}. Optimal stroke management should be preventive rather than reactive to the devastating event that has already occurred^{5,7,8}. Despite unquestionable progress in pharmacologic and non-pharmacologic prevention, the burden of cardiovascular disease (including stroke) will not be decreasing – but rather increasing – over the next 25 years¹. Recent stroke burden estimates for Europe indicate an increase in stroke incidence of +3% by 2047, and an increase by ≈30% of the number of people living with stroke⁹.

Atherosclerotic carotid artery stenosis is a modifiable, major mechanistic risk factor of ischemic stroke^{2,10}. Plaque rupture and/or erosion can lead to focal thrombus formation that may occlude the lumen, causing a stroke related to haemodynamic compromise¹⁰⁻¹². Another stroke mechanism is athero-thromboembolism to the brain, resulting in occlusion of an intracranial branch vessel(s) and infarction of the brain tissue supplied by these branches¹⁰⁻¹³. Real-life contemporary scenarios of acute ischaemic stroke due to athero-thrombotic carotid stenosis are demonstrated in **Fig 1** (all patients presenting with acute stroke of carotid origin in January 2022).

Stroke Occurrence in Carotid Atherosclerosis: Epidemiology

Atherosclerotic carotid disease is responsible for a much greater proportion of strokes than just those presenting with both a carotid lesion and intracerebral artery occlusion in stroke thrombectomy studies (≈15-20% “tandem occlusion” stroke patients in stroke thrombectomy all-comer registries^{11,12}). Major trials of stroke mechanical reperfusion excluded patients with “tandem” lesions and excluded patients with acute occlusion of the internal carotid artery origin (high-risk pathologies)¹². Some other atherothrombotic lesions at the carotid bifurcation may become “insignificant” by angiography after part of the lesion has embolized to the brain.¹² Although lower proportional contributions of atherosclerotic carotid stenosis to overall stroke burden have been claimed in the past^{15,16}, the totality

of data suggests an overall proportion of carotid stenosis related strokes at the level of at least 30%^{11,13,16}.

Clinically “significant” atherosclerotic carotid artery disease, usually (though not always rightly, as less severe lesions may cause strokes) defined as $\geq 50\%$ reduction in diameter at the carotid bifurcation and/or within the proximal internal carotid artery, is present in 2% to 16% of the general population, making it a common pathology^{8,11,17,18}. Its prevalence is similar to that of nonvalvular atrial fibrillation (AFib) and, like AFib, it increases with age². Notably, carotid stenosis is more prevalent in patients with diabetes, coronary artery disease, and peripheral artery disease^{2,8,19,20}. Contemporary clinical data from vascular clinics following patients with known vascular disease, show a yearly stroke rate of $\approx 2.5\%$ in real-life cohorts, including patients on maximal (by today’s criteria) medical therapy^{8,20,22}. This exceeds the annual stroke risk of 2.1% per year associated with paroxysmal AFib²³ that has been the focus of stroke prevention. A recent population-based study in 65 year old Swedish men showed a five-year cumulative neurological event rate of 6.5% with carotid stenosis of 50-79% (annual rate 1.3%) and 42% with stenosis of 80-99% (annual rate 18.4%)²⁴. Although the stroke risk may be lower in younger individuals with asymptomatic carotid artery stenosis (ACAS)^{8,15,16}, given that the risk (similar to the stroke risk in AFib²³) is cumulative over time, it remains very relevant.

Other factors may contribute to stroke risk in patients with ACAS. These may be related to the atherosclerotic lesion (note modulation of the atherosclerotic plaque rupture and thrombosis by the haemostatic system²⁵⁻²⁷) or may contribute independently to the increased stroke risk (eg. coexisting AFib²³). There are additional concerns raised on the impact of hemodynamically significant carotid atherosclerotic disease in patients with an incompetent circle of Willis and cognitive decline potentially related to hemodynamic insufficiency and subclinical embolism from the lesion^{28,29}. Overall, epidemiologic data indicate that the presence of ACAS may increase the risk of stroke by more than 50%³⁰.

Pharmacomanagement: The pillar of Therapy to Reduce the Stroke Risk in Patients with Atherosclerotic Carotid Artery Stenosis

Medical therapy reduces stroke risk in ACAS, but the residual risk remains substantial, particularly in patients with vascular comorbidities or diabetes^{19,20,22,31}. The progress in pharmacologic prevention in cardiovascular medicine over the last two decades, including the use (and currently high penetration) of statins, antiplatelet agents and angiotensin-converting enzyme inhibitors/angiotensin receptor blockers, has led to a reduction in the statistical stroke risk in patients with ACAS. Subgroup analyses of pharmacologic trials suggest a stroke reduction benefit in ACAS patients treated with the above medications^{8,13}. Based on this information, all ACAS patients today should receive maximised, medical therapy (MMT) to reduce stroke risk. The regimen should include i) an antiplatelet agent and ii) an angiotensin-converting enzyme inhibitor or angiotensin receptor blocker with iii) a statin (or other agent to reduce LDL-cholesterol) titrated to achieve guideline-recommended LDL-cholesterol levels as well as lifestyle modification³¹. MMT benefit needs to be individually balanced against potential adverse effects, such as an increase in bleeding with antiplatelet therapy³², and the residual stroke risk while on medications^{22,33,34}.

Despite the progress that has been made, the transition of a carotid lesion from asymptomatic to symptomatic lesion is far from being eradicated by MMT^{20,22,34}. This limitation of MMT is clearly demonstrated within the symptomatic patients cohort enrolled into recent clinical studies, a significant proportion of whom suffered a stroke despite MMT^{35,36} (see also Fig 1).

Stroke Risk Factors and Risk Markers in ACAS

Clinical studies have identified several risk markers and factors for stroke in ACAS patients^{8,13,20,30,35}. These are depicted in Fig 2. It is unclear why some of these have made it into clinical guidelines³⁷ while others have not. An update may be appropriate in this respect, in order to encourage clinical decision-making that takes into consideration the totality of evidence.

Is it Possible to Quantify Stroke Risk and Target Preventive Measures in Carotid Disease today?

Evidence suggests that there may be a gradient of stroke risk in ACAS. Calculation of stroke risk would be clinically useful, helping physicians and patients to make therapeutic decisions. In AFib clinical decision making is guided by well-defined scales (such as classic CHA₂DS₂-VASC scale or a more recent calculator of absolute stroke risk in AFib, CARS)³⁸. Regrettably, in carotid disease, for which stroke risk is of similar magnitude, these do not exist. Effort should be made to develop and validate stroke risk scales in ACAS similar to the established stroke risk scales in AFib^{33,38}.

The Paramount Role of Imaging in Delineating Stroke Risk

In medicine, as in other areas of life, effective prevention is better than reactive management. Prevention relies on reliable detection of the problem^{7,8}. Detection of ACAS by ultrasound does not cause harm nor necessitates an invasive intervention. Failure to identify ACAS results in lack of any treatment, including introducing (or maximizing) pharmacotherapy^{7,31,39}, and an important missed opportunity to reduce stroke risk. High-risk plaques are not rare in ACAS⁴⁰⁻⁴². Recent real-life evidence clearly shows that the associated risk of ipsilateral ischemic stroke in ACAS is higher than previous estimates^{24,43}. Meta-analysis of 64 studies (20,751 participants) showed that over a median observation time of merely 3 years, the high-risk carotid plaque, reproducibly detected by non-invasive imaging, translates into an increased risk of an ipsilateral stroke (OR 3.0, 95%CI 2.1-4.3)⁴⁰. In subjects with severe ACAS, the OR was similar (3.2, 95% CI 1.7-5.9), confirming that plaque features may play a more important role severity of stenosis⁴⁰. Strokes in relation to high-risk plaques continue to occur in patients on MMT^{35,44}. With the evidence today that non-invasive imaging can reliably identify ACAS patients at an increased of stroke, the question is not whether to screen or not but rather which populations to target and with which screening techniques. ACAS screening is cost-

effective already when a moderate (such as $\approx 20\%$) stroke risk relative reduction is achieved with preventive measures that result from screening⁴⁵.

A multi-society evidence-based guideline recommended that screening for carotid stenosis should be considered for asymptomatic patients with either: 1) symptomatic PAD, CAD, or atherosclerotic aortic aneurysm, or 2) two or more of the following risk factors: hypertension, hyperlipidemia, tobacco smoking, a family history of early-onset (less than 60 years) atherosclerotic disease in a first-degree relative, or a family history of ischemic stroke³⁹.

The fundamental advantage of non-invasive imaging is that there is no need to enter the body. A disadvantage of CT or MRI is the limited resolution that prevents analysis of, for instance, the risk-prone thin fibrous cap thickness, which in carotids is $\approx 160\text{-}200$ vs. ≈ 65 μm in the coronaries⁴². Similarly, a limitation of transcutaneous ultrasound is its poor reproducibility in plaque evaluation and incomplete 3D information. Because of these inherent limitations, intravascular imaging can serve as an important companion to the non-invasive techniques. In addition to expanding our knowledge by providing unique data on plaque morphology, it may guide development of further treatments^{41,42}. Moreover, intravascular imaging modalities such as optical coherence tomography or intravascular ultrasound, provide fundamental tools to understand plaque behaviour with different stent types and the intravascular consequences of stenting⁴¹. Routine evaluation of in-stent plaque prolapse in clinically symptomatic or clinically silent ipsilateral embolism patients implanted with a second-generation, micronet-covered stent is currently under way in a multicenter study (NCT04234854).

Another important role for imaging in ACAS is the detection of subclinical cerebral injury with MRI or CT (silent infarcts) that increase the risk of subsequent clinically-manifested stroke 2-fold²². Although ACAS plaque haemorrhage, rupture and thrombosis are typical features of conversion to a symptomatic plaque, it is important to bear in mind that these are also the mechanisms of “normal” plaque growth^{10,11}, and only some haemorrhage, rupture and thrombosis events are associated with clinical symptoms. Hence the role of other fundamental players, such as ‘vulnerable blood’⁴⁶ and the haemostatic system that is known to modulate atherothrombotic events²⁵⁻²⁷ (Fig 2).

Conventional Surgery and Conventional CAS

If carotid stenosis-related strokes are to be prevented rather than experienced, interventional elimination or sequestration of the thromboembolic plaque remains an important consideration in a significant proportion of ACAS patients^{8,13,17}. ACAS revascularisation should be i) safe, ii) effective (short and long-term) and, with the first two achieved, iii) minimally invasive. Optimally, it should prevent stroke rather than be performed in reaction to the irreversible cerebral damage that has already occurred^{7,8} (Fig 1). While undertaken to prevent subsequent stroke, an important consideration is that both surgical and endovascular routes of carotid revascularization are themselves associated with the risk of symptomatic and asymptomatic cerebral embolism^{29,48}.

One fundamental difference between open surgery and endovascular methods is that by removing the lesion, carotid endarterectomy (CEA) largely eliminates the post-procedural problems that may be related to offending the plaque; however, that is at risk for creating new source of cerebral emboli such as vessel injury and or dissection flap. In contrast, conventional carotid artery stenting (CAS) does not remove plaque but seeks to stabilize the potentially embolic lesion by restoring laminar flow and covering the lesion with a single-layer metallic stent⁴⁷. Plaque protrusion through the stent struts occurs in 30% to 100% of conventional carotid stents, depending on the plaque morphology and stent design, as well as well as the sensitivity of the imaging technique used^{8,48,49}. Plaque protrusion may lead to peri- and post-procedural cerebral embolism and trigger post-CAS neurological events including (mostly minor) strokes^{8,50}. This has been attributed as the primary cause of post procedure stroke, with $\approx \frac{2}{3}$ of CAS strokes occurring after the CAS procedure using conventional (single-layer) carotid stents^{48,51}. Thus, while optimised neuroprotection during CAS may minimise intraprocedural cerebral embolism, the risk of early or delayed post-procedural embolism remains a significant issue when using single-layer stents^{8,49}. In a recent meta-analysis of 6,526 patients from 5 trials comparing CAS and CEA⁵¹, the composite outcome of periprocedural death, stroke, myocardial infarction or non-periprocedural ipsilateral stroke was not significantly different

between therapies (OR: 1.22; 95% CI: 0.94 to 1.59). The risk of any periprocedural stroke plus non-periprocedural, ipsilateral stroke was higher with CAS (OR: 1.50; 95% CI: 1.22 to 1.84) which was mostly attributed to periprocedural minor stroke (OR: 2.43; 95% CI: 1.71 to 3.46). CAS was associated with a significantly lower risk of periprocedural myocardial infarction (OR: 0.45; 95% CI: 0.27 to 0.75); cranial nerve palsy (OR: 0.07; 95% CI: 0.04 to 0.14) and the composite outcome of death, stroke, myocardial infarction, or cranial nerve palsy during the periprocedural period (OR: 0.75; 95% CI: 0.60 to 0.93). Despite the lack of plaque elimination and incomplete coverage of the plaque with CAS using first-generation (single-layer) carotid stents, two recent RCTs have shown equipoise between conventional CAS and conventional CEA^{52,53}. In the Asymptomatic Carotid Trial I (ACT -1) the primary composite 30-day endpoint rate was 3.8% with first-generation CAS and 3.4% with CEA (p = 0.01 for noninferiority)²⁷. In the second asymptomatic carotid surgery trial (ACST-2) that randomly allocated 3,625 patients to CAS (n=1811) or CEA (n= 1814) with a mean follow-up of 5 years, more major procedural strokes occurred with CEA (0.99% vs. 0.82%), while CAS was associated with more non-disabling strokes (2.65% vs 1.60%). There was no statistically significant difference in the incidence of any peri-procedural stroke (3.6% vs 2.4% , p= 0.06) and long-term effects of both procedures was comparable^{53,54}. Similarly, meta-analysis of CEA and CAS outcomes in symptomatic patients has demonstrated similar outcomes in the post-procedural period⁵⁵. These data, taken together with a further reduction in peri-procedural stroke rate to <1% by 30 days using micronet-covered stents and coupled with their long-term treatment durability suggest that a more effective endovascular plaque sealing than that achieved in ACST-2 (with mostly first-generation stents), has the potential to achieve outcomes superior to open surgery⁵⁶. It should be noted that the importance of carotid revascularization endpoints other than stroke risk, such as cognitive or ocular function, is gaining increasing recognition^{28,29,57}.

Transcervical Access for CAS – why? (and its limitations today)

Transcervical carotid revascularization (TCR) is a hybrid technique that has gained popularity primarily in the United States with now nearly 20,000 cases performed worldwide. TCR, using surgical access (surgical cut-down) employs a robust transient flow reversal to protect the brain during lesion predilatation, stent delivery and implantation and postdilatation⁵⁸. One fundamental advantage of this technique, compared to transfemoral or transradial CAS, is that it eliminates the need for transversing the aortic arch and ostial common carotid artery – the CAS stages known to be generating emboli, particularly in elderly patients, or those who have atherosclerotic aortic or ostial lesions, calcified vessels or a complex/tortuous aortic arch⁵⁸. However, a recent systematic review and meta-analysis of 4,867 TCR procedures in 18 clinical studies showed that symptomatic patients had a higher risk of 30-day stroke or TIA than asymptomatic patients (2.5% vs. 1.2%; odds ratio 1.99; 95% CI 1.01-3.92; p =0.046)⁵⁸. This indicates a likely contribution of incomplete plaque coverage with a first-generation (single-layer) stent used in TCA to-date to the increased event rate in symptomatic patients. Pilot data, using diffusion-weighted cerebral magnetic resonance imaging (DW-MRI), suggest that the use of a second-generation (plaque-sealing) micronet-covered stent rather than a prior-generation single-layer stent, may minimize peri- and post-procedural embolism in TCR⁵⁹. This is currently under systematic investigation in the TOP-GUARD study (NCT04547387). Other important TCR considerations, such as the need to optimally manage the angle upon carotid artery entry (that may pose a challenge), are discussed elsewhere^{58,59}.

Novel Pharmacologic Approaches and Drugs

Thrombosis is known to be the most common precipitant of ischaemic stroke. Recently, it has become clear that not only the mechanisms of haemostasis may modulate the atherosclerotic plaque phenotype but also that fibrin clot properties affect the clinical manifestations of atherosclerosis²⁵⁻²⁷. Elucidation of fibrin clot properties in symptomatic versus asymptomatic carotid stenosis is under investigation in the FIB-CAR (FIBrin Clot properties in carotid Atherosclerotic disease) study a series of 200 consecutive patients. While this may be hampered by the “future-symptomatics” hiding within the current ACAS cohort, recent large scale data suggest that pharmacologic modulation of haemostasis

may be effective clinically. Analysis of stroke outcomes in the COMPASS (Cardiovascular Outcomes for People Using Anticoagulation Strategies) study in which with ACAS causing $\geq 50\%$ luminal stenosis was one of the inclusion criteria, demonstrated that the combination of rivaroxabam 2.5mg twice daily (used on top of 100mg aspirin) reduced any stroke and disabling stroke better than aspirin alone, without increasing the risk of haemorrhagic stroke⁶⁰. Although no specific sub-analysis is available for the ACAS patients in COMPASS, reduction in stroke incidence and severity in this study suggests that adding low-dose anticoagulant therapy to antiplatelet therapy might be considered, on an individual basis taking into consideration overall vascular risk, in ACAS patients – particularly in those with increased stroke risk features who are not candidates for plaque removal or sealing. Finally, indirect evidence from clinical trials of proprotein subtilisin/kexin type 9 (PCSK9) suggests a role for these agents at least in some ACAS patients, particularly in those with optimised statin therapy but elevated lipoprotein (a)⁶¹. Although the ‘vulnerable blood’ biomarkers, such as cytokines, may be targets for pharmacotherapy (*eg.*, interleukin-1 β targeting with canakinumab), their role may be difficult to dissect as their level in the plasma may not reflect the level in-situ within the carotid plaque⁴⁶. Several other novel strategies to induce the atherosclerotic plaque regression and/or pacification (such as inhibition of oxidized LDL and other modified lipids receptors) are currently tested in human trials. The interplay between the risk of athero-thrombotic events (including stroke) and fibrin clot properties is gaining increasing relevance. Intensive lowering of LDL cholesterol has been demonstrated to improve fibrin clot properties⁶³. Recent evidence shows that active factor XI is associated with the risk of cardiac and vascular events in patients with coronary atherosclerosis, indicating a potential clinically-relevant role for FXIa inhibitors as novel anti-thrombotic agents⁶⁴. This, and other pathways, may play an important role in reducing athero-thrombotic stroke risk in carotid atherosclerosis (Fig 2).

Novel Paradigm in Carotid Revascularisation: Minimally-Invasive Sequestration of Increased-Stroke-Risk Lesions

Recent body of evidence indicates that the use of ultra-closed-cell stent systems (achieved by covering the nitinol frame with a mesh made of different materials) may not only further reduce the risk of intraprocedural neurologic complications, but also, by preventing plaque protrusion through stent struts, eliminates postprocedural cerebral embolization as demonstrated on diffusion-weighted magnetic resonance imaging (DW-MRI)⁴⁹. This strategy has been termed intra- and post-procedural (sustained) ‘embolic prevention’. Sustained embolic prevention is thus complementary to the classic intra-procedural (temporary) ‘embolic protection’ using proximal (flow cessation or reversal) or distal (filter) devices. Recent evidence indicates that incorporation of the sustained embolic prevention technology in otherwise routine CAS may achieve CEA-like effect, leaving residual embolic source along with no residual stenosis, in both symptomatic and increased-stroke-risk asymptomatic ACAS patients, with peri-procedural complications <1%^{35,36}.

Three mesh-covered carotid stent designs have been CE-marked. They show fundamental differences in the mesh material and design and in its position in relation to the stent frame (polyethylene terephthalate single-fiber knitted mesh in the CGuard micronet-covered stent, braided metallic mesh inside in the Casper/RoadSaver stent, and perforated polytetrafluoroethylene/teflon membrane outside the Gore stent)⁵⁰. These differences, along those in the nitinol frame construction (braided in Casper/RoadSaver, laser-cut in CGuard and Gore stent) may translate into important differences in short- and long-term clinical outcomes. A meta-analysis comparing 30-day and 12-month clinical outcomes with the different mesh-covered stents (2nd generation carotid stents)^{57,63} in relation to single-layered (1st generation) carotid stents and in relation to surgery indicates that the mesh-covered stents design differences are relevant clinically^{37,58}. The body of prospective evidence is also growing. A recent randomised controlled trial established a profound reduction in peri- and post-procedural DW-MRI embolism, an index of stroke risk, with micronet-covered stents versus conventional first-generation carotid stents⁴⁹. This provides level-1 evidence in support of neuroprotected, minimally-invasive sealing of lesions with increased stroke risk, translating into a new carotid revascularisation paradigm^{8,36,49,64}. In addition, the plaque sealing strategy, paired with

optimised intraprocedural neuroprotection⁶⁰ may allow to expand routine percutaneous management to lesions traditionally considered high-risk for CAS, such as highly-calcific⁶⁵ or highly-thrombotic^{60,67}.

Obtaining Evidence that is Feasible – and Understanding what Evidence is Unlikely

Practicing evidence-based medicine requires integrating individual clinical expertise and the best available external evidence. There will not be a randomised controlled trial (RCT) for every treatment in every clinical scenario¹³. The basis for an RCT is the principle of uncertainty – lack of evidence that one treatment type may be better than the other. One fundamental limitation of many RCTs with clinical endpoints today is, apart from large costs and several years required to enrol the high patient numbers needed, that they test treatments that have already obtained evidence –often convincing– from prior imaging studies and from increased risk patient cohorts enrolled in registries. Specifically, the RCT null hypothesis may no longer be relevant if there have been previous studies showing that a particular treatment has benefits^{14,68}. Another fundamental basis of RCTs is ethics of patient enrolment that requires avoiding subjecting patients to harm. For this reason, patients with an increased risk of a clinical event if left untreated (eg., a thrombus-containing carotid lesion) typically get treated outside of any RCT⁶⁹, because physicians exercising the ‘do no harm’ principle chose the treatment path (that is usually the preference of the patient and family too). As a result, the RCT ends up primarily enrolling low-risk patients. Such a RCT is ethical, but it is a priori unable to test the effect of the treatment it is supposed to test, and results in outcomes being generalized to the detriment of vulnerable higher risk populations¹⁴.

Primary stroke prevention by ACAS revascularisation using either CAS or CEA is the focus of the ongoing Carotid Revascularization and Medical Management for Asymptomatic Carotid Stenosis (CREST-2) trial (NCT02089217). It is important to realize that the success of the CREST-2 study in demonstrating the benefit of revascularisation (using either CAS or CEA) will be critically dependent on randomising (and maintaining) ACAS patients with increased-stroke-risk in the medical-only therapy arm. This is a major challenge as patients with increased-risk (and their treating

physicians) naturally gravitate towards the intervention that is to be tested in the study. This is evidenced in several recent falsely “neutral” trials in cardiovascular medicine; for example, performing coronary thrombus aspiration, if required, outside the trial – and randomising the remaining patients who are unlikely to require the tested intervention. This is the main reason why, for instance, the Stent-Protected Angioplasty versus Carotid Endarterectomy-2 (SPACE-2) trial which aimed at comparing medical therapy-only vs. medical therapy + CAS/CEA in ACAS, failed to complete enrolment⁶⁹. To provide clinically-relevant answers, carotid revascularisation RCTs studies should strive to include a preponderance of high-stroke-risk rather than being largely limited to low-risk patients. Guideline requirements for level 1 evidence should consider in detail RCT patient selection bias which will affect, a priori, the “answer” the trial aims to provide.

In real-life clinical practice, almost no patient is an “average” patient (it is as rare as the tip of the Gaussian distribution). It is fundamental to understand individual variations in disease pathology and the risk of symptom occurrence¹⁴. Safe and more efficacious treatments, including both pharmacotherapy and devices need to be considered on a patient-specific basis - to precisely target and modify the individual disease-related risks^{14,48}.

Conclusions

Strokes, including those of a mechanistic origin from carotid atherosclerosis, should be prevented rather than experienced. Contemporary optimised (“maximal”) pharmacotherapy, the first-line therapeutic approach for ACAS, paired with lifestyle modification, may reduce (or delay) stroke risk. Pharmacotherapy, however, even if maximised, does not sufficiently protect against carotid stenosis-related strokes^{21,23,33,35,36,44} (Fig 1). MMT patients continue to join the symptomatic cohorts of contemporary carotid revascularization trials^{8,36}. These patients have already experienced symptomatic loss of their brain tissue, demonstrating a failure of the “wait-and-see” strategy in ACAS (cf. Fig 1-II).

Revascularization, in addition to MMT, ideally should have been offered to these patients prior to the point where they become disabled (Fig 1). Treatment should be preventive rather than

reactive and should be safe and effective, including the long term^{56,65}. Recent evidence indicates that less than 20 unselected patients with a significant carotid stenosis need to be revascularized (NNT) to prevent 1 stroke⁷¹. NNT is likely to be significantly lower in patients with increased lesion-level and/or clinical risk features^{14,7,22,31,33-36,41}. That said, cardinal principle for any preventive therapy (including carotid revascularization to reduce stroke risk) is that the benefit must outweigh the risk¹⁴.

There is ample current level-1 evidence that percutaneous (e.g. transfemoral or transradial) conventional carotid revascularisation using conventional CAS using 1st generation (single-layered stent) is as safe and effective as conventional surgery. Less invasive surgery, using transcervical approach with robust, transient flow reversal to protect the brain, is an attractive therapeutic option to surgeons who wish to avoid traversing the aortic arch^{59,60}. If paired with a plaque-sealing stent⁶⁰, both percutaneous and TCR approaches may prove superior to conventional CEA or conventional CAS using 1st generation stents⁵⁷. The risk posed by the intervention, even if small, should always be weighed against the stroke risk in the absence of intervention. The risk analysis should take into account clinical, physiological, imaging (cerebral and other) lesion and individual patient co-morbid characteristics¹⁴.

Stroke risk stratification in ACAS remains a major challenge as clinically applicable scales (such as those available to guide therapeutic decision-making to reduce stroke risk in paroxysmal AFib^{34,39}) do not yet exist for ACAS and are sorely needed. Evidence is accumulating that the novel paradigm of percutaneous, appropriately neuroprotected, minimally invasive plaque sealing may demonstrate short- and long-term superiority over other management options.

Progress in medical knowledge must not be neglected. Consistent with the principle of evidence-based medicine, it is the duty of the clinician to apply the best contemporary evidence available rather than passively wait for “further” evidence – which may or may not arrive^{5,14,30}. Decision-making that, in contemporary clinical practice, integrates ACAS patient- and lesion-characteristics continues to be evidence-based¹⁴. Patients in at-risk populations deserve comprehensive information in reaching treatment decisions about therapies designed to prevent stroke. Patients in at

risk categories deserve comprehensive information to assist in treatment decisions regarding therapies designed to prevent stroke. Patient preference typically and overwhelmingly is to receive preventive treatment for stroke which is effective in both short- and long -term and delivered with a low procedural risk and with least invasiveness^{8,36,72}. ACAS patients with an asymptomatic carotid artery stenosis of 60–99% and increased risk of stroke should be considered for revascularization⁷⁰.

Patients at increased stroke risk should receive MMT and be offered the opportunity of modern low-risk interventions (minimal periprocedural complication rate, long-term durability) to prevent carotid stenosis-associated strokes. The “wait-for-stroke-to-occur” strategy (*ie.*, revascularise only once the patient becomes symptomatic) becomes unacceptable when the risk of percutaneous ‘fix it’ intervention is down to the level of about 1%^{36,37,57} compared to the annual stroke risk of up to 2.5% in vascular clinic ACAS patients on optimised pharmacotherapy^{8,21,23}. Clinical decision-making in ACAS patients needs to be based on facts (Fig 1, Fig 2) and not on wishful thinking⁷³.

Acknowledgements: Supported by a research grant from the Jagiellonian University Medical College (K/ZDS/007819), Polish Cardiac Society/Servier Clinical Research in Atherosclerosis Grant, and Polish Cardiac Society/ADAMED Basic Research in Atherosclerosis Grant (to PM).

Conflicts of interest:

PM is a recipient of research grants for basic and clinical investigations in atherosclerosis, and he has proctored and/or consulted for Abbott Vascular, InspireMD, and Medtronic. PM has been performing clinical trials of novel minimally invasive methods in carotid revascularization in primary and secondary stroke prevention including CARENET (Co-Principal Investigator), PARADIGM/PARADIGM-Extend (Principal Investigator), OPTIMA (Principal Investigator), TOP-Guard (Principal Investigator), and he is Global Co- Principal Investigator in FDA IDE CGUARDIANS Trial. PM is the Polish Cardiac Society Board Representative for Stroke and Vascular Interventions.

KR reports receiving fees for serving on advisory boards from Abbott Vascular, Cardinal Health, Surmodics, Inari Medical, Volcano/Philips, and Proteon; receiving fees and stock options for serving on advisory boards from Cruzar Systems, Valcare, and Eximo; receiving stock options for serving on advisory boards from Capture Vascular, Shockwave, Micell, Endospan, and Silk Road Vascular; receiving stock options for serving on the advisory boards of and the holding of equity positions in

Contego, Access Vascular, and MD Insider; holding stock/stock options in Embolitech, Janacare, Primacea, and PQ Bypass; receipt of a future payout from a previous equity position in Vortex; and receiving grant support paid to his institution from Abbott Vascular, Atrium/Maquet, and Lutonix/Bard. Dr. Stone reports receiving consulting fees from GlaxoSmithKline, lecture fees from Alnylam Pharmaceuticals, and fees for providing expert testimony from USP Labs.

AHS has consulted for Amnis Therapeutics Ltd, Cerebrotech Medical, Systems Inc, CereVasc LLC, Claret Medical Inc, Codman, Corindus Inc, GuidePoint Global Consulting, Medtronic (Formerly Covidien), MicroVention, Neuravi, Penumbra, Pulsar Vascular, Rapid Medical, Rebound Therapeutics Corporation, Silk Road Medical, Stryker, The Stroke Project Inc, Three Rivers Medical Inc, W.L. Gore & Associates, and is a Board Member of Intersocietal Accreditation Commission. He has been Principal Investigator and/or served on Steering Committees for: Codman & Shurtleff, LARGE Trial, Covidien (Now Medtronic), SWIFT PRIME and SWIFT DIRECT Trials; MicroVention, FRED Trial, CONFIDENCE Study, MUSC, POSITIVE Trial; Penumbra, 3D Separator Trial, COMPASS Trial, INVEST Trial. AHS has financial interests in BuffaloTechnology Partners Inc, Cardinal, International Medical Distribution Partners, Medina Medical Systems, Neuro Technology Investors, StimMed, and Valor Medical.

IQG is vice-President of the World Federation for Interventional Stroke Treatment (WIST).

References

1. Pearson J, Sipido KR, Musialek P, van Gilst WH. The Cardiovascular Research community calls for action to address the growing burden of cardiovascular disease. *Cardiovasc Res.* 2019;115(10):e96-e98.
2. Mozaffarian D, Benjamin EJ, Go AS, et al. Heart Disease and Stroke Statistics – 2016 Update: A report From the American Heart Association. *Circulation.* 2016;133(4):e38-60.
3. Adamson J, Beswick A, Ebrahim S. Is stroke the most common cause of disability? *J Stroke Cerebrovasc Dis.* 2004;13(4):171-7.
4. Sturm JW, Donnan GA, Dewey HM. Quality of Life After Stroke: The North East Melbourne Stroke Incidence Study (NEMESIS). *Stroke* 2004;35(10):2340-2345.
5. Musialek P, Grunwald IQ. How asymptomatic is “asymptomatic” carotid stenosis? Resolving fundamental confusion(s)—and confusions yet to be resolved. *Pol Arch Intern Med.* 2017;127(11):718–719.
6. Hackam DG, Kapral MK, Wang JT, et al. Most stroke patients do not get a warning: A population-based cohort study. *Neurology.* 2009;73(13):1074-6.

7. Paraskevas KI, Eckstein HH, Mikhailidis DP, Veith FJ, Spence JD. Rationale for screening selected patients for asymptomatic carotid artery stenosis. *Curr Med Res Opin.* 2020;36(3):361-365.
8. Musialek P, Hopf-Jensen S. Carotid Artery Revascularization for Stroke Prevention: A New Era. *J Endovasc Ther.* 2017;24(1):138-148.
9. Wafa HA, Wolfe CDA, Emmett E, Roth GA, Johnson CO, Wang Y. Burden of Stroke in Europe: Thirty-Year Projections of Incidence, Prevalence, Deaths, and Disability-Adjusted Life Years. *Stroke.* 2020;51(8):2418-2427.
10. Spagnoli LG, Mauriello A, Sangiorgi G, Fratoni S, Bonanno E, Schwartz RS, Piepgras DG, Raimondo Pistolese R, Ippoliti A, Holmes Jr DR. Extracranial thrombotically active carotid plaque as a risk factor for ischemic stroke. *JAMA.* 2004;292(15):1845-52.
11. Sakakura K, Nakano M, Otsuka F, et al. Pathophysiology of atherosclerosis plaque progression. *Heart Lung Circ.* 2013;22(6):399-411.
12. Powers WJ, Rabinstein AA, Ackerson T, Adeoye OM, Bambakidis NC, Becker K, Biller J, Brown M, Demaerschalk BM, Hoh B, Jauch EC, Kidwell CS, Leslie-Mazwi TM, Ovbiagele B, Scott PA, Sheth KN, Southerland AM, Summers DV, Tirschwell DL. 2019 Update to the 2018 Guidelines for the Early Management of Acute Ischemic Stroke: *Stroke.* 2019;50:e344-e418.
13. Rubiera M, Ribo M, Delgado-Mederos R, Santamarina E, Delgado P, Montaner J, Alvarez-Sabín J, Molina CA. Tandem internal carotid artery/middle cerebral artery occlusion: an independent predictor of poor outcome after systemic thrombolysis. *Stroke.* 2006;37(9):2301-5.
14. Podlasek A, Grunwald IQ, Musialek P. The evolution from an “average” study patient to patient-specific characteristics to guide interventions in vascular medicine. *Pol Arch Intern Med.* 2021;131(1):5–8.
15. Abbott AL, Bladin CF, Levi CR, Chambers BR. What should we do with asymptomatic carotid stenosis? *Int Journal of Stroke* 2007;2(1):27-39.
16. Abbott AL. Medical (nonsurgical) intervention alone is now best for prevention of stroke associated with asymptomatic severe carotid stenosis: Results of a systematic review and analysis. *Stroke.* 2009;40(10):e573-83.
17. Mizowaki T, Fujita A, Inoue S, Kuroda R, Urui S, Kurihara E, Hosoda K, Kohmura E. Outcome and effect of endovascular treatment in stroke associated with acute extracranial internal carotid artery occlusion: Single-center experience in Japan. *J Stroke Cerebrovasc Dis.* 2020;29(7):104824.
18. de Weerd M, Greving JP, de Jong AW, Buskens E, Bots ML. Prevalence of asymptomatic carotid artery stenosis according to age and sex: systematic review and metaregression analysis. *Stroke.* 2009;40(4):1105-13.

19. Petrova M, Kiat H, Gavino A, McLachlan CS. Carotid Ultrasound Screening Programs in Rural Communities: A Systematic Review. *J Pers Med*. 2021;11(9):897.
20. Porcu M, Mannelli L, Melis M, Suri JS, Gerosa Clara, Cerrone G, Defazio G, Faa G, Saba L. Carotid plaque imaging profiling in subjects with risk factors (diabetes and hypertension). *Cardiovasc Diagn Ther*. 2020;10(4):1005-1018.
21. Conrad MF, Boulom V, Mukhopadhyay S, Garg A, Patel VI, Cambria RP. Progression of asymptomatic carotid stenosis despite optimal medical therapy. *J Vasc Surg*. 2013;58(1):128-35.
22. Paraskevas KI, Nicolaidis AN, Kakkos S. Asymptomatic Carotid Stenosis and Risk of Stroke (ACSRS) study: what have we learned from it? *Ann Transl Med*. 2020;8(19):1271
23. Conrad MF, Michalczyk MJ, Opalacz A, Patel VI, LaMuraglia GM, Cambria RP. The natural history of asymptomatic severe carotid artery stenosis. *J Vasc Surg*. 2014;60(5):1218-1226
24. Vanassche T, Lauw MN, Eikelboom JW, et al. Risk of ischaemic stroke according to pattern of atrial fibrillation: analysis of 6563 aspirin-treated patients in ACTIVE-A and AVERROES. *Eur Heart J*. 2015;36(5):281-287.
25. Högberg D, Björck M, Mani K, Svensjö S, Wanhainen A. Five Year Outcomes in Men Screened for Carotid Artery Stenosis at 65 Years of Age: A Population Based Cohort Study. *Eur J Vasc Endovasc Surg*. 2019;57(6):759-766
26. Borissoff JI, Spronk HM, ten Cate H. The hemostatic system as a modulator of atherosclerosis. *N Engl J Med*. 2011;364(18):1746-60.
27. Zabczyk M, Natorka J, Undas A. Fibrin Clot Properties in Atherosclerotic Vascular Disease: From Pathophysiology to Clinical Outcomes. *J Clin Med*. 2021;10(13):2999.
28. Loeffen R, Spronk HM, ten Cate H. The impact of blood coagulability on atherosclerosis and cardiovascular disease. *J Thromb Haemost*. 2012;10(7):1207-16.
29. Khan AA, Patel J, Desikan S, Chrencik M, Martinez-Delcid J, Caraballo B, Yokemick J, Gray VL, Sorkin JD, Cebal J, Sikdar S, Lal BK. Asymptomatic carotid artery stenosis is associated with cerebral hypoperfusion. *J Vasc Surg*. 2021;73(5):1611-1621.
30. Grunwald IQ, Papanagiotou P, Reith W, et al. Influence of carotid artery stenting on cognitive function. *Neuroradiology*. 2010;52(1):61-6.
31. Gaba K, Bulbulia R. Identifying asymptomatic patients at high-risk for stroke. *J Cardiovasc Surg*. 2019;60(3):332-344.
32. Paraskevas KI, Mikhailidis DP, Veith FJ, Spence JD. Definition of Best Medical Treatment in Asymptomatic and Symptomatic Carotid Artery Stenosis. *Angiology*. 2016;67(5):411-9.
33. Paraskevas KI, Mikhailidis DP, Baradaran H, Davies AH, Eckstein HH, Faggioli G, Fernandes JFE, Gupta A, Jezovnik MK, Kakkos SK, Katsiki N, Kooi ME, Lanza G, Liapis CD, Loftus IM, Millon A, Nicolaidis AN, Poredos P, Pini R, Ricco JB, Rundek T, Saba L, Spinelli F, Stilo F, Sultan S, Zeebregts CJ, Chaturvedi S. Optimal Management of

Asymptomatic Carotid Stenosis: Counterbalancing the Benefits with the Potential Risks. *J Stroke*. 2022;24(1):163-165.

34. Ding WY, Rivera-Caravaca JM, Marin F, Torp-Pedersen C, Roldán V, Lip GYH. Prediction of Residual Stroke Risk in Anticoagulated Patients with Atrial Fibrillation: mCARS. *J Clin Med*. 2021; 10: 335.
35. Paraskevas KI, Veith FJ, Ricco JB. Best medical treatment alone may not be adequate for all patients with asymptomatic carotid artery stenosis. *J Vasc Surg*. 2018;68(2):572-575.
36. Musialek P, Mazurek A, Trystula M, et al. Novel PARADIGM in carotid revascularisation: Prospective evaluation of All-comer percutaneous carotid revascularisation in symptomatic and Increased-risk asymptomatic carotid artery stenosis using CGuard MicroNet-covered embolic prevention stent system. *EuroIntervention*. 2016;12(5):e658-70.
37. Stabile E, de Donato G, Musialek P, et al. Use of dual-layered stents for carotid artery angioplasty: 1-year results of a patient-based meta-analysis. *J Am Coll Cardiol Interv*. 2020;13(14):1709–1715.
38. Aboyans V, Ricco JB, Bartelink MEL, Björck M, Brodmann M, Cohnert T, Collet JP, Czerny M, De Carlo M, Debus S, Espinola-Klein C, Kahan T, Kownator S, Mazzolai L, Naylor AR, Roffi M, Röther J, Sprynger M, Tendera M, Tepe G, Venermo M, Vlachopoulos C, Desormais I. 2017 ESC Guidelines on the Diagnosis and Treatment of Peripheral Arterial Diseases, in collaboration with the European Society for Vascular Surgery (ESVS): Document covering atherosclerotic disease of extracranial carotid and vertebral, mesenteric, renal, upper and lower extremity arteries. Endorsed by the European Stroke Organization (ESO) and the European Society for Vascular Surgery (ESVS). *Eur Heart J*. 2018;39(9):763-816.
39. Ding WY, Rivera-Caravaca JM, Marín F, Li G, Roldán V, Lip GYH. Number needed to treat for net effect of anticoagulation in atrial fibrillation: Real-world vs. clinical-trial evidence. *Br J Clin Pharmacol*. 2022;88(1):282-289.
40. Brott TG, Halperin JL, Abbara S, Bacharach JM, Barr JD, Bush RL, Cates CU, Creager MA, Fowler SB, Friday G, Hertzberg VS, McIff EB, Moore WS, Panagos PD, Riles TS, Rosenwasser RH, Taylor AJ, Jacobs AK, Smith SC Jr, Anderson JL, Adams CD, Albert N, Buller CE, Creager MA, Ettinger SM, Guyton RA, Halperin JL, Hochman JS, Hunt SA, Krumholz HM, Kushner FG, Lytle BW, Nishimura RA, Ohman EM, Page RL, Riegel B, Stevenson WG, Tarkington LG, Yancy CW.
ASA/ACCF/AHA/AANN/AANS/ACR/ASNR/CNS/SAIP/SCAI/SIR/SNIS/SVM/SVS guideline on the management of patients with extracranial carotid and vertebral artery disease. *Catheter Cardiovasc Interv*. 2013;81(1):E76-123.
41. Kamtchum-Tatuene J, Noubiap JJ, et al. Prevalence of high-risk plaques and risk of stroke

in patients with asymptomatic carotid stenosis: A meta-analysis. *JAMA Neurol.* 2020;77(12):1524–1535.

42. Nakagawa I, Kotsugi M, Park HS, et al. Nearinfrared spectroscopy carotid plaque characteristics and cerebral embolism in carotid artery stenting using first-generation stent. *EuroIntervention.* 2021;17(7):599–606.
43. Musialek P, Dabrowski W, Mazurek A, et al. Quantitative virtual histology for in vivo evaluation of human atherosclerosis—a plaque biomechanics-based novel image analysis algorithm: Validation and applications to atherosclerosis research. In: Balocco S, ed. *Intravascular Ultrasound: From Acquisition to Advanced Quantitative Analysis.* New York: Elsevier; 2020:71–96.
44. Liapis CD, Eckstein HH, Paraskevas KI, Cronenwett JL. Emerging evidence suggests that patients with high-grade asymptomatic carotid stenosis should be revascularized. *J Vasc Surg.* 2022;75(1S):23S-25S.
45. Hosseini AA, Simpson RJ, Altaf N, et al. Magnetic Resonance Imaging Plaque Hemorrhage for Risk Stratification in Carotid Artery Disease With Moderate Risk Under Current Medical Therapy. *Stroke* 2017;48(3):678-685.
46. Högberg D, Mani K, Wanhainen A, Svensjö S. Clinical Effect and Cost-Effectiveness of Screening for Asymptomatic Carotid Stenosis: A Markov Model. *Eur J Vasc Endovasc Surg.* 2018;55(6):819-827.
47. Musialek P, Tracz W, Tekieli L, et al. Multimarker approach in discriminating patients with symptomatic and asymptomatic atherosclerotic carotid artery stenosis. *J Clin Neurol.* 2013;9(3):165-75.
48. Musialek P, Roubin GS. Double-Layer Carotid Stents: From the Clinical Need, through a Stent-in-Stent Strategy, to Effective Plaque Isolation... the Journey Toward Safe Carotid Revascularization Using the Endovascular Route. *J Endovasc Ther.* 2019;26(4):572-577.
49. Karpenko A, Bugurov S, Ignatenko P, et al. Randomized Controlled Trial of Conventional Versus MicroNet-Covered Stent in Carotid Artery Revascularization. *JACC Cardiovasc Interv.* 2021;14(21):2377-2387.
50. Musialek P, Hopkins LN, Siddiqui AH. One swallow does not a summer make but many swallows do: accumulating clinical evidence for nearly-eliminated peri-procedural and 30-day complications with mesh-covered stents transforms the carotid revascularisation field. *Adv Interv Cardiol.* 2017;13(2):95-106.
51. Kotsugi M, Takayama K, Myouchin K, Wada T, Nakagawa I, Nakagawa H, Taoka T, Kurokawa S, Nakase H, Kichikawa K. Carotid Artery Stenting: Investigation of Plaque Protrusion Incidence and Prognosis. *JACC Cardiovasc Interv.* 2017;10(8):824-831.
52. Sardar P, Chatterjee S, Aronow HD, et al. Carotid artery stenting versus endarterectomy for

stroke prevention: a meta-analysis of clinical trials. *J Am Coll Cardiol*. 2017;69(18):2266–2275.

53. Rosenfield K, Matsumura JS, Chaturvedi S, et al. (ACT-1 Investigators). Randomized Trial of Stent versus Surgery for Asymptomatic Carotid Stenosis. *N Engl J Med*. 2016;374(11):1011–20.
54. Halliday A, Harrison M, Hayter E, Kong X, Mansfield A, Marro J, Pan H, Peto R, Potter J, Rahimi K, Rau A, Robertson S, Streifler J, Thomas D. 10-year stroke prevention after successful carotid endarterectomy for asymptomatic stenosis (ACST-1): a multicentre randomised trial. *Lancet*. 2010;376(9746):1074–84.
55. Halliday A, Bulbulia R, Bonati LH, et al. Second asymptomatic carotid surgery trial (ACST-2): A randomised comparison of carotid artery stenting versus carotid endarterectomy. *Lancet*. 2021;398(10305):1065–1073.
56. Brott TG, Calvet D, Howard G, et al. Long-term outcomes of stenting and endarterectomy for symptomatic carotid stenosis: A preplanned pooled analysis of individual patient data. *Lancet Neurol*. 2019;18(4):348–356.
57. Mazurek A, Malinowski K, Setacci F, et al. Carotid Artery Revascularization Using Second-Generation Stents Versus Surgery: A Meta-Analysis of Clinical Outcomes. Abstract. *J Am Coll Cardiol* 2021;78(19Suppl B):188.
58. Machalińska A, Kowalska-Budek A, Kawa MP, Kazimierczak A, Safranow K, Kirkiewicz M, Rynio P, Wilk G, Lubiński W, Gutowski P, Machaliński B. Effect of carotid endarterectomy on retinal function in asymptomatic patients with hemodynamically significant carotid artery stenosis. *Pol Arch Intern Med*. 2017;127(11):722–729.
59. Galyfos GC, Tsoutsas I, Konstantopoulos T, et al. Early and late outcomes after transcrotid revascularisation for internal carotid artery stenosis: A systematic review and meta-analysis. *Eur J Vasc Endovasc Surg*. 2021;61(5):725–738.
60. Trystuła M, Musialek P. Transient flow reversal combined with sustained embolic prevention in transcervical revascularization of symptomatic and highly-emboligenic carotid stenoses for optimized endovascular lumen reconstruction and improved peri- and post-procedural outcomes. *Adv Interv Cardiol*. 2020;16(4):495–506.
61. Sharma M, Hart RG, Connolly SJ, et al. Stroke Outcomes in the COMPASS Trial. *Circulation*. 2019;139(9):1134–1145.
62. Schwartz GS, Szarek M, Bittner VA, et al. Lipoprotein(a) and Benefit of PCSK9 Inhibition in Patients With Nominally Controlled LDL Cholesterol. *J Am Coll Cardiol*. 2021;78(5):421–433.

63. Siudut J, Zabczyk M, Wolkow P, Polak M, Undas A, Jawien J. Intensive low-density lipoprotein cholesterol lowering improves fibrin clot properties: Association with lipoproteins and C-reactive protein. *Vascul Pharmacol*. 2022 (online ahead of print)
64. Paszek E, Pociask E, Zabczyk M, Piorkowski A, Butenas S, Legutko J, Undas A. Active factor XI is associated with the risk of cardiovascular events in stable coronary artery disease patients. *Atherosclerosis*. 2022 (online ahead of print).
65. Mazurek A, Borratynska A, Malinowski KP, et al. MicroNET-covered stents for embolic prevention in patients undergoing carotid revascularisation: Twelve-month outcomes from the PARADIGM study. *EuroIntervention*. 2020;16(11):E950–E952.
66. Mazurek A, Partyka L, Trystula M, et al. Highly-calcific carotid lesions endovascular management in symptomatic and increased-stroke-risk asymptomatic patients using the CGuard™ dual-layer carotid stent system: Analysis from the PARADIGM study. *Catheter Cardiovasc Interv*. 2019;94(1):149-156.
67. Tekieli L, Banaszkiwicz K, Moczulski Z, Urbańczyk M, Musialek P. Novel Large-Diameter Controlled-Expansion Stentriever, Embolic-Prevention Stent and Flow Reversal in Large-Thrombus-Burden ICA Proximal Occlusion Stroke. *JACC Cardiovasc Interv*. 2021;14(21):e287-e291.
68. Musialek P. TASTE-less endpoint of 30-day mortality (and some other issues with TASTE) in evaluating the effectiveness of thrombus aspiration in STEMI: not the "evidence" to change the current practice of routine consideration of manual thrombus extraction. *Pol Heart J*. 2014;72(6):479-87.
69. Eckstein HH, Reiff T, Ringleb P, Jansen O, Mansmann U, Hacke W. SPACE-2: A Missed Opportunity to Compare Carotid Endarterectomy, Carotid Stenting, and Best Medical Treatment in Patients with Asymptomatic Carotid Stenoses. *Eur J Vasc Endovasc Surg*. 2016;51(6):761-5.
70. Gaba K, Ringleb PA, Halliday A. Asymptomatic Carotid Stenosis: Intervention or Best Medical Therapy? *Curr Neurol Neurosci Rep*. 2018;18(11):80.
71. Aro E, Ijäs P, Vikatmaa L, Soinnie L, Sund R, Venermo M, Vikatmaa P. The Efficacy of Carotid Surgery by Subgroups: The Concept of Stroke Prevention Potential. *Eur J Vasc Endovasc Surg*. 2019;58(1):5-12.
72. Trystula M, Tomaszewski T, Pachalska M. Health-related quality of life in ischaemic stroke survivors after carotid endarterectomy (CEA) and carotid artery stenting (CAS): Confounder-controlled analysis. *Adv Interv Cardiol*. 2019;15(2):226-233.
73. Högberg D, Björck M. Response to "Re. Five Year Outcomes in Men Screened for Carotid Artery Stenosis at 65 Years of Age: A Population Based Cohort Study". *Eur J Vasc Endovasc Surg*. 2020;59(1):152.

Fig 1. Scenarios of acute ischaemic stroke due to athero-thrombotic carotid stenosis (January 2022)

This figure presents 3 types of ischemic stroke, mechanistically related to athero-thrombotic carotid stenosis:

Panel I exemplifies acute ischemic stroke due to (sub-)occlusion of the carotid artery (extracranial segment) with a large thrombus originating from the atherosclerotic lesion. Panel II shows a tight stenosis as an underlying mechanism. Panel III demonstrates a “tandem” lesion stroke with migration of part of the internal carotid origin thrombus (stenosis progression to thrombotic occlusion) into the intracranial vasculature.

Examples are taken from consecutive patients with acute ischemic stroke due to carotid stenosis, all presenting in January 2022. The strokes in patients I-III presented without any prior warning symptom(s), consistent with $\approx 80\%$ of stroke presentations⁶.

The imaging timeline is from top to bottom. Cerebral images are in the axial view, except III-D2 that is a coronal presentation. All carotid images are in the coronal view. In patient I and II the left hemisphere is dominant, in patient III – the right hemisphere.

Stenosis severity was 74% (by lumen area)/56% (diameter stenosis) in patient I, 87% (by lumen area)/64% (diameter stenosis) in patient II and 78% (by lumen area)/61% (diameter stenosis) in patient III.

Yellow stars (I-A, III-B1) in patient I and III indicate early cerebral ischemia on cerebral computed tomography at the time of presentation. In patient II, diffusion-weighted magnetic resonance imaging on admission (II-A1/A2) showed diffusion restriction (hyperintense areas) in the left hemisphere.

The lesions were also visible on fluid-attenuated inversion recovery imaging, consistent with established cerebral damage. Patient I and III received intravenous thrombolytic therapy (IVT) which, in both cases, was clinically ineffective, consistent with reported recanalization rates of $<10\%$ in carotid occlusion strokes. Patient II presented beyond the 4.5h time window for thrombolysis.

Yellow arrows depict the culprit (carotid) lesion (I-B1/B2, II-B1/B2, III-B2). Red arrowheads (all B images and III-C) indicate thrombus. Images in C show the CT-angiography at the time of presentation. All three patients still show presence of intracranial collaterals; those, however, are rarely able to sustainably compensate an abrupt carotid artery occlusion.

Red arrows (D) show the infarcted area at discharge. White arrows (III-D1/D2) depict haemorrhagic transformation that occurred in patient III.

Clinical outcomes are provided at the bottom of the figure. A modified Rankin score (mRS) of 2 indicates slight disability (patient able to look after their own affairs without assistance, but unable to carry out all previous activities); mRS 3 signifies moderate disability (patient requires some help, but is able to walk unassisted); mRS 4 represents moderately severe disability (patient unable to attend to own bodily needs without assistance, and unable to walk unassisted). The National Institutes of Health Stroke Scale (NIHSS) represents a clinical stroke severity scale (≤ 6 minor stroke; > 6 major stroke).

Extracranial thrombotically active carotid plaque is a major, mechanistic risk factor for ischaemic stroke¹⁰. Strokes in Patient I and patient III were likely preventable with low-risk revascularization^{36,37} on top of MMT. Note that the presence of PAD or CAD increase the risk of CS while diabetes (patient I) is an important risk factor for stroke in CS. Patient III was not revascularised due to a widespread belief (despite lack of data) in a sufficient MMT protection against CS-related stroke (see text for references).

After the stroke, patients I and III were no longer suitable for carotid revascularisation due to major loss of cerebral tissue with a mRS >2 , resulting in a high risk-to-benefit ratio for intervention. Patient II subsequently underwent uncomplicated endovascular revascularisation of the culprit lesion 12 days after the event; this did not resolve his pronounced aphasia and stroke-related neurological deficits but would reduce the risk of another stroke.

CS – carotid artery stenosis, PAD – peripheral arterial disease, CAD – coronary artery disease, MMT – maximal medical therapy³², NSTEMI – non ST-elevation myocardial infarction, RICA – right internal carotid artery, LICA – left internal carotid artery, RECA – right external carotid artery, LECA – left external carotid artery, RMCA – right middle cerebral artery, Occl – occlusion. Red arrowheads indicate thrombus.

Fig 2. The "Roulette wheel" of contemporary stroke risk management in carotid stenosis.

The stroke risk level in subjects with clinically asymptomatic atherosclerotic carotid artery stenosis (ACAS) is represented on the top axis; the bottom axis represents measures that counteract the stroke risk level. Ideally, a higher risk level should be matched with a greater magnitude of preventive measures.

Clinical data show that, in previously asymptomatic lesions, cumulating risk factors increase the likelihood for a stroke. This is indicated by a risk gradient (blue triangle). Today, in contrast to

CHA₂DS₂-VASC and other clinically applicable risk stratification scales in atrial fibrillation (AFib), no validated risk quantification tools exist for ACAS subjects. The prevalence of ACAS is similar to that of paroxysmal AFib; the annual stroke risk in ACAS patients on optimised medical therapy (OMT) is similar to that seen in paroxysmal AFib patients on aspirin (≈ 2.0 - 2.5% in ACAS vs. $\approx 2.1\%$ in AFib).

The stars within the blue triangle of the risk gradient symbolise the random distribution (and, not infrequently, random understanding and use) of characteristics known to increase stroke risk in ACAS. Evidence from clinical studies shows that these features (such as contralateral transient ischaemic attack or stroke, ipsilateral silent cerebral infarction, stenosis progression, echolucent plaque, intraplaque haemorrhage or large necrotic core) may be differently weighted regarding their impact on stroke risk, hence the stars differ in size. Some have made it into ACAS patient management guidelines despite poor reproducibility and/or lack of robust data. For instance, today only $\approx 5\%$ of patients with a recent carotid stenosis-related stroke or TIA have spontaneous embolic signals on transcranial Doppler, questioning (beyond the technical and reproducibility problems) its role in asymptomatic risk stratification. Some other, more obvious, stroke risk factors such as carotid plaque surface irregularity/ulceration or thrombus-containing plaque did not make it to the guidelines, despite their evidenced role.

It is important to understand that even ACAS lesions that are believed to be low-risk can become symptomatic and cause stroke, albeit less frequently (note the patient-level stroke hit arrows on the top of the figure). For the patient and their family the occurrence of an actual stroke event is what matters, rather than continuous linear (or curvilinear) stroke “risk” considerations.

Today, there is ample evidence that the carotid plaque itself plays an important, mechanistic part in transforming a lesion from asymptomatic to symptomatic. Apart from the lesion phenotype (that may be dynamic), fundamental fields of the roulette turning wheel are lesion-level stroke factors (such as the ‘vulnerable’ plaque phenotype that may be specific to the imaging technique used) and ‘vulnerable blood’ mechanisms that impact plaque rupture and thrombosis. In addition, in some clinical conditions such as diabetes or thrombophilia, there is a marked increase in stroke risk that partly includes a mechanistic contribution from the carotid lesion. Blue arrows indicate interactions between risk features.

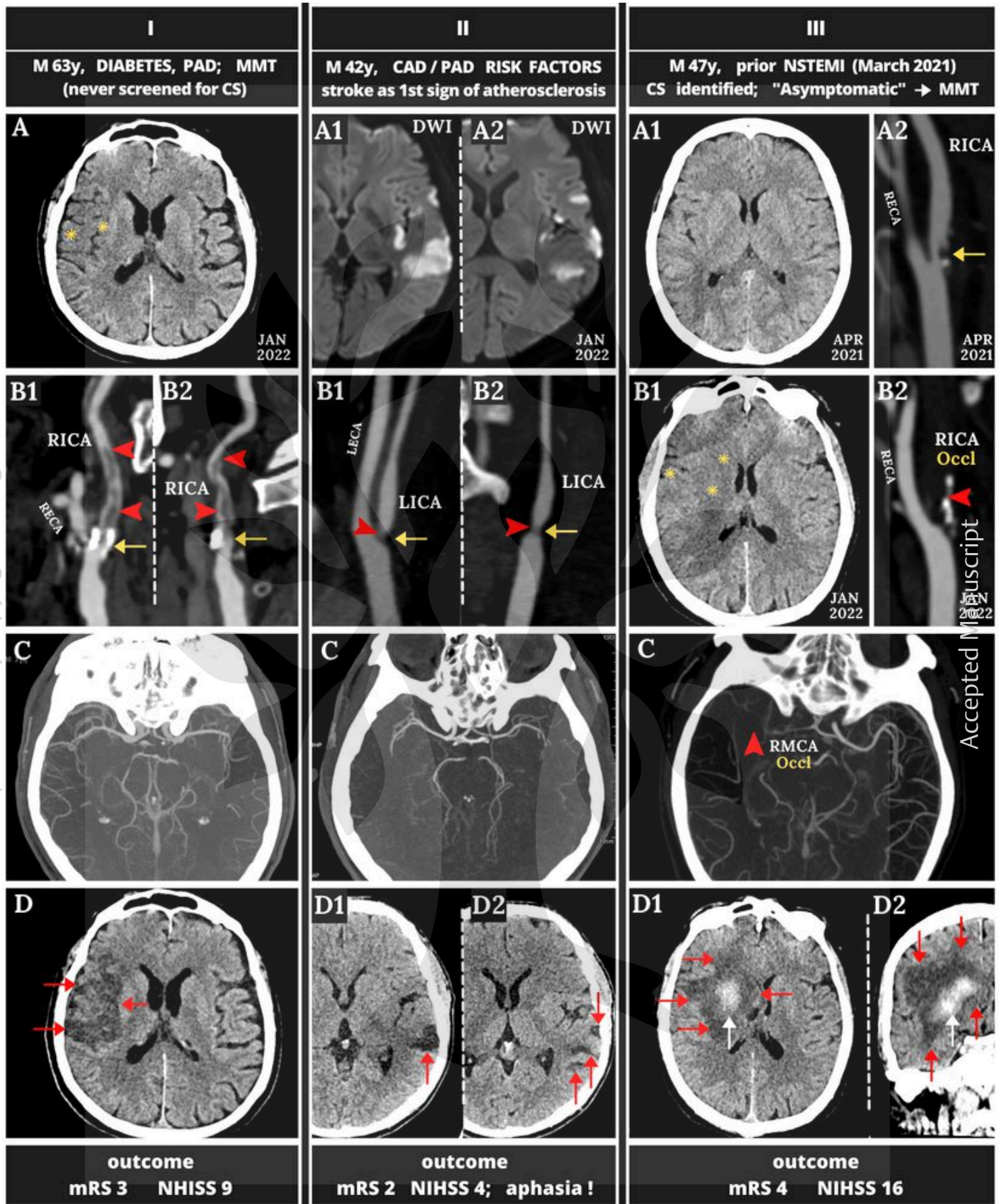
Combined analysis of data from two large, randomized trials (Asymptomatic Carotid Atherosclerosis Study and Asymptomatic Carotid Stenosis Trial-1) showed no effect of increasing lumen stenosis (beyond 60%) on stroke risk in ACAS. The 5-year stroke rate was 7.8% with 60-99% stenosis, 7.4% with 70-79% stenosis, and 5.1% with $\geq 80\%$ stenosis. Thus the severity of luminal stenosis is a poor

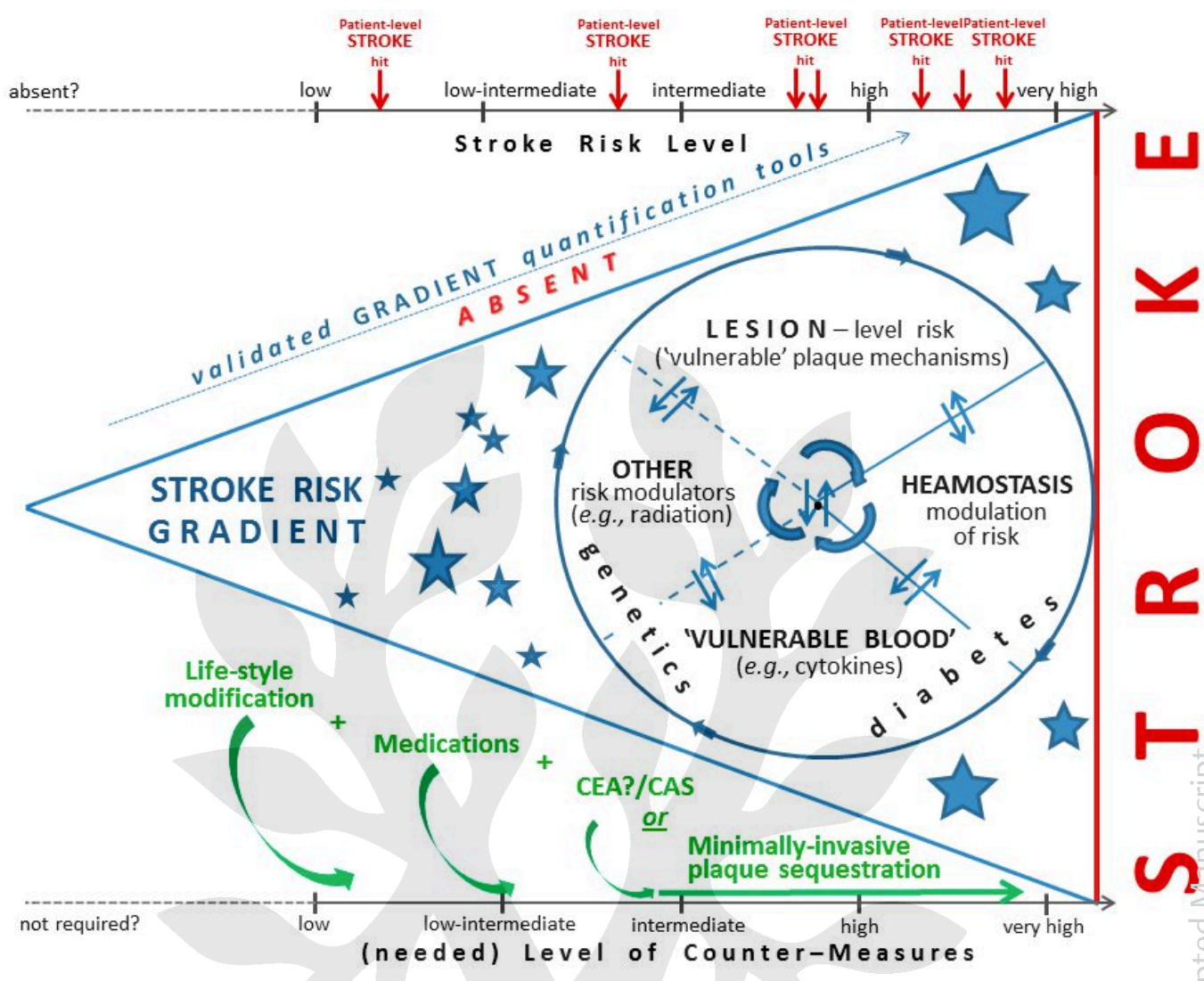
indicator for stroke risk in ACAS. Indeed, luminal stenosis is a poor index of the plaque burden and plaque morphology because of the varying vessel compensation for the plaque growth (remodelling). Despite the evidence contradicting the role of the degree of luminal stenosis for stratification of stroke risk in ACAS, it remains on the roulette wheel.

Although no carotid stenosis-specific data are yet available, the haemostatic system is known to critically modulate clinical event risks in atherosclerosis. Recent evidence from studies that have included ACAS patients indicates that haemostatic modulation may be an important target for pharmacotherapy with low-dose oral antithrombotic agents.

In contrast to the knowledge gaps in quantifying a stroke risk gradient in ACAS, there is significantly more knowledge on how to counteract risk of stroke. OMT, that may reduce or delay stroke risk (but does not universally abolish it), is the main pillar of treatment. OMT should include an antiplatelet agent, an angiotensin-converting enzyme inhibitor or angiotensin receptor inhibitor and a statin titrated to achieve guideline-recommended LDL cholesterol levels. Indirect evidence from recent low-dose oral antithrombotic agent and proprotein subtilisin/kexin type 9 (PCSK9) inhibitor trials suggests a role for these agents at least in some ACAS patients.

Two trials (Randomized Trial of Stent versus Surgery for Asymptomatic Carotid Stenosis, ACT-1, and Asymptomatic Carotid Stenosis Trial-2, ACST-2) indicated equipoise between surgery (carotid endarterectomy, CEA) and endovascular treatment using, exclusively or mostly, first-generation (single-layer) carotid stents in ACAS patients. Recent studies suggest that minimally invasive endovascular sealing of high risk plaque may be a safer and more effective treatment modality in carotid stenosis-related stroke prevention. Elimination of plaque, by surgery or sealing, will eliminate further lesional stroke risk (green cross). Patient preference typically points to less invasive management options. Data are accumulating that appropriately neuroprotected, minimally invasive plaque sequestration may prove superior to conventional surgery, both short- and long-term. See text for references.





This article is protected by copyright. All rights reserved.

Accepted Manuscript

This document was downloaded for personal use only. Unauthorized distribution is strictly prohibited.