

Case  
Report

# Reconstruction of the Bifurcation of Right Upper Bronchus Using Miyamoto's Technique for Typical Carcinoid

Ayaka Asakawa, Hironori Ishibashi, Kuniyo Sueyoshi, Erika Mori, Yasuhiro Nakashima, Masashi Kobayashi, and Kenichi Okubo

**A 41-year-old woman presented with productive cough and exertional dyspnea. Bronchoscopy revealed an endobronchial tumor arising from the membrane proximal to the bifurcation of right upper bronchus, and the tumor was a typical carcinoid. The right main bronchus, right upper lobe bronchus, and intermediate bronchus were resected along with the tumor. Intraoperative pathological diagnosis of the bronchial stumps was negative, and bronchial reconstruction was subsequently performed. Two-thirds of the circumference of the right main bronchus and the right intermediate bronchus were anastomosed. The right upper lobe bronchus was anastomosed in an end-to-side fashion. The anastomotic site was covered by the intercostal muscles.**

**Keywords:** typical carcinoid, bronchial reconstruction, Miyamoto's technique

## Introduction

In the surgery of bronchial tumors, bronchial excision and reconstruction should be considered to preserve the lung parenchyma, especially for low-malignant tumors. Reconstruction methods of carina have been reported before, but reports of reconstruction of bronchial bifurcation is rare. Herein, we report a novel technique of reconstruction of the bifurcation using Miyamoto's method.

*Department of Thoracic Surgery, Tokyo Medical and Dental University, Tokyo, Japan*

Received: May 16, 2022; Accepted: August 9, 2022

Corresponding author: Kenichi Okubo. Department of Thoracic Surgery, Tokyo Medical and Dental University, 1-5-45, Yushima, Bunkyo-ku, Tokyo 113-8510, Japan  
Email: okubo.thsr@tmd.ac.jp

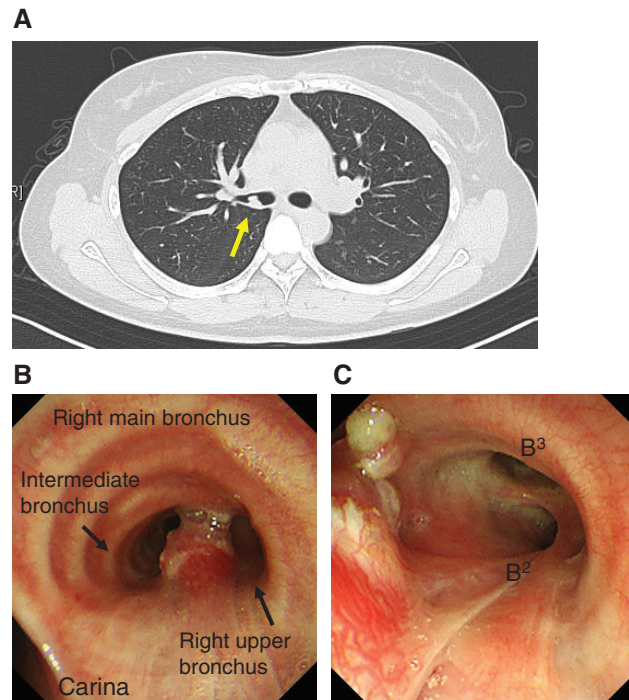


This work is licensed under a Creative Commons Attribution-NonCommercial-NoDerivatives International License.

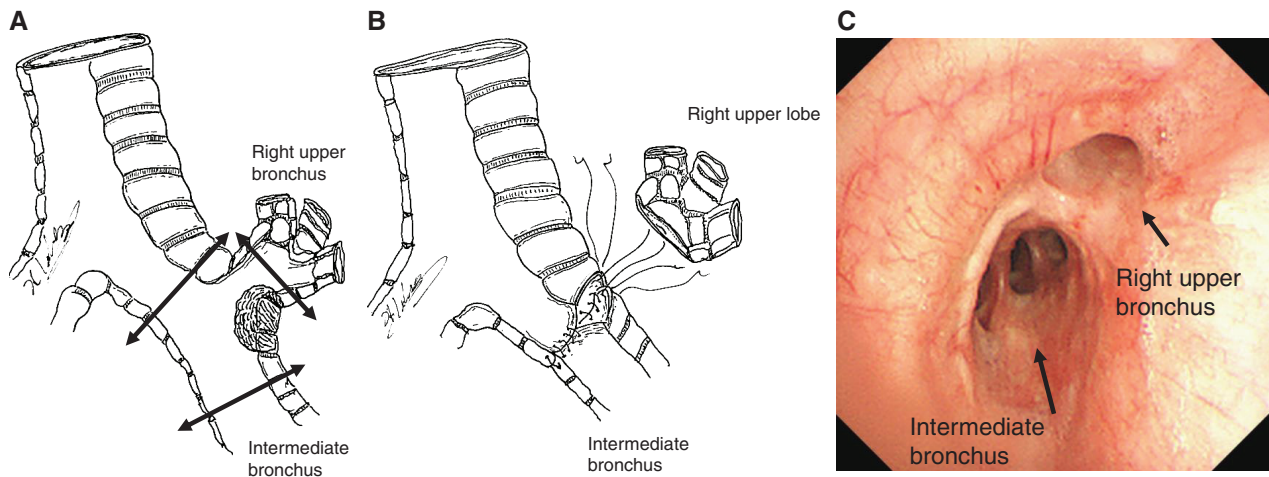
©2022 The Editorial Committee of *Annals of Thoracic and Cardiovascular Surgery*

## Case Report

A 41-year-old woman presented with productive cough and exertional dyspnea. Chest computed tomography showed a 10-mm endobronchial tumor arising from the right main bronchus and the bifurcation of right upper bronchus (**Fig. 1A**). Bronchoscopy revealed an endobronchial tumor arising from the membrane proximal to the bifurcation of right upper bronchus. The tumor was diagnosed as a typical carcinoid via biopsy (**Figs. 1B and 1C**). Surgical treatment was chosen due to the absence of lymph and systemic metastases. The patient underwent bronchial resection and reconstruction, with preservation of the lung parenchyma, due to the tumor's low malignant profile and location. A right posterolateral thoracotomy via the fourth intercostal space was done. The right main, intermediate, and right upper bronchi were transected to achieve a safe margin (**Fig. 2A**). The tumor was removed along the right bifurcation of right upper bronchus. The pulmonary ligament and pericardium underneath the hilum were incised as tension-reducing maneuvers. Frozen section biopsy revealed negative



**Fig. 1** (A) Chest computed tomography revealed a 10-mm endobronchial tumor arising from the right main bronchus and the bifurcation of right upper bronchus. (B and C) Bronchoscopy revealed an endobronchial tumor arising from the membrane proximal to the bifurcation of right upper bronchus.



**Fig. 2** Resection and reconstruction of the bronchus. (A) A sketch of the tumor and the resection line of the bronchus. (B) The bronchus was reconstructed using the Miyamoto's technique. (C) Postoperative bronchoscopy showed a patent right upper bronchus and intermediate bronchus.

margins in each bronchial stump. Thus, bronchial reconstruction was subsequently performed.

Two-thirds of the circumference of the right main bronchus and intermediate bronchus were anastomosed with interrupted sutures using 4-0 PDSII (Ethicon Inc.,

Johnson & Johnson Company, New Brunswick, NJ, USA). Next, the right upper lobe bronchus, one-third of the right main bronchus, and the intermediate bronchus were anastomosed in an end-to-side fashion without additional bronchial trimming (**Fig. 2B**). The anastomosis site

was covered with an intercostal muscle flap. The postoperative course was uneventful, and the patient was discharged on the fifth postoperative day. Bronchoscopy performed four months after the operation showed a new bifurcation without stenosis (**Fig. 2C**). Histopathological examination confirmed an endobronchial typical carcinoid with a free surgical margin. The patient showed no signs of recurrence after two years of follow-up.

## Discussion

Surgery is the initial choice of treatment for localizing bronchial carcinoids. Sparing of the pulmonary parenchyma should be considered due to the low malignant potential of typical bronchial carcinoids and the low incidence of associated pulmonary lymph node metastasis.<sup>1–3</sup> Pikin et al. reported 25 patients with endobronchial carcinoids, without metastasis, who underwent endoscopic resection and sequential bronchoplasty without resecting the pulmonary parenchyma. The patients had a good prognosis, with 100% overall 5-year survival, without severe complications.<sup>4</sup> Pulmonary parenchyma-sparing surgery is feasible in patients with typical bronchial carcinoids to preserve respiratory function and avoid excessive surgical stress.

Miyamoto's technique, firstly reported as the modified double-barrel method, is a principal technique used for carinal reconstruction to create "neocarina."<sup>5,6</sup> After the tracheal carina is resected, two-thirds of the circumference of the trachea and the left main bronchus are anastomosed. The remaining one-third of the circumference is trimmed to create an orifice to anastomose the right bronchus. This method disperses tension to the trachea and left main bronchus, avoiding bronchial ischemia. The Miyamoto's technique and montage-type reconstruction have this point in common.

There are several ways to reconstruct bronchial bifurcation. Wedge plasty, end-to-end plasty, and double barrel methods have been reported<sup>7–11</sup>; meanwhile, the Miyamoto's technique has not been reported before. We adopted the Miyamoto's technique in our case because the carina and right bronchial bifurcation were similar in shape.

## Conclusion

Reconstruction of bifurcation of right upper bronchus, using the Miyamoto's technique, was feasible for the surgical treatment of a low-risk bronchial malignancy.

## Acknowledgments

We would like to thank Editage (<http://www.editage.com>) for editing and reviewing this manuscript for English language.

## Disclosure Statement

None declared.

## References

- 1) Aydin E, Yazici U, Gulgosteren M, et al. Long-term outcomes and prognostic factors of patients with surgically treated pulmonary carcinoid: our institutional experience with 104 patients. *Eur J Cardiothorac Surg* 2011; **39**: 549–54.
- 2) Maurizi G, Ibrahim M, Andretti C, et al. Long-term results after resection of bronchial carcinoid tumor: evaluation of survival and prognostic factors. *Interact Cardiovasc Thorac Surg* 2014; **19**: 239–44.
- 3) Nowak K, Karenovics W, Nicholson AG, et al. Pure bronchoplastic resections of the bronchus without pulmonary resection for endobronchial carcinoid tumors. *Interact Cardiovasc Thorac Surg* 2013; **17**: 291–4; discussion, 294–5.
- 4) Pikin O, Ryabov A, Sokolov V, et al. Two-stage surgery without parenchyma resection for endobronchial carcinoid tumor. *Ann Thorac Surg* 2017; **104**: 1846–51.
- 5) Yamamoto K, Miyamoto Y, Ohsumi A, et al. Surgical results of carinal reconstruction: an alternative technique for tumors involving the tracheal carina. *Ann Thorac Surg* 2007; **84**: 216–20.
- 6) Yamamoto K, Miyamoto Y, Ohsumi A, et al. Results of surgical resection for tracheobronchial cancer involving the tracheal carina. *Gen Thorac Cardiovasc Surg* 2007; **55**: 231–9; discussion, 238–9.
- 7) Wang A, Chen X, Huang D, et al. Deeper wedge resection and parenchymalsparing bronchoplasty of the secondary carina: an alternative surgical technique for removal of tumor located at the orifice of upper lobar bronchus. *J Cardiothorac Surg* 2017; **12**: 51.
- 8) Zhang Z, Yuan F, Yin R, et al. Left upper lobectomy with bronchoplasty in uniportal video-assisted thoracic surgery for bronchial carcinoid. *J Vis Surg* 2016; **2**: 84.
- 9) Uramoto H, Nakajima Y, Kinoshita H. Left upper lobe double sleeve lobectomy with double barrel anastomosis for lung adenocarcinoma. *Ann Med Surg (Lond)* 2016; **9**: 12–4.
- 10) Tanaka K, Nakajima T, Morimoto J, et al. Right lower sleeve lobectomy with double-barreled bronchoplasty for a centrally located lung cancer. *Ann Thorac Surg* 2015; **99**: 1829.
- 11) Hata A, Wada H, Sakairi Y, et al. Extended right upper sleeve lobectomy with double-barrel segmental bronchoplasty. *J Thorac Dis* 2018; **10**: 3059–64.