

# Um Raro Caso de Hepatotoxicidade Induzida pela Empagliflozina

## *A Rare Case of Drug Induced Liver Injury Secondary to Empagliflozin*

Ana Luísa Nunes<sup>1</sup> (<https://orcid.org/0000-0002-5989-4219>), Daniela Santos<sup>1</sup> (<https://orcid.org/0000-0001-5822-2640>), Carolina Figueiredo<sup>2</sup> (<https://orcid.org/0000-0002-6069-8194>), Diana M. Ferreira<sup>1</sup> (<https://orcid.org/0000-0002-2458-048X>), Jandira Lima<sup>1</sup> (<https://orcid.org/0000-0002-4509-8422>), Arsénio Santos<sup>1</sup> (<https://orcid.org/0000-0001-5091-5223>)

### Resumo:

A hepatotoxicidade apresenta um amplo espectro de manifestações clínicas. O diagnóstico constitui um desafio, não só devido ao vasto número de hepatotóxicos, mas particularmente se a capacidade de induzir toxicidade por determinada substância é desconhecida. A empagliflozina associa-se a múltiplos efeitos adversos, mas não de forma convincente à hepatotoxicidade. Apresentamos o caso de uma doente do sexo feminino, de 70 anos, diabética, que desenvolveu sintomas gastrointestinais 1 mês após introdução da empagliflozina. Verificou-se elevação das enzimas hepáticas. Ecograficamente visualizou-se microlitíase vesicular, mas sem obstrução confirmada das vias biliares. Excluídas outras causas de doença hepática. Após biópsia hepática foi diagnosticada hepatotoxicidade secundária à empagliflozina. Objetivou-se resolução completa clínica e analítica após suspensão do antidiabético oral. Foram reportados apenas dois casos de hepatotoxicidade desde o licenciamento da empagliflozina, tornando este caso mais interessante e permitindo sensibilizar os médicos para um diagnóstico precoce e tratamento adequado.

**Palavras-chave:** Doenças Hepática Induzida por Químicos e Fármacos; Inibidores do Transportador Sódio-Glicose 2/efeitos adversos.

### Abstract:

*Drug induced liver injury (DILI) is a condition with a wide clinical spectrum. The diagnosis represents a challenge not only due to the large number of known hepatotoxic products but especially when the substance involved is not known to induce liver damage. Empagliflozin is linked to several adverse effects but has not been convincingly associated to DILI. We report a case of a 70-year-old type 2 diabetic woman that presented with gastrointestinal symptoms 1 month after empagliflozin introduction. Elevated hepatic enzymes were found and despite ultrasound evidence of vesicular microlithiasis, no biliary obstruction was confirmed. Other causes of liver injury*

*were excluded and the diagnosis of DILI secondary to empagliflozin was made after liver biopsy. Complete clinical and laboratorial resolution was verified after empagliflozin withdrawal. Only two cases of DILI were reported since empagliflozin licensure which makes this case more interesting, alerting clinicians to an early diagnosis and appropriate treatment.*

**Keywords:** Chemical and Drug Induced Liver Injury; Sodium-Glucose Transporter 2 Inhibitors/adverse effects.

### Introduction

Drug induced liver injury (DILI) is a well-recognized condition with a wide spectrum of symptoms that can mimic acute and chronic liver diseases. Being able to identify the substance implicated is crucial, since the first-line treatment consists of withdrawing the toxin. There are over 1000 drugs and herbal products described as potential inducers of DILI.<sup>1</sup> When there is a temporal relationship between the onset of a drug administration and the appearance of liver changes, the diagnosis becomes more evident. However, this diagnostic hypothesis is not always obvious, especially when dealing with pharmacological substances without a previous and clear knowledge of causing liver injury. Amongst those drugs is one of the most recent group of oral antidiabetic drugs.

Sodium-glucose cotransporter 2 inhibitors (SGLT-2i) prevent glucose reabsorption in proximal renal tubule resulting in glucose renal excretion and subsequent reduction in serum levels. Four specific drugs (canagliflozin, dapagliflozin, empagliflozin and ertugliflozin) were introduced in clinical practice. Several adverse effects have been described, but none of the four agents was associated with increased serum aminotransferase or alkaline phosphatase in clinical trials, and since licensure, there have been only very rare and not completely conclusive reports<sup>2</sup> of clinically apparent induced liver injury.

Thereby, we present a rare clinical case of a diabetic female patient that develops DILI after initiating empagliflozin 1 month earlier.

### Case Report

A 70-year-old Caucasian woman presented with a 3-day continuous diffuse abdominal pain associated with nausea and diarrhoea (without blood, mucus or pus). The patient denied fever or any other symptoms.

<sup>1</sup>Serviço Medicina Interna, Centro Hospitalar e Universitário de Coimbra, Coimbra, Portugal.

<sup>2</sup>Serviço Dermatologia, Centro Hospitalar e Universitário de Coimbra, Coimbra, Portugal.

She had a long-time history of poorly controlled type 2 diabetes with target organ damage, especially diabetic nephropathy, and severe ischemic heart disease with the need for primary percutaneous angioplasty one year before, due to myocardial infarction (being medicated with acetylsalicylic acid 100 mg/day and ticagrelor 180 mg/day since then). It is noteworthy the introduction of empagliflozin in the last month, aiming to achieve a better disease control, despite glargine insulin therapy. Other relevant past medical history includes obesity, arterial hypertension (well managed with valsartan 80 mg/day, amlodipine 5 mg/day, carvedilol 25 mg/day and furosemide 40 mg/day), dyslipidaemia (under atorvastatin 20 mg/day) and anxiety/depression disorder (medicated with trazodone 100 mg/day, amitriptyline 25 mg/day and pregabalin 150 mg/day). There was no alcohol, drug or any natural products consumption. She denied animal contact and was a pastry chef for a living.

On physical examination she revealed diffuse pain, more intense on the upper right quadrant, without peritoneal irritation signs or Murphy's sign. The remaining of her physical examination was unremarkable.

Laboratory investigation revealed an elevation of both cytolytic and cholestatic parameters (aminotransferases greater than ~4 times the normal upper limit; alkaline phosphatase and gamma-glutamyl transferase increased ~6 and 18 times than the normal upper limit, respectively) despite normal albumin, bilirubin, and coagulation function tests (Table 1). Abdominal and kidney ultrasounds were performed and reported normal, except for vesicular microlithiasis. Thus, she was hospitalized for further investigation, after empagliflozin withdrawal.

**Table 1:** Abnormal blood tests results

Blood test	Result	Normal range
Creatinine	1.6 mg/dL	0.5-1 mg/dL
Lactate dehydrogenase	445 U/L	< 247 U/L
Aspartate aminotransferase	123 U/L	< 31 U/L
Alanine aminotransferase	248 U/L	< 34 U/L
Gamma-glutamyl transferase	553 U/L	< 38 U/L
Alkaline phosphatase	725 U/L	30-120 U/L
C-reactive protein	4.3 mg/dL	< 0.5 mg/dL

Blood and urine cultures and serologies for hepatotropic pathogens (Table 2) were performed and reported negative. Hepatic autoimmune diseases were excluded, and no other immunologic alterations were identified. There was no evidence of copper or iron excess. Since vesicular microlithiasis was

**Table 2:** Blood serologies (hepatotropic virus and bacteria)

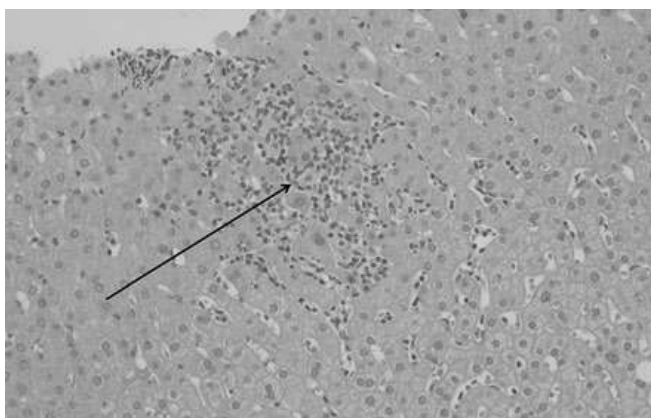
Microorganism	Result	Interpretation
Cytomegalovirus	Positive IgG, negative IgM	Previous infection
Herpes simplex virus 1	Positive IgG, negative IgM	Previous infection
Herpes simplex virus 2	Negative IgG and IgM	No active infection
Epstein-Barr virus	Negative IgG, IgM and EBNA	No active infection
Hepatitis A virus	Negative IgG and IgM	No active infection
Hepatitis B virus	Negative HBsAg, HBsAb and HBcAb	No active infection
Hepatitis C virus	Negative IgG and IgM	No active infection
Hepatitis E virus	Negative IgG and IgM	No active infection
Human immunodeficiency virus	Negative Ag/Ab	No active infection
Treponema pallidum	Negative IgG and IgM	No active infection
Rickettsia conorii	Negative IgG and IgM	No active infection
Coxiella burnetii	Negative IgG and IgM	No active infection

IgG – immunoglobulin G; IgM – immunoglobulin M; EBNA - Epstein-Barr nuclear antigen; HBsAg – hepatitis B surface antigen; HBsAb – hepatitis B surface antibody; HBcAb – hepatitis B core antibody; Ag- antigen; Ab – antibody.

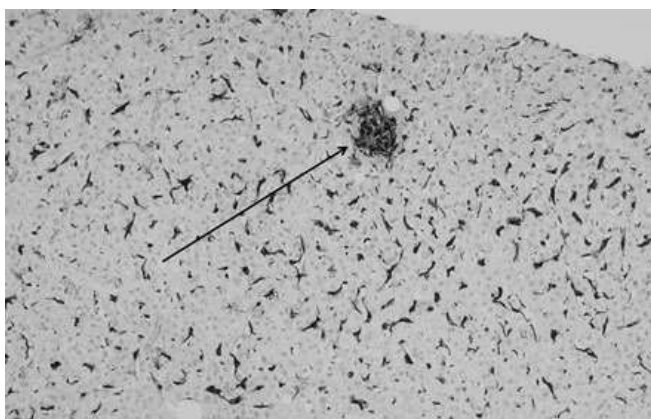
described, despite the absence of ultrasound signs of cholecystitis or choledocholithiasis, a magnetic resonance cholangiopancreatography (MRCP) was carried out. However, no pathological lithiasic condition or biliary tract dilatation was evident.

According to the findings, the hypothesis of liver toxicity secondary to empagliflozin became the most likely. Although there was a progressive normalization of liver enzymes after empagliflozin suspension, a liver biopsy was needed to enhance the hypothesis. Non necrotizing lobular microgranulomas (Fig.s 1 e 2) were found and there was no inflammatory infiltrate, loss of biliary ducts or visualization of microorganisms, suggesting the diagnosis of liver toxicity.

The acute toxic hepatitis was attributed to empagliflozin, introduced 1 month earlier. The remaining drugs that could induce liver toxicity were not discontinued, given their chronicity over more than 1 year.



**Figure 1:** Liver parenchyma with microgranulomas (arrow) (hematoxylin-eosin staining, 200x magnification).



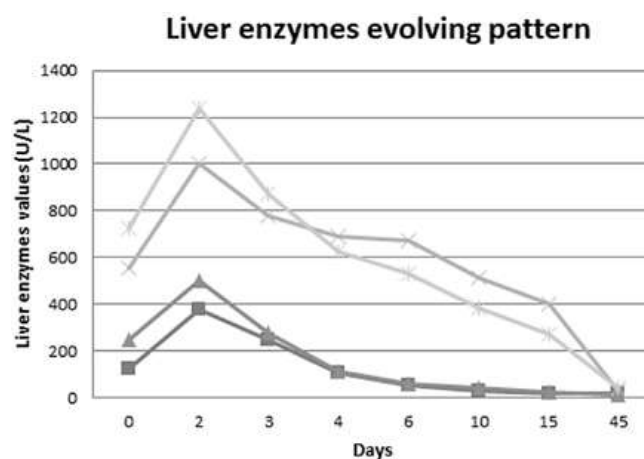
**Figure 2:** A microgranuloma is highlighted by the CD68 stain (arrow), which also exhibits Kupffer cell hyperplasia (100x magnification).

She had a favourable evolution and was discharged after 2 weeks of hospitalization with a reinforced dietetic, exercise and insulin therapy plan. At 1-month follow-up she was asymptomatic, without analytical changes (Fig. 3).

## Discussion

DILI accounts for <1% of cases of acute liver injury but it is the most common cause for acute liver failure in the USA and Europe. This condition is one of the main reasons for drug withdrawal. In contrast to intrinsic DILI, the onset of idiosyncratic DILI, which is less common but nonetheless responsible for about 10%-15% of acute liver failures in the USA, is almost impossible to predict, being characterized by a variable latency to onset (weeks to months) and a lack of clear dose dependency.<sup>3</sup>

Once DILI is induced by many drugs, herbs, and dietary supplements it can represent a diagnostic challenge, particularly in polymedicated patients. The development of nonspecific symptoms after introducing a new drug may indicate drug toxicity and an evaluation for DILI should be



**Figure 3:** Liver enzymes evolving pattern: progressive normalization of liver enzymes during the 15 days of hospitalization, with a slower lowering of cholestatic enzymes. One month after discharge (45 days after being admitted to the emergency department) there was a complete normalization of the hepatic alterations.

AST - aspartate aminotransferase. ALT - alanine aminotransferase. GGT - gamma - glutamyl transferase. FA - alkaline phosphatase.

considered. A high clinical suspicion after a thorough history is crucial for the diagnosis. Blood tests to exclude other causes of liver injury, including viral and autoimmune diseases, are also necessary. It is known that ageing influences DILI phenotypes, making cholestatic damage more likely in  $\geq 60$ -year-old patients, regardless of the used drug. Therefore, MRCP is indicated to rule out biliary obstruction if cholestasis is present.<sup>4</sup>

Liver biopsy may suggest the diagnosis of DILI through the histological pattern of injury and correlation with clinical history, laboratory, and imaging data. When alternative causes for liver injury have been excluded and the patient has been exposed to a drug known to induce hepatic injury, DILI can be assumed as final diagnosis and no liver biopsy is necessary. In fact, liver biopsy is not routinely used in the evaluation of suspected DILI, except when the diagnosis or the injury severity remains uncertain. After excluding the main causes for necrotizing microgranulomas (such as sarcoidosis and tuberculosis), the probability of them being induced by drugs is high.<sup>5</sup> Despite this, it is noteworthy that complete confirmation of DILI may require following the patient long past the point of liver biopsy and in our patient, we verified a complete normalization of liver changes after empagliflozin withdrawal.<sup>6</sup>

Empagliflozin is a SGLT-2i that can be safely used in mono or combined therapy, due to its insulin independent action mechanism. Empagliflozin was approved in 2014 for management of hyperglycaemia in type 2 diabetes. In 2017, the indications to its use were extended to decreasing the risk of cardiovascular death in adults with type 2 diabetes and associated cardiovascular disease.

In clinical trials phase III empagliflozin was well tolerated

and most adverse effects were mild to moderate, leading to discontinuation of the drug in a similar proportion to the placebo group. The only official contraindication to the use of empagliflozin is hypersensitivity to the correspondent substance.<sup>7</sup>

DILI by any of the SGLT-2i is quite rare and this may be related to their minimal hepatic metabolism which is largely via uridine diphosphate glucuronyltransferase. A prospective study carried out between 2004 and 2013 identified 899 cases of DILI, but none attributable to SGLT-2i.<sup>8</sup> Indeed, a systematic review of 18 controlled trials of type 2 diabetic patients treated with SGLT-2i found out that this pharmacological group not only was not associated to hepatotoxicity, but in fact reduced ALT levels compared to placebo (by an average of 2.8U/L).<sup>9</sup>

In multiple randomized controlled trials, empagliflozin was not associated with liver enzymes elevation during therapy.<sup>10</sup> By the contrary, there are trials that can identify a reduction in cytolysis and/or cholestasis parameters for all the SGLT-2i, probably as a result of concurrent improvement in fatty liver disease due to a better glycaemic control, weight loss or both.<sup>11</sup> During prelicensure studies, no clinically apparent acute liver injury was convincingly linked to empagliflozin<sup>12</sup> and hepatic enzymes elevation accompanied by jaundice occurred equally in dapagliflozin<sup>13</sup> and placebo groups. Since SGLT-2i approval and more widespread use, there have been only 2 cases of DILI reported:

1) A young female patient with non-alcoholic fatty liver disease and cirrhosis developed decompensation with jaundice, ascites and encephalopathy 10 weeks after starting dapagliflozin, having somewhat improved after stopping therapy, but ultimately required liver transplantation several months later<sup>14</sup>;

2) An elderly woman with non-alcoholic fatty liver disease developed fever, jaundice and liver enzymes elevation 6 weeks after starting empagliflozin, which resolved within a week after withdrawal and remained normal thereafter.<sup>15</sup>

It is noteworthy to point out that both of the cases occurred in patients with previous liver conditions, just like it happened with our patient, that also had hepatic steatosis.

Despite being an overall safe pharmacological group, with few known adverse effects, SGLT-2i may develop hepatotoxicity, as described previously in the literature. The fact that DILI is so rare with these drugs makes this case even more interesting, as it alerts the clinicians to an early diagnosis and appropriate treatment, with immediate suspension of the drug. ■

### Responsabilidades Éticas

Conflitos de Interesse: Os autores declaram a inexistência de conflitos de interesse na realização do presente trabalho.

Fontes de Financiamento: Não existiram fontes externas de financiamento para a realização deste artigo.

Confidencialidade dos Dados: Os autores declaram ter seguido os protocolos da sua instituição acerca da publicação dos dados de doentes.

Consentimento: Consentimento do doente para publicação obtido.

Proveniência e Revisão por Pares: Não comissionado; revisão externa por pares.

### Ethical Disclosures

Conflicts of interest: The authors have no conflicts of interest to declare.

Financing Support: This work has not received any contribution, grant or scholarship

Confidentiality of Data: The authors declare that they have followed the protocols of their work center on the publication of data from patients.

Patient Consent: Consent for publication was obtained.

Provenance and Peer Review: Not commissioned; externally peer reviewed.

© Autor (es) (ou seu (s) empregador (es)) e Revista SPMI 2021. Reutilização permitida de acordo com CC BY-NC. Nenhuma reutilização comercial.

© Author(s) (or their employer(s)) and SPMI Journal 2021. Re-use permitted under CC BY-NC. No commercial re-use.

### Correspondence / Correspondência:

Ana Luísa Nunes – ana.luisa.s.nunes@gmail.com

Serviço Medicina Interna, Centro Hospitalar e Universitário de Coimbra, Coimbra, Portugal.

Praceta Prof. Mota Pinto, 3000-075 – Coimbra

Received / Recebido: 29/04/2021

Accepted / Aceite: 18/08/2021

Publicado / Published: 21/12/2021

### REFERENCES

1. Stirnimann G, Kessebohm K, Lauterburg B. Liver injury caused by drugs: an update. *Swiss Med Wkly*. 2010;140:w13080. doi: 10.4414/smw.2010.13080.
2. LiverTox: Clinical and Research Information on Drug-Induced Liver Injury [Internet]. Bethesda (MD): National Institute of Diabetes and Digestive and Kidney Diseases; 2012. Sodium Glucose Cotransporter-2 (SGLT-2) Inhibitors. [Updated 2018 Dec 17]. Available from: <https://www.ncbi.nlm.nih.gov/books/NBK548289/>
3. Andrade RJ, Aithal G, Björnsson E, Kaplowitz N, Kullak-Ublick GA, Larrey D, et al. EASL Clinical Practice Guidelines: Drug-induced liver injury. *J Hepatol*. 2019;70:1222-61. doi: 10.1016/j.jhep.2019.02.014.
4. Lucena MI, Sanabria J, García-Cortes M, Stephens C, Andrade RJ. Drug-induced liver injury in older people. *Lancet Gastroenterol Hepatol*. 2020;5:862-74. doi: 10.1016/S2468-1253(20)30006-6.
5. Culver EL, Watkins J, Westbrook RH. Granulomas of the liver. *Clin Liver Dis*. 2016;7:92-6. doi: 10.1002/cl.544.
6. Kleiner DE. Liver histology in the diagnosis and prognosis of drug-induced liver injury. *Clin Liver Dis*. 2014;4:12-6.
7. Calado J, Silva Nunes J. Empagliflozina: Uma Nova Arma Farmacológica na Terapêutica da Diabetes Tipo 2. *Rev Port Diabetes*. 2015; 10: 118-26.
8. Chalasani N, Bonkovsky HL, Fontana R, Lee W, Stolz A, Talwalkar J, et al. Features and Outcomes of 899 Patients With Drug-Induced Liver Injury: The DILIN Prospective Study. *Gastroenterology*. 2015;148:1340-52.
9. Storgaard H, Gluud LL, Bennett C, Grøndahl MF, Christensen MB, Knop FK, et al. Benefits and Harms of Sodium-Glucose Co-Transporter 2 Inhibitors in Patients with Type 2 Diabetes: A Systematic Review and Meta-Analysis. *PLoS One*. 2016;11:e0166125.

10. Häring HU, Merker L, Seewaldt-Becker E, Weimer M, Meinicke T, Woerle HJ, et al. Empagliflozin as add-on to metformin plus sulfonylurea in patients with type 2 diabetes: a 24-week, randomized, double-blind, placebo-controlled trial. *Diabetes Care*. 2013;36:3396-404.
11. Kuchay MS, Krishan S, Mishra SK, Farooqui KJ, Singh MK, Wasir JS, et al. Effect of empagliflozin on liver fat in patients with type 2 diabetes and nonalcoholic fatty liver disease: A Randomized Controlled Trial (E-LIFT Trial). *Diabetes Care*. 2018;41:1801-08. doi: 10.2337/dc18-0165.
12. Ridderstråle M, Andersen KR, Zeller C, Kim G, Woerle HJ, Broedl UC. Comparison of empagliflozin and glimepiride as add-on to metformin in patients with type 2 diabetes: a 104-week randomised, active-controlled, double-blind, phase 3 trial. *Lancet Diabetes Endocrinol*. 2014;2:691-700.
13. Ptaszynska A, Johnsson KM, Parikh SJ, de Bruin TW, Apanovitch AM, List JF. Safety profile of dapagliflozin for type 2 diabetes: pooled analysis of clinical studies for overall safety and rare events. *Drug Saf*. 2014;37:815-29. doi: 10.1007/s40264-014-0213-4.
14. Levine JA, Lo AA, Wallia A, Rogers M, VanWagner LB. Dapagliflozin-induced acute-on-chronic liver injury. *ACG Case Rep J*. 2016;3:e169. doi: 10.14309/crj.2016.142.
15. Famularo G, Sajeve MR, Marino G, Granato C. Acute hepatitis caused by empagliflozin in a nonalcoholic fatty liver disease patient. *Ann Pharmacother*. 2017;51:1142-3.