

## **Progressive radial nerve entrapment resulted in finger drop**

### **A case report**

Emamhadi, Mohammadreza; Emamhadi, Roxana; Andalib, Sasan

*Published in:*  
Trauma Monthly

*DOI:*  
10.5812/traumamon.85461

*Publication date:*  
2019

*Document version:*  
Final published version

*Document license:*  
CC BY-NC

*Citation for pulished version (APA):*  
Emamhadi, M., Emamhadi, R., & Andalib, S. (2019). Progressive radial nerve entrapment resulted in finger drop: A case report. *Trauma Monthly*, 24(3), [e85461]. <https://doi.org/10.5812/traumamon.85461>

Go to publication entry in University of Southern Denmark's Research Portal

#### **Terms of use**

This work is brought to you by the University of Southern Denmark.  
Unless otherwise specified it has been shared according to the terms for self-archiving.  
If no other license is stated, these terms apply:

- You may download this work for personal use only.
- You may not further distribute the material or use it for any profit-making activity or commercial gain
- You may freely distribute the URL identifying this open access version

If you believe that this document breaches copyright please contact us providing details and we will investigate your claim.  
Please direct all enquiries to [puresupport@bib.sdu.dk](mailto:puresupport@bib.sdu.dk)



# Progressive Radial Nerve Entrapment Resulted in Finger Drop: A Case Report

Mohammadreza Emamhadi<sup>1</sup>, Roxana Emamhadi<sup>2</sup> and Sasan Andalib<sup>3, 4, 5, 6, 7, \*</sup>

<sup>1</sup>Brachial Plexus and Peripheral Nerve Injury Center, Guilan University of Medical Sciences, Rasht, Iran

<sup>2</sup>Department of Biotechnology, School of Basic Sciences, Tonekabon Branch, Islamic Azad University, Tonekabon, Iran

<sup>3</sup>Neuroscience Research Center, Poursina Hospital, Guilan University of Medical Sciences, Rasht, Iran

<sup>4</sup>Department of Neurosurgery, Poursina Hospital, School of Medicine, Guilan University of Medical Sciences, Rasht, Iran

<sup>5</sup>Road Trauma Research Center, Poursina Hospital, Guilan University of Medical Sciences, Rasht, Iran

<sup>6</sup>Department of Nuclear Medicine, Odense University Hospital, Odense, Denmark

<sup>7</sup>Department of Clinical Research, Faculty of Health Sciences, University of Southern Denmark, Odense, Denmark

\* Corresponding author: Neuroscience Research Center, Department of Neurosurgery, Poursina Hospital, School of Medicine, Guilan University of Medical Sciences, Rasht, Iran. Tel/Fax: +98-133322444, Email: andalib@gums.ac.ir

Received 2018 October 17; Revised 2019 March 19; Accepted 2019 April 12.

## Abstract

**Introduction:** Posterior interosseous nerve (PIN) palsy gives rise to various symptoms. The PIN due to lipoma is rare. Here, we report a case of progressive loss of finger extension due to a giant painless parosteal lipoma.

**Case Presentation:** A 52-year-old patient with progressive weakness of finger extension with diagnosis of posterior interosseous nerve (PIN) palsy was referred to our clinic. Electrophysiological studies showed a right PIN neuropathy at the level of the forearm. The patient had no history of trauma of the hand. The patient underwent surgery for tumor removal and nerve decompression. The loss of finger extension due to PIN palsy gradually recovered after tumor removal and the nerve recovered from the motor deficits. The patient showed no recurrence of motor deficit after the surgery in the follow-up.

**Conclusions:** Since PIN palsy may arise from lipoma early surgical exploration and the excision of deep-seated lipoma in the proximal forearm is recommended in order to avoid permanent damage to PIN or other branches of the radial nerve.

**Keywords:** Parosteal Lipoma, Finger Drop, Posterior Interosseous Nerve, Palsy

## 1. Introduction

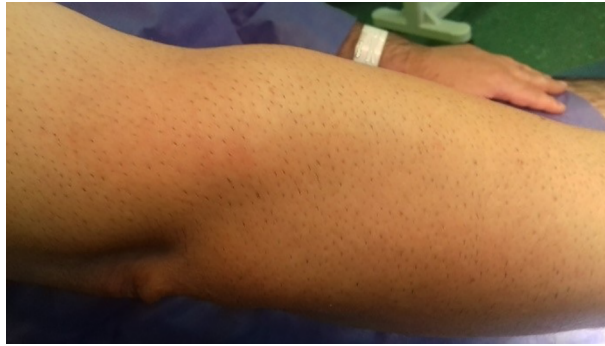Parosteal lipomas are benign fat tumors, closely linked to the periosteum. These tumors are rare and constitute 0.3% of all lipomas (1). Proximal forearm lipomas, which were first introduced in the literature by Richmond in 1953 (2), are uncommon causes of posterior interosseous nerve (PIN) compression. These tumors have mature adult fat, which is similar to soft-tissue lipomas, and an osseous stalk with cortical thickening is normally found. The most common sites of parosteal lipomas are the femoral, radial, and humeral diaphysis. The tumors are likely to rest directly on the cortex without bone or cartilage. The narrow osseous stalk in these tumors may have a lucent lipomatous cap, which mimics a pedunculated exostosis. On the other hand, radial tunnel entrance is made by the arcade of Fröhse, which is the most common site of compression of the radial nerve motor branch (3). In plain radiograph, the parosteal lipoma is typically seen as a large lucent mass and in CT scan, which is done for differentiation from osteochondroma, is found with lack of under-

lying medullary continuity. Moreover, it is visualized as a T1/T2 hyperintense mass without signal on fat suppression in magnetic resonance imaging (MRI). The MRI can more appropriately assess the adjacent nerve involvement and muscle atrophy. A few cases of PIN palsy owing to parosteal lipoma have so far been reported. We here report a case of PIN palsy with progressive loss of finger extension caused by a giant painless parosteal lipoma.

## 2. Case Presentation

A 52-year-old man, who was a bank clerk, presented with a 6-month progressive difficulty of active extension of his fingers in his right hand along with a mass in dorsal aspect of the proximal forearm for the last two months. He complained about his personal and occupational disability of releasing objects when he held them with his hand. Physical examination showed a non-tender soft mass on the right proximal forearm (Figure 1). There was no active extension of all the fingers at the MP joint (Figure 2) and all

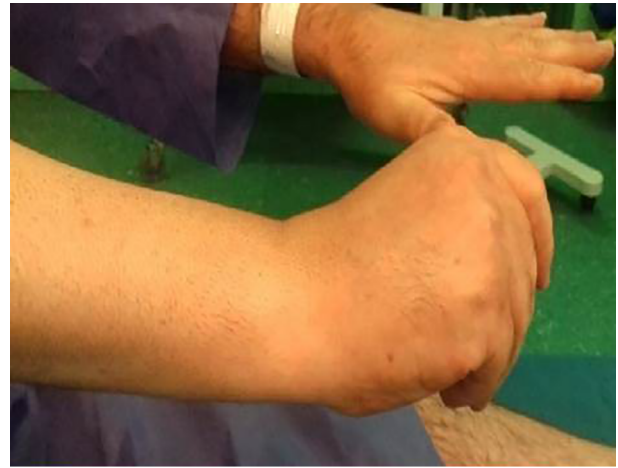the finger joints showed a full range of passive movement, notwithstanding normal active wrist extension and sensation. Magnetic resonance imaging of the right forearm illustrated a giant well-defined fatty lesion ([Figure 3](#)).



**Figure 1.** A non-tender soft mass on the right proximal forearm

### 2.1. Surgical Technique

A vertical incision was made on the dorsal surface of the right forearm over the tumor and extended interval between the extensor carpi radialis longus (ECRL) and the brachioradialis (BR) muscles in the right proximal forearm over the tumor. The superficial radial nerve (SRN) was explored after dividing ECRL and BR muscles. The BR has a thinner fascial layer, making it appear redder, whereas the ECRL, encased in the thicker fascia, appears lighter or white. Blunt finger dissection can be done easily toward the arcade of Fröhse. If there is any difficulty dissecting between these two muscles, then the surgical plane is not correct. The SRN was then followed proximally to expose the PIN and extensor carpi radialis brevis (ECRB) nerve. Normally, the SRN is located medially, and the PIN is located laterally. The smaller ECRB nerve is located between these two nerves and the PIN is obliquely oriented as it dives under the superficial head of the supinator, but in this case, the PIN and ECRB nerves were found to run over the tumor and pushed up ([Figure 4](#)). This caused great pressure on the nerve. The tumor originated under the supinator muscle, and the tendon of ECRB muscle and the upper layer of supinator muscles were cut to open the radial tunnel. There was a lobulated lipoma, which was well encapsulated. The tumor was excised undocking the periosteal attachment. Sutures were removed ten days after the surgery. On gross pathology, the tumor was a huge multilobulated well-encapsulated well-defined irregular soft yellowish homogeneously greasy mass ([Figure 5](#)). Histopathology confirmed that the lesion was composed

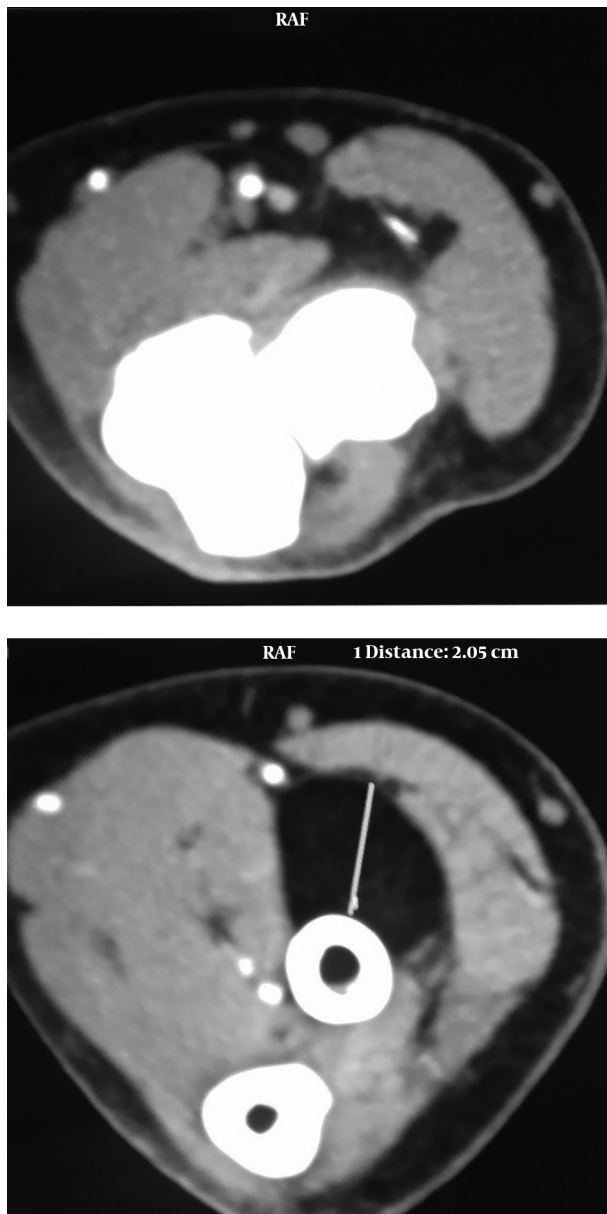


**Figure 2.** No active extension of all right fingers at the MP joint

of mature lipocytes without any cellular atypia. Active extension of all right fingers returned a year after surgery, as illustrated in [Figure 6](#).

### 3. Discussion

In clinical setting, non-traumatic PIN palsy is uncommon. Most of the involvements occur in the fifth to eighth decades of life ([4](#)). Diagnosis of PIN palsy can be challenging and suspicion needs to be maintained, especially when there is uncertainty in the diagnosis ([4](#)). Compression or entrapment of the PIN may be present at various anatomies in the forearm ([5](#)). However, PIN palsy due to lipomas is usually seen at elbow level ([6](#)). A few cases of PIN palsy owing to proximal radius parosteal lipoma have been reported to date ([1, 4, 7-10](#)). We presented a case with non-traumatic progressive finger drop at the MP joint of the

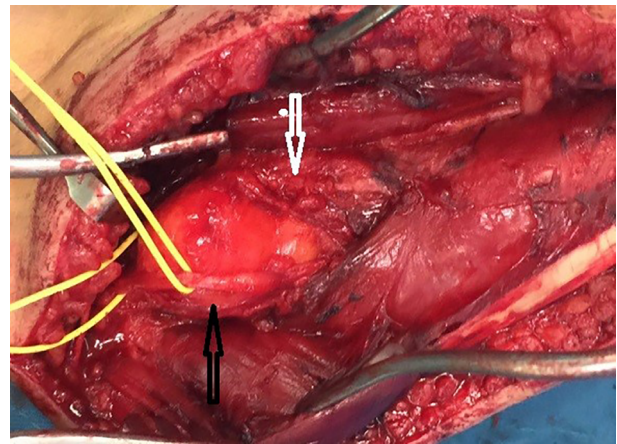


**Figure 3.** Magnetic resonance imaging (MRI) of the right forearm illustrated a giant well-defined fatty lesion

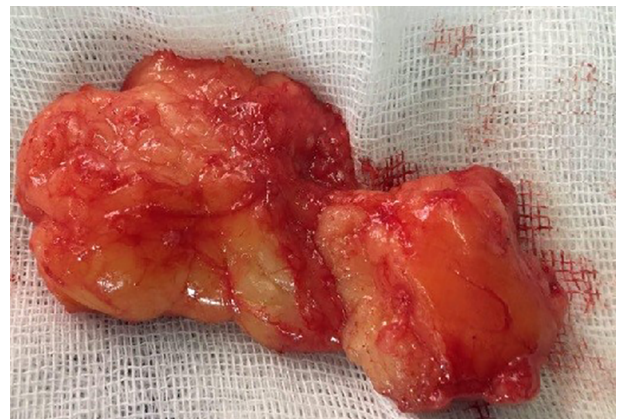right forearm and a full range of passive movement in all the finger joints in which MRI showed a giant well-defined fatty lesion. The PIN decompression is performed using posterolateral or anterior surgical approaches. Fitzgerald et al. used the anterior approach for dissection of tumors, enabling direct visualization of parosteal lipoma and decreasing the risk of damage to the main nerve and muscular branches (7). Nonetheless, Fernandez et al. utilized the posterolateral approach, enabling a complete visual-

ization of the PIN course as we did it (11). The parosteal lipoma is treated by complete surgical resection and when nerve entrapment is present, the tumor must be dissected to prevent irreversible muscle atrophy and maintain the nerve function. Furthermore, separation of the nerve from the parosteal lipoma must be done with care.

In conclusion, presence of tumors should be evaluated in any cases of nontraumatic progressive finger drop, especially in proximal radius parosteal lipomas, which have an excellent prognosis and are without recurrence. In the proximal forearm, early exploration and excision of deep parosteal lipomas are recommended to prevent damage to the PIN or other branches of the radial nerve.



**Figure 4.** The PIN (black arrow) and ECRB nerve (white arrow) were found to be ran over the tumor and pushed up



**Figure 5.** On gross pathology, a huge multilobulated well-defined irregular soft yellowish homogenously greasy mass was seen





**Figure 6.** Active extension of all right fingers returned a year after the surgery

### Footnotes

**Conflict of Interests:** The authors declare no conflict of interest.

**Funding/Supprot:** No funding was received.

**Patient Consent:** Informed consent was obtained from the patient.

### References

1. Hamdi MF, Aloui I, Allagui M, Abid A. Paralysis of posterior interosseous nerve caused by parosteal lipoma. *Neurol India*. 2010;**58**(2):319–20. doi: [10.4103/0028-3886.63790](#). [PubMed: [20508361](#)].
2. Richmond DA. Lipoma causing a posterior interosseous nerve lesion. *J Bone Joint Surg Br*. 1953;**35-B**(1):83. doi: [10.1302/0301-620X.35B1.83](#). [PubMed: [13034877](#)].
3. Clavert P, Lutz JC, Adam P, Wolfram-Gabel R, Liverneaux P, Kahn JL. Frohse's arcade is not the exclusive compression site of the radial nerve in its tunnel. *Orthop Traumatol Surg Res*. 2009;**95**(2):114–8. doi: [10.1016/j.otsr.2008.11.001](#). [PubMed: [19297265](#)].
4. Avram R, Hynes NM. Posterior interosseous nerve compression secondary to a parosteal lipoma: Case report and literature review. *Can J Plast Surg*. 2004;**12**(2):69–72. doi: [10.4172/plastic-surgery.1000398](#). [PubMed: [24115878](#)]. [PubMed Central: [PMC3792810](#)].
5. Salama H, Kumar P, Bastawrous S. Posterior interosseous nerve palsy caused by parosteal lipoma: A case report. *Case Rep Med*. 2010;**2010**. doi: [10.1155/2010/785202](#). [PubMed: [20811574](#)]. [PubMed Central: [PMC2929686](#)].
6. Henrique A. A high radial neuropathy by parosteal lipoma compression. *J Shoulder Elbow Surg*. 2002;**11**(4):386–8. doi: [10.1067/mse.2002.121766](#). [PubMed: [12195259](#)].
7. Fitzgerald A, Anderson W, Hooper G. Posterior interosseous nerve palsy due to parosteal lipoma. *J Hand Surg Br*. 2002;**27**(6):535–7. doi: [10.1054/jhsb.2002.0783](#). [PubMed: [12475510](#)].
8. Nishida J, Shimamura T, Ehara S, Shiraishi H, Sato T, Abe M. Posterior interosseous nerve palsy caused by parosteal lipoma of proximal radius. *Skeletal Radiol*. 1998;**27**(7):375–9. doi: [10.1007/s002560050401](#). [PubMed: [9730328](#)].
9. Seki Y, Hoshino Y, Kuroda H. Posterior interosseous nerve palsy due to parosteal lipoma. *Neurol India*. 2012;**60**(6):644–5. doi: [10.4103/0028-3886.105203](#). [PubMed: [23287331](#)].
10. Lidor C, Lotem M, Hallel T. Parosteal lipoma of the proximal radius: A report of five cases. *J Hand Surg Am*. 1992;**17**(6):1095–7. doi: [10.1016/S0363-5023\(09\)91072-3](#). [PubMed: [1430948](#)].
11. Fernandez E, Pallini R, Lauretti L, Scogna A, Di Rienzo A. Neurosurgery of the peripheral nervous system: The posterior interosseous nerve syndrome. *Surg Neurol*. 1998;**49**(6):637–9. doi: [10.1016/S0090-3019\(97\)00489-8](#). [PubMed: [9637624](#)].