

The effect of *Hypericum Perforatum* on wound healing of oral mucosa in diabetic rats

Purpose

This study aims to investigate the histopathological and biochemical effects of the topical application of *Hypericum perforatum* on the healing of surgical wounds created in the oral mucosa of rats with experimentally induced diabetes mellitus.

Materials and methods

The study was carried out on 48 adult male Wistar albino rats. The animals were divided into two main groups as control and study groups. Two main groups were divided into three subgroups according to the sacrifice days. All rats were given streptozotocin 60 mg/kg, after 72 hours, and those having blood glucose levels above 200 mg/dL were included in the study. Mucosal defects were created in the palatal area of the rats. *H. perforatum* oil was applied topically twice a day to the wounds of the rats in the study group. Animals were sacrificed on the 3rd, 7th and 10th days and samples taken from the palatal wounds were examined histologically and biochemically.

Results

On the 7th day, ulceration, necrosis, epithelialization, polymorphonuclear leucocytes and hydroxyproline variables showed statistically significant differences ($p < 0.05$). Ulceration, necrosis and polymorphonuclear leukocytes values were higher in the control group, whereas epithelialization and hydroxyproline values were found to be higher in the *H. perforatum* group. Among 10th-day groups, there was only a statistically significant difference between the values of hydroxyproline, whereas *H. perforatum*-treated group showed high hydroxyproline levels ($p < 0.05$).







Conclusion

Topically applied *H. perforatum* did not create any difference on the 3rd day, but it has positively affected the wound healing on the 7th and 10th days in diabetic rats.

Keywords: Diabetes mellitus; *H. perforatum*; oral mucosa; St. John's Wort; wound healing

Introduction

Wound healing is characterized by the unification of epithelial cells, endothelial cells, inflammatory cells, platelets and fibroblasts, and the fulfilment of their normal functions in a specific sequence and order. Many people in the world are known to suffer from chronic wounds. There are many systemic and local factors affecting wound healing. Diabetes mellitus is a chronic metabolic disease with negative effects on wound healing. Diabetes has the effect of reducing wound tension and hydroxyproline levels. Problems encountered during wound healing in diabetic patients include decreased cellular infiltration, granulation tissue, angiogenesis and the amount and formation of collagens, resulting in increased infectious complications. Even though the causes of these problems seen in diabetes cannot be fully explained, hyperglycemia is generally held responsible for

Ahmet Altan¹, 
Mutan Hamdi Aras², 
İbrahim Damlar³, 
Hasan Gökçe⁴, 
Oğuzhan Özcan⁵, 
Cansu Alpaslan⁶ 

ORCID IDs of the authors: A.A. 0000-0003-2041-6364;
M.H.A. 0000-0002-8907-7340; İ.D. 0000-0003-1453-5391;
H.G. 0000-0002-4658-9987; O.Ö. 0000-0001-7486-503X;
C.A. 0000-0003-2092-7842.

¹Department of Oral and Maxillofacial Surgery,
Gaziosmanpaşa University, Faculty of Dentistry, Tokat, Turkey

²Private Practice, Gaziantep, Turkey

³Private Practice, Hatay, Turkey

⁴Department of Pathology, İnönü University, Faculty of
Medicine, Malatya, Turkey

⁵Department of Biochemistry, Mustafa Kemal University,
Faculty of Medicine, Hatay, Turkey

⁶Department of Oral and Maxillofacial Surgery, Gazi
University, Faculty of Dentistry, Ankara, Turkey

This study was presented at the 22nd International
Scientific Congress of Turkish Association of Oral and
Maxillofacial Surgery, May 19 to 22, 2015, Bodrum,
Turkey, as an oral presentation.

Corresponding Author: Ahmet Altan
E-mail: dt.ahmetaltan@gmail.com

Received: 09 October 2017

Revised: 13 November 2017

Accepted: 10 January 2018

DOI: 10.26650/eor.2018.505

this situation. High blood glucose levels have been shown to inhibit cell proliferation and collagen production. Moreover, conditions such as the reduction of growth factors and fibroblast proliferation, apoptosis increase in wound tissue cells, infections caused by the decrease in chemotaxis and phagocytosis, have shown to be adverse effects of hyperglycemia on wound healing as well (1).

Plants have historically played an important role in the recovery of human health. *Hypericum perforatum*, a member of the Hypericaceae family, has been considered a valuable herbal medicine. This plant contains hyperforin, flavonoids and hypericin (2). Olive oil extract of *H. perforatum* has long been used both topically and orally as a homemade remedy to treat cuts, burns, depression, haemorrhoids, diabetes and gastrointestinal ulcers (3). Damlar *et al.* (4) reported that *H. perforatum* improve bone healing in defects filled with bovine-derived xenograft. The studies showed that *H. perforatum*, increased collagen deposition, shortened the duration of inflammation and stopped the migration of fibroblasts during wound healing (5).

The aim of this study to investigate the histopathological and biochemical effects of the topical application of *H. perforatum* on wound healing in the oral mucosa of experimentally induced diabetic rats. The null hypothesis tested in this study is that the topical application of *H. perforatum* does not have any histological and/or biochemical effect on the healing of surgical defects created in the palatal mucosa of diabetic rats.

Materials and methods

Animals

This study was conducted with conformity approval from the Animal Ethics Committee of Mustafa Kemal University (No: 2014017), regarding the ethical treatment of animals. 48 adult male Wistar albino rats were used, with an average age of 5 months and weight of 300–350 g. The experimental animals were given water ad libitum and standard rat chow, and they were kept in metal cages at room temperature, with a 12-hour light/dark cycle. Streptozotocin (STZ) was used to create experimentally induced diabetes. The dosage was calculated as 60 mg/kg, and a single dose of STZ was intraperitoneally injected into each rat. 72 hours after the STZ injection, blood glucose levels were determined from blood samples taken from the tail vein. The rats with blood glucose levels above 200 mg/dL were considered diabetic and those below this value were excluded from the study. Forty-eight rats were randomly divided into 2 groups of equal numbers as the study and control groups. *H. perforatum* oil was applied topically to rats in the study group two times daily, whereas the wound healing of rats in the control group was followed without any intervention. The animals were sacrificed on the 3rd, 7th and 10th day with cervical dislocation.

Surgical procedure

Prior to wound formation, the rats were anesthetized by intramuscular injection of 30 mg/kg ketamine-HCL and 5 mg/kg xylazine HCL. Next, 4-mm mucosal defects were created

with round, stainless steel blades designed for punch biopsy in the palatal area of each rat (Figure 1). Following bleeding control, the wounds were left for secondary healing. The first day of formation of the wounds was recorded as day zero.

Preparation of traditional *Hypericum perforatum* oil

Natural *H. perforatum* flowers were collected, from Çamlıyayla, Mersin, dried and pulverized, and 50 g of *H. perforatum* was placed in a transparent glass jar containing 500 mL of olive oil. This jar was kept in the sunshine for 4 weeks during summer for 12 hours a day (3). It was observed that the red dye of the herb diffused into the olive oil. Gas chromatograph-mass spectrometer (GC-MS) and high-performance liquid chromatography (HPLC) (Shimadzu QP2010 Ultra, Kyoto, Japan) were used for analysis of the components of *Hypericum perforatum* oil extract. Results were compatible with previous studies (6, 7). Naftodiantron (0.06–0.4%), phenylpropanes (<1%), flavonoids (2–4%), proanthocyanidins (2–4%), phloroglucinols (0.2–4%) and biflavons represent the main components of this plant. The essential oils were listed as palmitic acid (17.61%), cyclopentadecanone, 2-hydroxy- (66.75%), heneicosane (2.27%) and cyclopropaneoctanoic acid (2.53%).

Histopathological evaluation

From all groups, samples of full thickness mucosa were collected from palate wound formations on the 3rd, 7th and 10th day, including robust tissue of 1 x 1 cm. The samples were fixed in 10% formalin solution for 48 hours and embedded in paraffin. The prepared slides were stained with hematoxylin-eosin and evaluated by light microscopy for monitoring inflammatory changes in the healing wounds and to examine the morphology. Histopathological analysis was performed at the Department of Pathology, Mustafa Kemal University by a single blinded examiner. Ulceration, necrosis and epithelialization variables were evaluated as present (1) and absent (0), whereas oedema, polymorphonuclear leukocytes (PNLs), mononuclear cells (MNLs), fibroblasts and vascularization were scored and evaluated as absent (0), low (1), moderate (2) or severe (3).

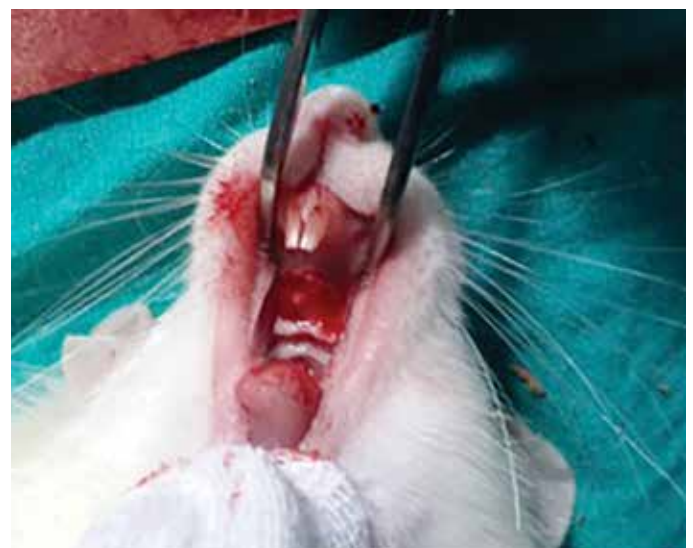

Figure 1. Rat palatal wound after surgery.

Biochemical examination

The hydroxyproline determination on the palate samples from the 3rd, 7th and 10th days was performed by partly modifying the method that was described by Woessner (8). In this method, chloramine T is neutralized with perchloric acid prior to reaction with p-dimethylaminobenzaldehyde (Ehrlich's reagent). The tissue samples were mixed with 1 mL buffered chloramine T reagent and incubated for 20 min at room temperature. Then, 1 mL perchloric acid was added and the mixture was incubated for a further 5 minutes at room temperature before addition of 1 mL Ehrlich's reagent. The mixture was heated for 20 minutes at 60°C, cooled, and then absorbance was determined at 550 nm. The hydroxyproline concentration (1 mg/mL in 1 mM HCl) was determined.

Statistical analysis

IBM Statistical Package for the Social Sciences Statistics for Windows, version 20.0 (IBM Corp.; Armonk, NY, USA) was used for statistical analysis of the data. Mean, standard deviation, median and frequency were used for descriptive statistics. The consistency of the variables with normal distribution assumptions were tested with the Shapiro–Wilks test. In a general comparison of measurements of the groups with normal distribution, Student's t-test was used. The Mann–Whitney U test was used to compare abnormally distributed variables. Evaluation of categorical variables was performed with the chi-square test. Confidence interval was set to 95% and p values less than 0.05 were considered as statistically significant.

Results

The results of the statistical analysis showed that on the 3rd (Figure 2) and 10th days, no statistical difference between the two groups was found in any of the variables evaluated by histopathologic examination. On the 7th day, necrosis, epithelialization, ulceration and PNL parameters showed statistically significant differences ($p < 0.05$) (Figure 3). It was found that the ulceration, necrosis and PNL values of these variables were higher in the control group, whereas the epithelialization value was found to be higher in the *H. perforatum*-administered group (Table 1).

On the 3rd day, no statistically significant difference between the two groups was found for the hydroxyproline level assessed by biochemical analysis ($p > 0.05$). On the 7th and 10th days, the comparison between groups showed statistically significant differences ($p < 0.05$). It was found that the amount of hydroxyproline was higher in the *H. perforatum*-administered group on the 7th and 10th days (Figure 4).

Discussion

H. perforatum, which is commonly used to accelerate the healing of burns and wounds, has been proven to have a positive effect on wound healing (5,9,10). In the literature, no studies were found about *H. perforatum* regarding its effect on wound healing in the oral mucosa in the presence of diabetes mellitus. The biologically active compounds in the structure

of this plant can be listed as naftodiantron, phloroglucinol, flavonoids, biflavons, phenylpropane and proanthocyanidins. These active compounds were examined separately but; our study has investigated the traditional use of *H. perforatum* rather than the separate effects of these substances.

H. perforatum accelerates the migration of fibroblasts, shortens the period of inflammation, increases the collagen deposition and induces better epithelialization (5,11). However, in diabetes mellitus, studies showing the effect on wound healing are limited. Yadollah-Damavandi *et al.* (12) reported the number of fibroblast cells increased in diabetic rats that were treated with *H. perforatum* compared to the control group. Farsak *et al.* (13) claimed *H. perforatum* and olive oil decreased the oxidative stress in the diabetic tissue permitting better healing. In our study, topical application of *H. perforatum* positively affected the wound healing in experimentally induced diabetic rats on the 7th day. We determined a statistically significant decrease in the 7th-day *H. perforatum* group compared to the control group regarding necrosis and ulceration variables.

Rao *et al.* (14) compared the effectiveness of *H. perforatum* and *Calendula* plants in a study conducted on albino rats. At the end of the study, the group treated with *H. perforatum* completed epithelialization in 15 days, whereas this duration was 16.5 days in the group treated with *Calendula*. Lavagna *et al.* (10) investigated the effect of the combined use of *Calendula* and *H. perforatum* oils (30:70 ratio) in a study conducted on 24 female patients who had given birth by caesarean section. They found a significant reduction in wound surface area compared to the control group. Suntar *et al.* (5) reported in an in vivo study on wound healing that *H. perforatum* had positive effects on epithelialization. In the present study, the results obtained on the 7th day were statistically significant. Accordingly, the level of epithelialization in the topical *H. perforatum*-administered group was higher. Our results showed that the topical administration of *H. perforatum* increased epithelialization in experimentally induced diabetic rats.

Menegazzi *et al.* (15) reported that the methanol extract of *H. perforatum* has anti-inflammatory effects. Hammer *et al.* (16) have proven in vitro that flavonoids, such as hyperforin and pseudohypericin along with amentoflavone and quercetin, are active anti-inflammatory components of the plant. *Hypericum* species lead to faster and better wound healing through active antibacterial components, such as hyperforin and flavonoids (17). Flavonoids are antioxidant compounds that are effective in prevention of cell damage and inhibition of lipid peroxidation. These compounds allow a reduction in cell damage and an increase in vitality of collagen fibrils (18). It was found that aqueous suspensions of *H. perforatum* teas are antimicrobially effective against gram-positive bacteria, and especially against methicillin-resistant *Staphylococcus aureus* species (19). In the present study, we evaluated the number of PNLs and MNLs to examine the anti-inflammatory effects of *H. perforatum*. Our findings also showed that *H. perforatum* shortened the duration of inflammation and anti-inflammatory effects. On the 7th day, we detected lower levels of PNLs and MNLs in the *H. perforatum*-administered group. There was a statistically significant difference between the groups in terms of PNL levels. Therefore, we suggest that *H.*

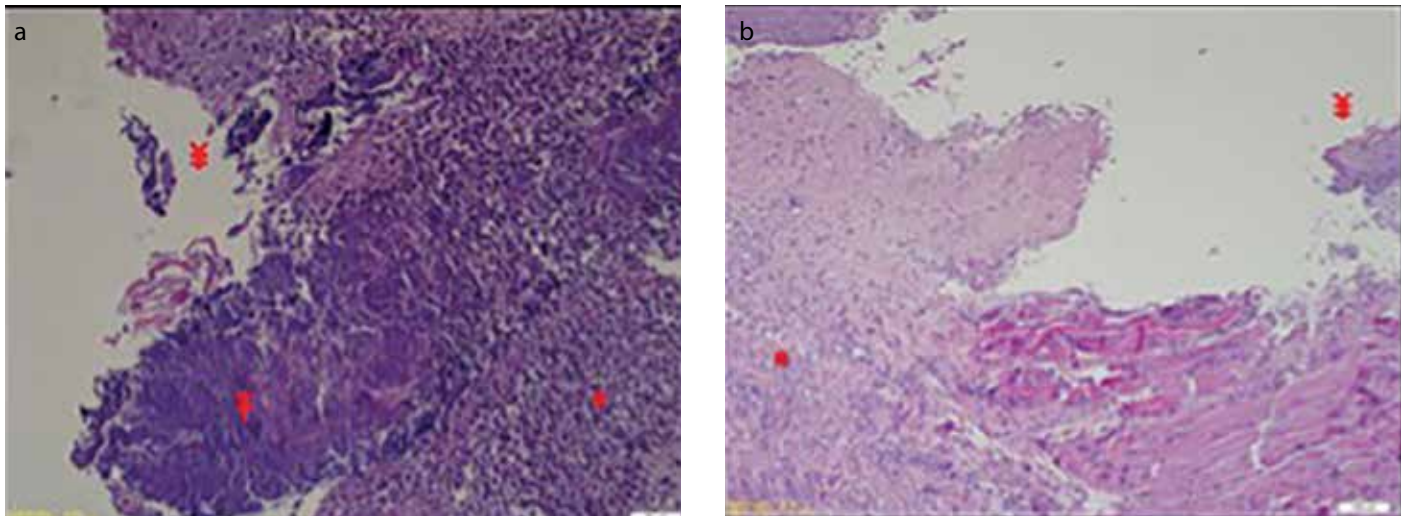


Figure 2. a, b. Mucosal tissue samples taken at 3rd day post-surgery. *H. perforatum* group (a) and control group (b). ulceration (¥), bacterium colonization (F) on the surface and leukocytes dominant, severely mixed inflammation (*) (H&E stain X200 and X100).

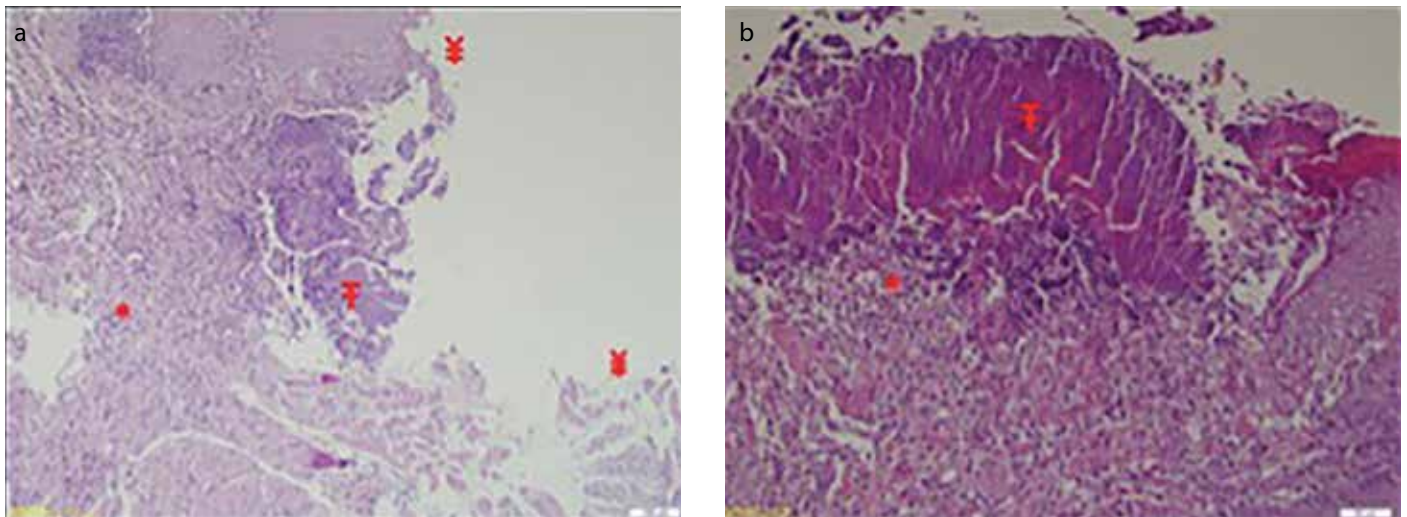


Figure 3. a, b. Mucosal tissue of the 7th day *H. perforatum* group (a) and control group (b). ulceration (¥), bacterium colonization (F) and medium-density, mixed type cell inflammation (*) is present. (H&E stain X100 and X200).

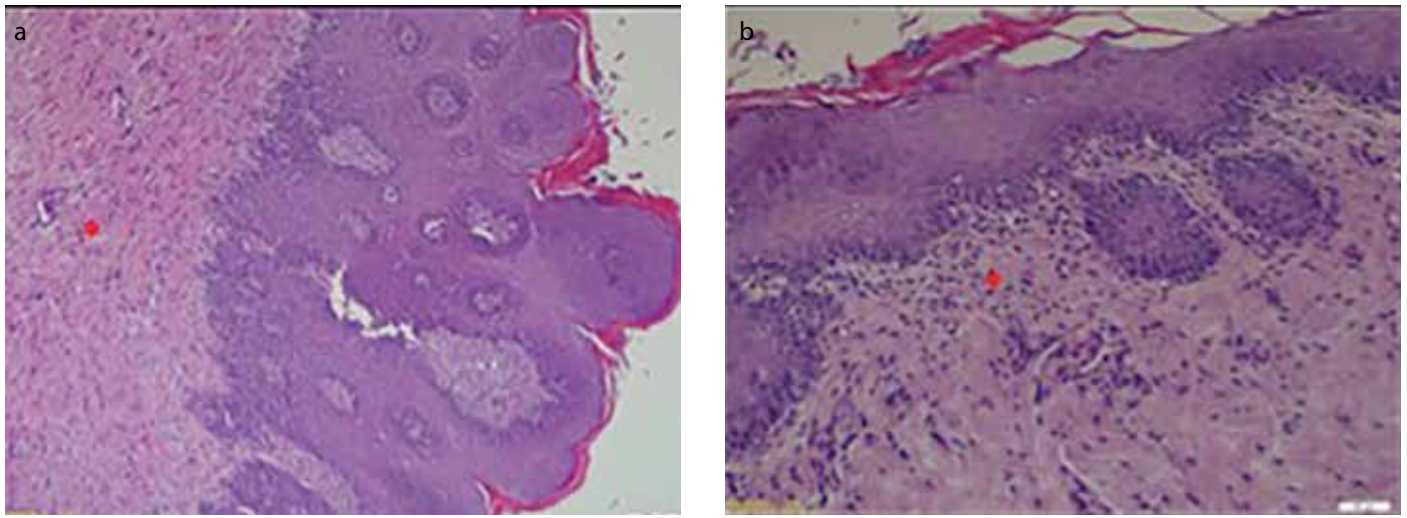


Figure 4. a, b. Mucosal tissue of the 10th day *H. perforatum* group (a) and control group (b). Underneath the epithelium, chronic inflammation and inflammatory granulation tissue (*) is present (Hematoxylin-Eosin stain X100 and X200).

perforatum has anti-inflammatory effects on wounds in the presence of diabetes mellitus, as well as on normal wounds.

Delayed wound healing in diabetic organisms may be due to insufficient formation of new blood vessels. In previ-

ous studies, hyperglycaemia occurring during diabetes has been shown to have adverse effects on the vascularisation (20). However, a consensus has not been reached regarding the effects of *H. perforatum*. Castro *et al.* (9) reported that the

Table 1. The results of statistical analysis of histopathological and biochemical variables

	3 rd day			7 th day			10 th day		
	HP group (n=8)	Control group (n=8)	p	HP group (n=8)	Control group (n=7)	p	HP group (n=8)	Control group (n=7)	p
Ulceration	0.750±.462	0.875±.353	0.519	0.375±.517	0.857±.377	0.049*	0.00±.000	0.14±.377	0.205
Necrosis	0.500±.534	0.500±.534	1.000	0.125±.353	0.714±.487	0.016*	0.00±.000	0.00±.000	1.000
Epithelialization	0.250±.462	0.125±.353	0.519	0.625±.517	0.142±.377	0.049*	1.00±.000	0.85±.377	0.205
Edema	1.250±.462	1.625±.517	0.143	1.250±.462	1.142±.377	0.617	1.25±.462	1.42±.534	0.480
PNL	1.625±1.187	1.250±.707	0.397	0.875±1.125	2.142±1.069	0.039*	0.62±.744	0.28±.487	0.350
MNL	2.000±.000	2.000±.000	1.000	1.625±.517	2.000±1.154	0.293	1.37±.517	1.57±.534	0.462
Fibroblasts	2.375±.517	2.500±.534	0.626	2.625±.517	2.857±.377	0.327	2.50±.534	2.4286±.534	0.789
Vascularization	2.250±.462	2.500±.534	0.317	2.500±.534	2.714±.487	0.414	2.37±.517	2.2857±.487	0.724
Hydroxyproline	18.70±.766	18.49±.937	0.205	25.25±.854	19.87±.967	0.001*	28.17±1.249	20.19±.829	0.001*

*p<0.05; HP: *Hypericum perforatum*; PNL: polymorphonuclear leukocytes; MNL: mononuclear cells

vascularisation was more frequent in their *H. perforatum*-administered group and it was observed that the formation of blood vessels was more extensive. Schempp *et al.* (21) reported that hyperforin, which is an active substances in *H. perforatum*, is an inhibitor of angiogenesis. Suntar *et al.* (5) observed in their study that *H. perforatum* had no effect on new blood vessel formation or proliferation of fibroblasts. They reported that the positive effect of *H. perforatum* on wound healing is caused by fibroblast migration and collagen deposition. We have found in our study that topical administration of *H. perforatum* has no effect on vascularisation.

Collagen synthesis, which is one of the most important events in wound healing, slows down and decreases in diabetic organisms (22). Öztürk *et al.* (23) suggested that the positive effect of *H. perforatum* on wound healing is caused by fibroblastic activity and increased collagen synthesis, in an in vitro study on embryonic chicken fibroblasts. Castro *et al.* (9) administered *H. perforatum* and Arnica montana on skin wounds in a study conducted on Wistar rats. The results indicated that this administration had a positive effect on the formation of new tissue compared to the control group, and the number of formed blood vessels along with the percentage of mature collagen fibres was higher. In our study, the difference between hydroxyproline values among the 7th-day and 10th-day groups was statistically significant. However, the fibroblast level, which is one of the parameters of histopathological examination, did not support this conclusion. With respect to the number of fibroblasts, there was no significant difference between the groups on the 3rd, 7th and 10th days. Biochemically, based on the fact that hydroxyproline determination is an objective method, we can say that topical *H. perforatum* administration mitigates the decrease seen in collagen synthesis for diabetic organisms, and affects wound healing positively with the occurring increase.

In diabetes mellitus, in which wound healing is adversely affected, the problems observed in wound healing can be listed as decreased cellular infiltration, angiogenesis, granulation tissue, collagen amount and organization, along with increased infectious complications (1). Although the causes of this problem seen in diabetes cannot be fully explained, hyperglycaemia

is generally held responsible. Arokiyaraj *et al.* (24) reported that the oral use of ethyl acetate extract of *H. perforatum* has anti-hyperglycaemic activity in rats, which were made diabetic with STZ. Husain *et al.* (25) reported in an animal study conducted on type 2 diabetes that a daily oral intake of 300 mg/kg of *H. perforatum* had the same effect as a daily intake of 10 mg/kg of glibenclamide, which is a potent hypoglycaemic agent. Can *et al.* (26) reported in their study, which investigated the effect of *H. perforatum* on blood glucose levels, that the plant has antidiabetic effects and this is caused by the flavonoids found in it. In a similar study, Kamalakkannan *et al.* (27) found that orally administered flavonoids had anti-hyperglycaemic and antioxidant effects on rats that were made diabetic with STZ. In terms of response to wound healing, it is observable that the topical and oral use of the same drug can give different results (28). As we used topical administration in our study, in which we saw the positive effects of *H. perforatum* oil for wound healing on the oral mucosa of diabetic rats, we believe that further studies should be conducted to be able to conclude that the positive effect on wound healing as mentioned in the literature is a result of the anti-hyperglycaemic effect, which occurs systematically.

Conclusion

Within the limitations of this experimental study, it can be concluded that the topical application of *H. perforatum* demonstrated positive effects on the healing of surgical defects created in the palatal mucosa of diabetic rats at 7th and 10th days.

Ethics Committee Approval: Ethics committee approval was received for this study from the Animal Ethics Committee of Mustafa Kemal University (No: 2014017).

Peer-review: Externally peer-reviewed.

Author Contributions: AA, CA designed the study. HG and OO generated the data. AA and İD gathered the data. MHA analyzed the data. AA and İD wrote the majority of the original draft. AA and CA collected the raw data of the study. All authors approved the final version of the paper.

Conflict of Interest: The authors have no conflicts of interest to declare.

Financial Disclosure: This project was supported with a grant from the research foundation of Mustafa Kemal University (project no: 12023).

Türkçe öz: Diyabetik sıçanlarda kantaronun (*Hypericum perforatum*) ağız mukozasındaki yara iyileşmesine etkisi. Amaç: Bu çalışmanın amacı *H. perforatum*'un (kantaron) topikal olarak uygulanmasının, deneysel olarak diyabet oluşturulmuş sıçanlarda ağız mukozasındaki yara iyileşmesine etkilerinin histopatolojik ve biyokimyasal olarak araştırılmasıdır. Gereç ve Yöntem: Çalışmada 48 adet, erkek, 5 aylık Wistar Albino rat kullanıldı. Deney hayvanları çalışma ve kontrol grubu olmak üzere, 24 sıçandan oluşan 2 ana gruba ayrıldı. Ana gruplar hayvanların sakrifiye edileceği günlere göre üç alt gruba ayrıldı. Tüm ratlara 60 mg/kg dozunda streptozotocin verildi. Yetmiş iki saat sonra yapılan ölçümlerde kan glikoz seviyesi 200 mg/dL'nin üzerinde olanlar çalışmaya dahil edildi. Sıçanlarda damak bölgesinde mukozal defektler oluşturuldu. Çalışma grubunda yaraya kantaron yağı, topikal olarak günde iki defa uygulandı. Kontrol grubundaki sıçanların yara bölgelerine herhangi bir uygulama yapılmadı. Sakrifiye edilen tüm ratlarda damakta oluşturulan yaralardan 3., 7. ve 10. günlerde örnekler alındı. Alınan örnekler histopatolojik ve biyokimyasal olarak incelendi. Bulgular: Yapılan istatistiksel analiz sonucunda 3. gün grupları arasında anlamlı bir fark görülmedi. 7. günde ise nekroz, polimorfonükleer lökosit, epitelizasyon, ülserasyon, ve hidroksipirolin değişkenlerinde istatistiksel olarak anlamlı farklılık bulundu ($p < 0,05$). Bu değişkenlerden nekroz, ülserasyon ve polimorfonükleer lökosit değerlerinin kontrol grubunda yüksek olduğu; epitelizasyon ve hidroksipirolin değerlerinin ise kantaron uygulanan çalışma grubunda daha yüksek olduğu tespit edildi ($p < 0,05$). Onuncu gün gruplar arasında sadece hidroksipirolin değerleri arasında anlamlı bir fark tespit edilmiş olup, kantaron uygulanan grupta hidroksipirolin seviyesinin yüksek olduğu görüldü ($p < 0,05$). Sonuç: Bu çalışma deneysel olarak diyabet oluşturulmuş sıçanlarda topikal olarak uygulanan *Hypericum perforatum*'un 3. günde herhangi bir farklılık oluşturmaya bile 7. ve 10. günlerde yara iyileşmesini olumlu yönde etkilediğini göstermiştir. Anahtar kelimeler: Diyabet; *Hypericum perforatum*; kantaron; ağız mukozası; yara iyileşmesi

References

- Blakytyn R, Jude E. The molecular biology of chronic wounds and delayed healing in diabetes. *Diabet Med* 2006; 23: 594-608. [CrossRef]
- Linde K. St. John's wort - an overview. *Forsch Komplementmed* 2009; 16: 146-55. [CrossRef]
- Zorzetto C, Sánchez-Mateo CC, Rabanal RM, Lupidi G, Petrelli D, Vitali LA, Bramucci M, Quassinti L, Caprioli G, Papa F, Ricciutelli M, Sagratini G, Vittori S, Maggi F. Phytochemical analysis and in vitro biological activity of three *Hypericum* species from the Canary Islands (*Hypericum reflexum*, *Hypericum canariense* and *Hypericum grandifolium*). *Fitoterapia* 2015; 100: 95-109. [CrossRef]
- Damlar I, Arpag OF, Tatlı U, Altan A. Effects of *Hypericum perforatum* on the healing of xenografts: a histomorphometric study in rabbits. *BJOMS* 2017; 55: 383-7. [CrossRef]
- Süntar IP, Akkol EK, Yilmazer D, Baykal T, Kirmizibekmez H, Alper M, Yeşilada E. Investigations on the in vivo wound healing potential of *Hypericum perforatum* L. *J Ethnopharmacol* 2010; 127: 468-77. [CrossRef]
- Wolfe U, Seelinger G, Schempp CM. Topical application of St. John's wort (*Hypericum perforatum*). *Planta Med* 2014; 80: 109-20.
- Nahrstedt A, Butterweck V. Biologically active and other chemical constituents of the herb of *Hypericum perforatum* L. *Pharmacopsychiatry* 1997; 30: 129-34. [CrossRef]
- Woessner JF Jr. The determination of hydroxyproline in tissue and protein samples containing small proportions of this imino acid. *Arch Biochem Biophys* 1961; 93: 440-7. [CrossRef]
- Castro FC, Magre A, Cherpinski R, Zelante PM, Neves LM, Esquisato MA, Mendonça FA, Santos GM. Effects of microcurrent application alone or in combination with topical *Hypericum perforatum* L. and *Arnica montana* L. on surgically induced wound healing in Wistar rats. *Homeopathy* 2012; 101: 147-53. [CrossRef]
- Lavagna SM, Secci D, Chimenti P, Bonsignore L, Ottaviani A, Bizzarri B. Efficacy of *Hypericum* and *Calendula* oils in the epithelial reconstruction of surgical wounds in childbirth with caesarean section. *Farmaco* 2001; 56: 451-3. [CrossRef]
- Yeşilada E, Honda G, Sezik E, Tabata M, Fujita T, Tanaka T, Takeda Y, Takaishi Y. Traditional medicine in Turkey. V. Folk medicine in the inner Taurus Mountains. *J Ethnopharmacol* 1995; 46: 133-52. [CrossRef]
- Yadollah-Damavandi S, Chavoshi-Nejad M, Jangholi E, Nekouyian N, Hosseini S, Seifae A, Rafiee S, Karimi H, Ashkani-Esfahani S, Parsa Y, Mohsenikia M. Topical *Hypericum perforatum* Improves Tissue Regeneration in Full-Thickness Excisional Wounds in Diabetic Rat Model. *Evid Based Complement Alternat med* 2015; 2015: doi: 10.1155/2015/245328. [CrossRef]
- Farsak M, Özdağlı G, Özmüş D, Çömelekoğlu Ü, Yalın S, Bozdoğan Arpacı R, Gen R, Kanık A, Ümit Talas D. Effects of *Hypericum perforatum* on an Experimentally Induced Diabetic Wound in a Rat Model. *Wounds* 2017; 29: E10-7.
- Rao SG, Udupa AL, Rao G, Rao PGM, Kulkarni DR. Wound healing activity of *Calendula officinalis* and *Hypericum*: two homeopathic drugs promoting wound healing in rats. *Fitoterapia* 1991; 62: 508-10.
- Menegazzi M, Di Paola R, Mazzon E, Muià C, Genovese T, Crisafulli C, Suzuki H, Cuzzocrea S. *Hypericum perforatum* attenuates the development of carrageenan-induced lung injury in mice. *Free Radic Biol Med* 2006; 40: 740-53. [CrossRef]
- Hammer KD, Hillwig ML, Solco AK, Dixon PM, Delate K, Murphy PA, Wurtele ES, Birt DF. Inhibition of prostaglandin E(2) production by anti-inflammatory *hypericum perforatum* extracts and constituents in RAW264.7 Mouse Macrophage Cells. *J Agric Food Chem* 2007; 55: 7323-31. [CrossRef]
- Cecchini C, Cresci A, Coman MM, Ricciutelli M, Sagratini G, Vittori S, Lucarini D, Maggi F. Antimicrobial activity of seven *hypericum* entities from central Italy. *Planta Med* 2007; 73: 564-6. [CrossRef]
- Getie M, Gebre-Mariam T, Rietz R, Neubert RH. Evaluation of the release profiles of flavonoids from topical formulations of the crude extract of the leaves of *Dodonaea viscosa* (Sapindaceae). *Pharmazie* 2002; 57: 320-2.
- Bystrov NS, Dobrynin VN, Kolosov MN, Chernov BK, Chervin, II. Structure of the chromophoric part of hyperforin. *Dokl Akad Nauk SSSR* 1975; 225: 1327-8.
- Teixeira AS, Andrade SP. Glucose-induced inhibition of angiogenesis in the rat sponge granuloma is prevented by aminoguanidine. *Life Sci* 1999; 64: 655-62. [CrossRef]
- Schempp CM, Kiss J, Kirkin V, Averbek M, Simon-Haarhaus B, Kremer B, Termeer CC, Sleeman J, Simon JC. Hyperforin acts as an angiogenesis inhibitor. *Planta Med* 2005; 71: 999-1004. [CrossRef]
- Bitar MS, Farook T, Wahid S, Francis IM. Glucocorticoid-dependent impairment of wound healing in experimental diabetes: amelioration by adrenalectomy and RU 486. *J Surg Res* 1999; 82: 234-43. [CrossRef]
- Ozturk N, Korkmaz S, Ozturk Y. Wound-healing activity of St. John's Wort (*Hypericum perforatum* L.) on chicken embryonic fibroblasts. *J Ethnopharmacol* 2007; 111: 33-9. [CrossRef]
- Arokiyaraj S, Balamurugan R, Augustian P. Antihyperglycemic effect of *Hypericum perforatum* ethyl acetate extract on streptozotocin-induced diabetic rats. *Asian Pac J Trop Biomed* 2011; 1: 386-90. [CrossRef]

25. Husain GM, Singh PN, Kumar V. Beneficial effects of a standardized *Hypericum perforatum* extract in rats with experimentally induced hyperglycemia. *Drug Discov Ther* 2009; 3: 215-20.
26. Can ÖD, Öztürk Y, Öztürk N, Sagratini G, Ricciutelli M, Vittori S, Maggi F. Effects of treatment with St. John's Wort on blood glucose levels and pain perceptions of streptozotocin-diabetic rats. *Fitoterapia* 2011; 82: 576-84. [\[CrossRef\]](#)
27. Kamalakkannan N, Prince PS. Antihyperglycaemic and antioxidant effect of rutin, a polyphenolic flavonoid, in streptozotocin-induced diabetic wistar rats. *Basic Clin Pharmacol Toxicol* 2006; 98: 97-103. [\[CrossRef\]](#)
28. Sidhu GS, Mani H, Gaddipati JP, Singh AK, Seth P, Banaudha KK, Patnaik GK, Maheshwari RK. Curcumin enhances wound healing in streptozotocin induced diabetic rats and genetically diabetic mice. *Wound Repair Regen* 1999; 7: 362-37. [\[CrossRef\]](#)