

Polarized Dermoscopy Facilitates Diagnosis and Treatment of Plantar Pseudohirsutism

Sody Naimer¹

ABSTRACT

Background: Plantar cutaneous conditions are the most common causes of foot discomfort limiting ambulation. Identification of indwelling foreign bodies is greatly facilitated by dermoscopy, allowing early detection of the character of the underlying pathological etiology. Furthermore, polarized dermoscopy provides ideal conditions of illumination and three-dimensional visualization of the involved site, without direct contact with the cutaneous surface. **Case Presentation:** A patient presented with localized plantar discomfort diagnosed as a soft tissue reaction to an embedded single human hair, folded and rooted inside the epidermis. Under magnified vision the phenomenon was characterized, the hair was extracted, the source was manipulated with a hypodermic needle and the lesion was removed with ensuing complete resolution. **Discussion:** Previous reports of hair slivers embedded inside the skin were attributed to barbers or animal grooming and the treatment was dictated by the severity of the complications. In this relatively mild case the intervention was greatly facilitated by therapeutic dermoscopy. **Conclusion:** Therapeutic dermoscopy is advocated for use to evaluate and treat many diverse body surfaces, especially the plantar skin as it raises the likelihood of successful treatment of embedded foreign bodies. Precisely how a single hair may become lodged into normal plantar skin remains to be explained.

Keywords: Case report; dermoscopy; ectopic body hair; foreign body; pseudohirsutism

¹ Department of Family Medicine, Faculty of Health Sciences, Ben-Gurion University of the Negev, Israel

Corresponding Author

Sody Naimer: Department of Family Medicine, Faculty of Health Sciences,
Ben-Gurion University of the Negev, POB 653, Beer-Sheva 84105, Israel
E-mail: sodyna@clalit.org.il

Contents

- 1 Background
- 2 Case presentation
- 3 Discussion
- 4 Conclusion
- 5 References

Background

Since hirsutism is defined as excessive body hair in men and women on parts of the body where hair is normally minimal or absent, hair growth of the sole may be included in this category. However, in an instance whereby the complete absence of a hair follicle is evident, by some illusive mechanism, we may coin such a condition as: "pseudohirsutism".

A common and disturbing complaint referring to the family physician is a painful focus over the plantar surface. In this report, a case of a solitary human hair lodged inside the superficial plantar skin was observed to result in the formation of a tender papule limiting normal function.

Case Presentation

A 54-year-old woman of normal health, complained of a bump on the sole of her foot causing pain upon weight bearing existent for a number of days. She could not recall walking barefoot outside the household or participating in any irregular activity that may have predisposed to any previous sores of the involved skin. There were no

domestic pets in the environment. Palpation revealed a mild protrusion of the skin surface. Close inspection raised suspicion of a sliver of hair "stuck" to the surface of the plantar skin, however the minute dimensions of the lesion precluded elucidation of any detail. In order to accurately assess the finding the lesion was examined with a smartphone, in photography mode, mounted over a polarized dermatoscope. A video recording of the procedure was performed for documentation. The cutaneous plane appeared completely normal with a 3 mm length of black human hair overlying the surface (figure 1).

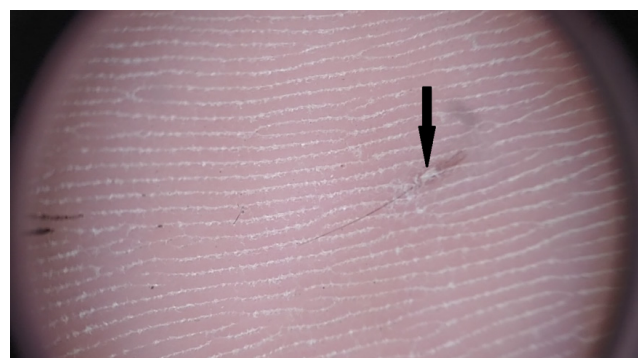


Figure 1. Dermoscopic image as projected onto the screen of the smartphone demonstrating a solitary plantar hair sliver penetrating the surface at a papular lesion.

To the right of the sole surface, the point the hair seemed attached, slight disruption of the integrity of the cutaneous surface is seen (figure 1 arrow). Upon attempt to remove the hair with forceps it seemed to elongate and its length



Figure 2. Introducing forceps between the dermoscope and the skin to grasp hair under vision.



Figure 3. Forceful traction of hair resulted in stretching until its eventual avulsion.

at least doubled far beyond that of its seemed stretching limits. (figures 2&3).

Further traction resulted in apparent release of the hair but apparently the stalk tore. The sharp tip of a 23G hypodermic needle was used to manipulate the epidermis. Folding over a segment of the superficial epidermal layer revealed a short stump of the hair embedded inside this tissue (figure 4).

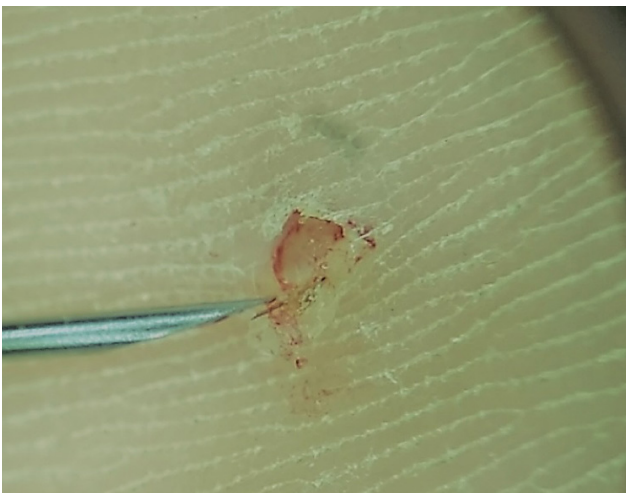


Figure 4. Hypodermic 23G needle tip manipulation of the papule where hair penetration was apparent reveals anchoring in the superficial epidermis.

The procedure was completed without bleeding and the lesion healed completely with resolution of symptoms and

since she did not suffer any sequelae or recurrences. The following three years of follow up since this condition appeared there were absolutely no consequences or symptoms.

Discussion

Foreign bodies constitute a substantial contribution to painful superficial plantar conditions. They pose an important challenge especially as they involve weight bearing surfaces in an awkward location. If left ignored, at times, extravagant and expensive imaging is needed in order to locate ignored penetrating bodies.^{1,2} Clinicians readily welcome a technique enabling prompt diagnosis and removal of foreign bodies prior to the onset of difficult to treat complications.^{3,4} The dermoscope offers a marked contribution while performing challenging therapeutic procedures. It has already been reported to facilitate identifying obscure conditions such as detection and extraction of unidentified corneal foreign bodies or buried sutures.^{5,6} Moreover, its value in identification and extraction of plantar foreign bodies has been established.⁷

Utilization of attachment of the dermoscope (3 Gen DermLite™) to the standard smartphone allows grasping the complete unit with one hand while the dominant hand is free to function as the situation demands. Polarized illumination is particularly advantageous for characterization of pigmented cutaneous lesions over standard lighting. In this instance, regular light source may have sufficed, nevertheless, as demonstrated in the escorting images superior contrast is achieved with polarization. Conversely, in order to perform forceps or needle manipulation of the skin under visualization, this is impossible to achieve with contact dermoscopy. Because a glass interface disallows any space between the examining instrument and the surface inspected. This is precisely where the polarized dermoscopy provides an ideal solution.

In 1942, Allington and Templeton described a pilonidal sinus, which was an important step leading to the discovery of an occupational acquired disease seen in barbers and hair dressers.⁸ Studies in the 1950s found a rate of approximately 13 percent problems with hair slivers among these two groups.⁹ The hair slivers in these groups are unusual in that they occur in non-hair-bearing areas such as between the toes or on the bottom of the foot. Other occupations such as dog groomers and sheep shearers are also at risk, but hair slivers can occur in anyone who owns an animal.¹⁰ They may be seen in runners who get pet hairs in their shoes as well.^{11,12}

This case demonstrates a unique phenomenon involving abnormal penetration of hair, an inherently benign component of skin appendage into the normal cutaneous plantar surface. It seems that part of the hair had been coiled inside the epidermis after somehow becoming incorporated into the layers of the epidermis. The precise mechanism of the penetration of this solitary hair adhering to the plantar tissue and arousing a localized inflammatory-like response

is complete enigmatic, especially as the history could not disclose any previous process in that zone. Furthermore attempts to find any such precedent in the medical literature were unsuccessful.

Conclusion

It is suggested that the use of therapeutic dermoscopy is an acceptable, improved and safe alternative to a blind search for an invisible intruding foreign body. Therapeutic dermoscopy is advocated for use to evaluate and treat many diverse body surfaces, especially the plantar skin as it raises the likelihood of successful treatment of embedded foreign bodies. Precisely how a single hair may become lodged into normal plantar skin remains to be explained.

References

1. Eidelman M, Bialik V, Miller Y, Kassis I. Plantar puncture wounds in children: analysis of 80 hospitalized patients and late sequelae. *Isr Med Assoc J.* 2003;5: 268-271.
2. Barták V, Krátký Z, Popelka ml S. Tumour-like lesion of the forefoot due to a retained toothpick fragment. [Case report]. *Acta Chir Orthop Traumatol Cech.* 2014;81(2):152-154.
3. Dar TA, Sultan A, Hussain S, Dhar SA, Ali MF. Contracture of the third toe as a delayed presentation of a foreign body in the foot. *Foot Ankle Spec.* 2011;4(5):298-300.
4. Joseph WS, Le Frock JL. Infections complicating puncture wounds of the foot. *J Foot Surg.* 1987; 26(1 Suppl):S30-S33.
5. Naimer SA, Urkin Y. Enhancement of pediatric ophthalmologic diagnosis with hand held polarized dermoscopy. *Clin Pediatr.* 2014;53:579-584.
6. Naimer SA. Prevention and Identification of Retained Sutures. *J Am Acad Dermatol.* 2014;70:e57-e58.
7. Naimer SA. Facilitating Detection and Extraction of Plantar Foreign Bodies: Therapeutic Dermoscopy. *J Am Board Fam Pract.* 2017;30:374-376.
8. Allington HV, Templeton HJ. Foreign body granuloma or interdigital cysts with hair formation. *Arch Dermatol Syph.* 1942; 46(7):157-158.
9. Efthimiadis C, Kosmidis C, Anthimidis G, Grigoriou M, Levva S, Fachantidis P. Barbers hair sinus in female hairdressers: uncommon manifestation of an occupational disease: a case report. *Case J.* 2008;1:214.
10. Papa CA, Ramsey ML, Tyler WB. Interdigital pilonidal sinus in a dog groomer. *J Am Acad Dermatol.* 2002;47:S281-S2812.
11. Schulz W. Hair as a penetrating foreign body in the plantar surface of the foot. *Arch Dermatol Syph.* 1950; 61(4):668.
12. O'Neal AC, Purcell EM, Regan PJ. Interdigital pilonidal sinus of the foot. *The Foot.* 2009; 19(4):227-228.