

# The accurate diagnosis of grand microvascular imaging in differentiating benign and malignant thyroid nodules: A meta-analysis

Y. Zhou and C. Wang\*

Department of Ultrasound, the First Affiliated Hospital of Dalian Medical University, Dalian, Liaoning Province, China

## ► Review article

### \*Corresponding author:

Dr. Cong Wang

E-mail: [fytgzy@163.com](mailto:fytgzy@163.com)

Received: May 2020

Final revised: October 2021

Accepted: October 2021

*Int. J. Radiat. Res.*, April 2022;  
20(2): 263-267

DOI: 10.52547/ijrr.20.2.2

**Keywords:** thyroid nodule, superb microvascular imaging, meta-analysis.

## ABSTRACT

**Background:** Meta-analysis experiments can be used to judge the hypothesis of SMI benign and malignant thyroid nodules. **Material and Methods:** We explored Cochrane Library, PubMed, Google Scholar, CBM and Web of Science, databases according to the required content, and used a number of analysis equipment to analyze, and through the conclusions drawn to determine the sensitivity (Sen) and specificity (Spe), the probability ratio of pragmatic and dismissive (LR + / LR-), diagnostic factor (DOR) and receiver performance typical curve (SROC) are calculated for summary statistics. **Results:** The meta-analysis included nine studies that met the participation criteria. An aggregation of 636 malignant thyroid legumes and 732 benign thyroid nodules were evaluated. The comprehensive Sen was 0.79 (95% confidence interval (CI) = 0.76-0.82), and the comprehensive Spe was 0.89 (95% CI = 0.85-0.92). The comprehensive LR + was 7.04 (95% CI = 5.26-9.43), and the comprehensive negative LR- was 0.23 (95% CI = 0.20-0.27). The comprehensive DOR of thyroid nodules diagnosed by SMI was 30.33 (95% confidence interval = 20.73–44.38). The range beneath the SROC curve was 0.82 (95% confidence interval = 0.79 to 0.86). We established no proof of reporting bias ( $t = 0.91$ ,  $P = 0.39$ ). **Conclusion:** In a related meta-analysis, the study found that SMI has a very high prognosis accuracy in distinguishing malignant and benign thyroid nodules.

## INTRODUCTION

Nowadays, thyroid cancer is a relatively usual tumor among malignant tumors, accounting for 1% of all cancer patients<sup>(1)</sup>. Because the threat element for thyroid cancer is solid thyroid nodules, this means that accurate identification of thyroid nodules is the most important link<sup>(2)</sup>. Ultrasonography represents the principal option for clinical prognosis and identification of thyroid cancer<sup>(3)</sup>. Nevertheless, because of the convolution and overlap of ultrasound images of thyroid nodules, it is strenuous to employ atypical ultrasound features to accurately identify the nodules<sup>(4)</sup>.

The blood circulation and vascular surface structure of benign and malignant thyroid nodules are dissimilar, which helps to distinguish the two<sup>(5)</sup>. Color Doppler flow imaging (CDFI) may indicate tumor circulation, but CDFI is not effective for some low-speed microvascular imaging<sup>(6)</sup>. Superb microvascular imaging (SMI) is a contemporary ultrasound technology which can simply, rapidly, and non-invasively monitor tumor microvascular disposition and assess microvascular perfusion<sup>(7)</sup>. Record the slow-flowing signal. In contrast, the traditional Doppler system using a one-dimensional

filter is not sufficient to perceive slow cues that intersect with the framework<sup>(8)</sup>. Early studies have shown that SMI may discern tumor angiogenesis and distinguish benign and malignant thyroid nodules<sup>(9)</sup>. Nevertheless, due to the small sample size of the presented researches and the limitations of a single center, clear conclusions cannot be drawn at present. SMI has not been systematically checked to diagnose thyroid nodules. The intention of this research was to establish the precision of SMI in the disparate investigation of benign and malignant thyroid lesions.

## MATERIALS AND METHODS

This meta-analysis protocol has been published<sup>(10)</sup>.

### Literature search

Searched CBM databases, Google Scholar, Cochrane Library, PubMed, and Web Science. These ensuing key-phrases and MeSH terms are engaged: ["thyroid cancer" or "thyroid tumor" or "thyroid tumor" or "thyroid nodule"] and ["excellent microvascular imaging"]. We checked the relevant content, read the bibliography of papers published in

recent years, and manually searched for other potential articles.

### Selection criteria

The inclusion criteria include: (1) it must be a clinical unit study or the research design of a diagnostic test, (2) the study requires SMI assessment of the accuracy in the distinctive analysis of thyroid benign and malignant, (3) all thyroid nodules must be histologically SMI inspection; (4) The information in the quadruple (2 × 2) table should be adequate for examination. If a survey fails to satisfy the inclusion criteria, it will be eliminated. Authors need to publish multiple studies on the same topic, and can include recent publications.

### Data extraction

Use standardized tables to systematically obtain relevant data from all studies of the two researchers. The investigators gathered the initial author's last name, publication year, publication language, and study structure, number of lesions, sample magnitude, and diagnostic accuracy. Four (2×2) tables of true positives (TP), true negatives (TN), false positives (FP) and false negatives (FN) are also collected.

### Quality evaluation

Two researchers evaluated the methodological quality separately rooted on the standard analysis of the diagnostic exactness study (QUADAS). The QUADAS standard contains 14 assessment points. Analysis points are obtained as "yes" (2), "no" (0) and "opaque" (1). QUADAS scores range from 0 to 28, and scores ≥ 22 indicate satisfactory standard.

### Statistical assessment

Meta-Disc version 1.4 (Universidad Complutense, Madrid, Spain) and STATA version 14.0 (Stata Corp, College Station, TX, USA) and were employed for the procedure. Calculate the sensitivity effect (SEN), singularity (SPE), positive and negative possibility ratio (LR + / LR-) and use the 95% confidence interval (CI) to estimate the threshold effect. Receiver performance characteristics (SROC) curve summary and the corresponding area under the curve (AUC, Spearman correlation coefficient is engaged to assess the threshold effect. The Cochran Q statistic and I2 test are employed to gauge the possible heterogeneity between the studies, if significant is observed Because of heterogeneity (Q test P<0.05 or I2 test> 50%), using random effects models or entities, we further conducted meta-regression and subgroup examination to investigate probable origins of heterogeneity. A sensitivity review was conducted to the analysis to assess overall estimates. We used the Begger funnel table and Egger's test to explore publication partiality.

## RESULTS

### Features of inclusion research

Key-phrase probes were pinpointed from 61 reports. The abstract and the article end with Article 39. A check of the entire text and data for completeness resulted in the exclusion of 13 other studies, leaving 13 research evaluations. Figure 1 shows the selection process for degree studies. Nine studies included 636 malignant thyroid nodules and 732 benign thyroid nodules. The features and procedural standard of the research are outlined in Table 1. In all included studies, the QUADAS score was ≥22.

**Table 1.** Baseline characteristics and methodological quality of all included studies.

First author	Year	Language	Sample size	Age (Years)	Instrument	SMI 2×2 table				QUA DAS score
						TP	FP	FN	TN	
Kong J <sup>(11)</sup>	2017	English	113	42(20-75)	Toshiba Ap1io400	60	3	19	31	24
Pei SF <sup>(12)</sup>	2015	English	196	—	Toshiba Ap1io500	92	5	26	73	23
Zhu YC <sup>(13)</sup>	2018	English	76	49.6 ± 13.2	Toshiba Ap1io500	25	7	4	40	24
Zhao YF <sup>(14)</sup>	2019	Chinese	296	—	Toshiba Ap1io500	105	21	34	136	23
Li YH <sup>(15)</sup>	2017	Chinese	254	39.0 ± 16.5	Toshiba Ap1io500	58	23	15	158	22
Yang GX <sup>(16)</sup>	2017	Chinese	236	49.4 ± 12.5	Toshiba Ap1io500	33	12	7	48	21
Chen X <sup>(17)</sup>	2017	Chinese	163	45.2 ± 18.5	Toshiba Ap1io500	48	6	10	99	22
Diao XH <sup>(18)</sup>	2016	Chinese	68	44.8 ± 17.6	Toshiba Ap1io500	24	2	3	39	23
Zhao YF <sup>(19)</sup>	2020	English	102	44.0 ± 10.6	Toshiba Ap1io500	60	6	13	23	24

### Quantitative material synthesis

The fixed effects model was employed because there lacked a significant heterogeneity during the study period. A sensitivity analysis was performed and there was no significant interference with the outcomes of the meta-analysis (figure 2). The comprehensive Sen is 0.79 (95% CI = 0.76-0.82); the comprehensive Spe is 0.89 (95% CI = 0.85-0.92) (figure 3); the overall LR + is 7.04 (95% CI = 5.26-9.43); the combined negative LR- is 0.23 (95% confidence interval = 0.20-0.27) (figure 4). There lacked a substantial correspondence linking sensitivity and specificity (r = 0.167, P = 0.668). The combined DOR of thyroid nodules diagnosed with SMI was 30.33 (95% confidence interval = 20.73-44.38) (figure 5). The range under the SROC curve is 0.82 (95% confidence interval = 0.79-0.82) (figure 6). There lacks any proof of imbalance in the funnel chart (figure 7). The Egger test failed to yield compelling qualitative evidence of release error (t = 0.91, P = 0.39). Figure 8 shows a SIM image of benign and malignant and benign thyroid lesions.

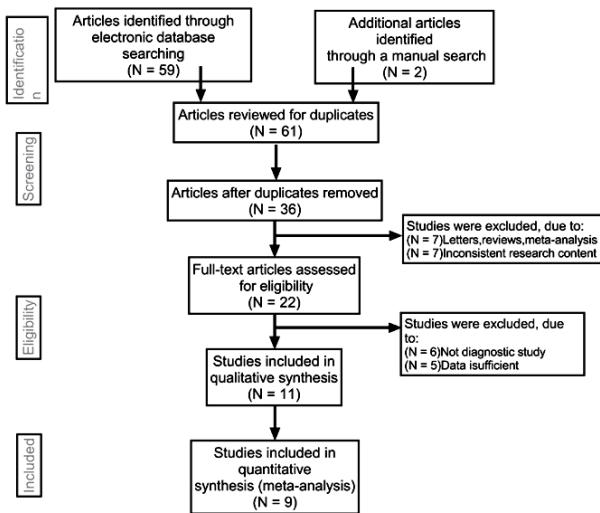


Figure 1. Flow chart of the literature search and study selection. Nine studies were included in this meta-analysis.

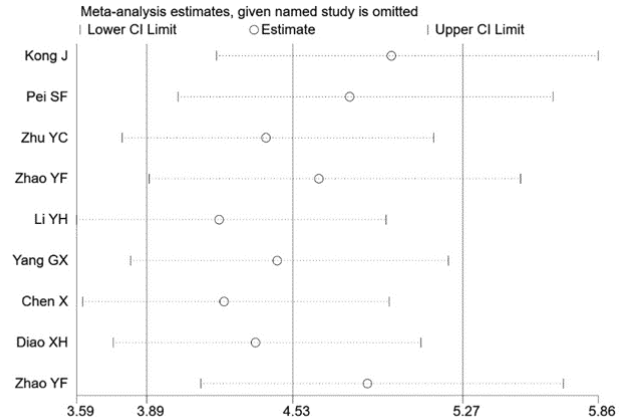


Figure 2. Sensitivity analysis. No study had an obvious interference with the results. CI confidence intervals, OR odds ratio.

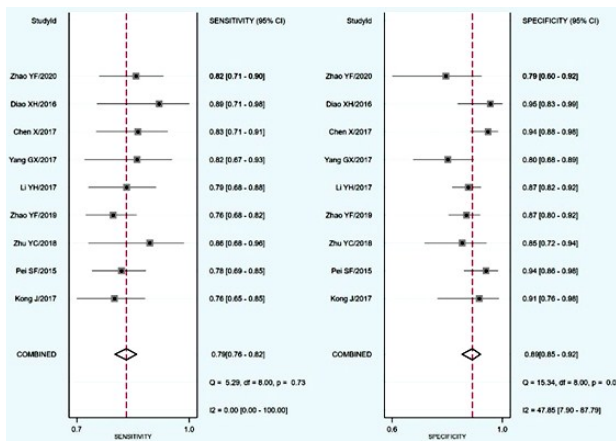


Figure 3. Forest plots for the accuracy of SMI in the diagnosis of thyroid nodules: a) Sensitivity and Specificity.

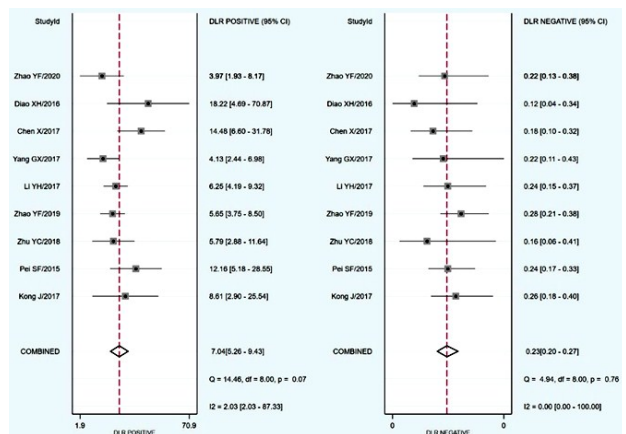


Figure 4. Forest plots for the accuracy of SMI in the diagnosis of thyroid nodules: a) Sensitivity, b) Specificity, c) Positive likelihood ratio, and d) Negative likelihood ratio. CI confidence intervals, SMI superb microvascular imaging.

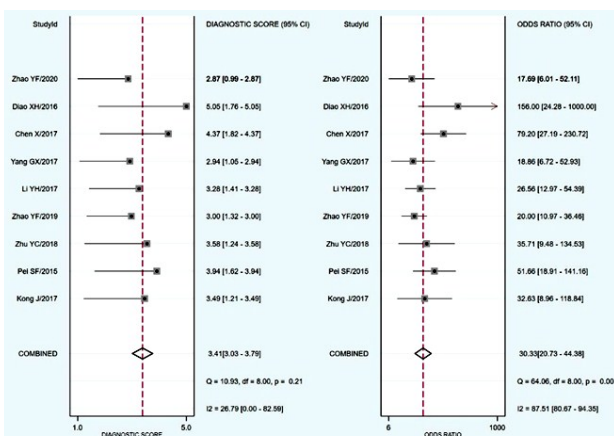


Figure 5. Forest plot of DOR of SMI for the diagnosis of thyroid nodules. DOR diagnostic odds ratio, SMI superb microvascular imaging.

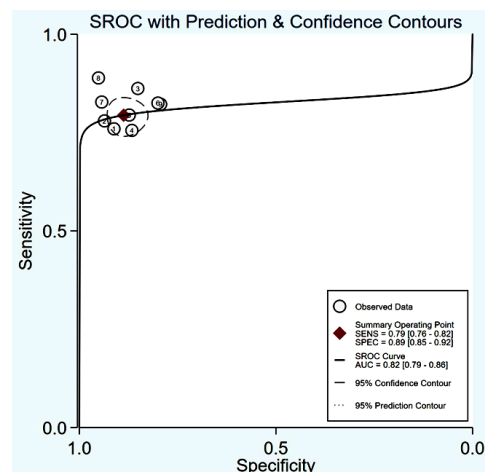
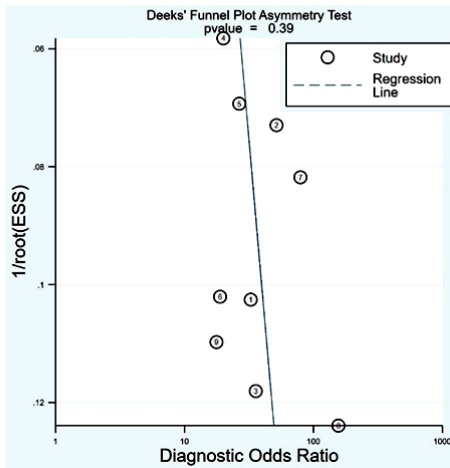
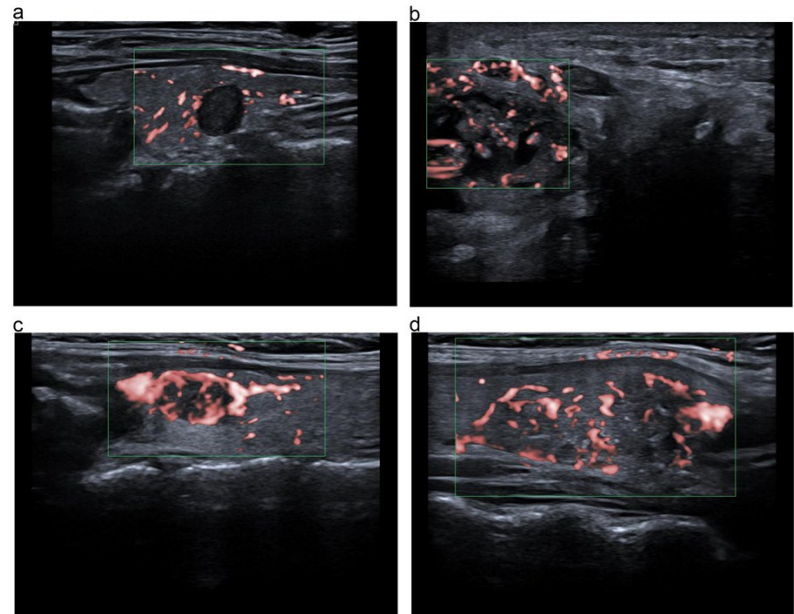


Figure 6. SROC curve for the accuracy of SMI in the diagnosis of thyroid nodules. AUC area under curve, SMI superb microvascular imaging, SROC summary receiver operator characteristic.



**Figure 7.** Begger's funnel plot of publication bias on the pooled OR. No publication bias was detected in this meta-analysis.



**Figure 8.** SIM image for thyroid nodules. **a)** Nodular goiter; **b, c and d)** papillary thyroid carcinoma.

## DISCUSSION

Thyroid abrasions are a substantially regular discovery, and precise differentiation is elemental towards clinical conclusion-determination. Hyperspectral ultrasound has a crucial part in the differential assessment of thyroid lesions (20). The ultrasound characteristics of malignant thyroid legumes are hypoechoic, inconspicuous, an aspect ratio >1, and micro-calcification. These findings raise the likelihood of malignant nodules. However, there lacks any ultrasound characteristic that can singly detect malignant nodules (21). The circulation pattern of benign and malignant thyroid nodules is different (22). The vascular and circulatory properties of thyroid nodules can be used for the distinctive analysis of malignant and benign thyroid nodules (23, 24). Nevertheless, the practicality of color Doppler technique in the assessment of malignant and benign thyroid nodules is contentious.

SMI employs hyperspectral Aplio diagnostic equipment (Doppler ultrasound) to develop a concentrated beam-former. Conventional Doppler ultrasound engages filtering to reduce blood circulation and eradicate movement and noise reminders. SMI mechanics can establish the cycle generated by the tissue and sequence action, and manifest the adaptive cycle computation procedure to exhibit the actual cycle data.

Studies have shown that SMI can precisely differentiate malignant and benign abrasions. This discovery is another fact that SMI has the advantage of identifying low-speed blood circulation with the absence of CDFI-related business artifact-complications. SMI helps us in grayscale, showing that the separation of benign and malignant thyroid nodules alone or with the help of CDFI (13) improves

diagnostic performance. SMI is expected to complement rather than replace the United States. In theory, the current meta-analysis emphasizes the application of SMI in remedying diseases such as thyroid disease and other breast diseases.

A systematic review of the practical precision and efficiency of SMI in the differential analysis of malignant and benign thyroid nodules. The overall SM, SMe, and DOR for the assessment of thyroid buds were 0.79, 0.89, and 30.33, respectively. In the SMI study, the combined values of Sen, Spe and DOR in breast cancer diagnosis were 0.81, 0.71 and 46.97, respectively (25). These outcomes coincide with the possibly more diagnostic exactness of SMI for different tumors, indicating that SMI is a reliable method to distinguish malignant and benign thyroid nodules, and can predict the prognosis of patients with thyroid nodules. The outcomes established no direct proof of publication bias. These data indicate that, according to previous studies, SMI is an accurate non-invasive tool that can be used for the qualitative analysis of thyroid nodules.

Despite this being a pioneer meta-analysis concentrating on the exactness of SMI thyroid diagnosis, our research is still limited. First, the sample size of the evaluated study is relatively small, and there is not enough information to evaluate the exactness of SMI. In addition, the backdated state of the meta-analysis led to topic choice. In addition, most research started in a geographic area (ie, China). Such location restrictions could severely influence the genuineness and plausibility of the results.

In conclusion, this report reveals that through meta-research analysis, SMI can generate a comprehensively precise diagnosis of malignant and benign thyroid nodules. Simultaneously, the findings

array that SMI is often accorded top priority when assessing thyroid nodules.

#### ACKNOWLEDGMENTS

We would like to acknowledge the helpful comments on this paper received from our reviewers. We would also like to thank all our colleagues working in the Ultrasound Department of the First Affiliated Hospital at Dalian Medical University. We thank LetPub ([www.letpub.com](http://www.letpub.com)) for its linguistic assistance during the preparation of this manuscript.

#### Systematic review registration:

INPLASY202080084

**Ethical considerations:** We will not obtain ethic documents because this study will be conducted based on the data of published literature.

**Author contributions:** Data curation: (Y.Z). Investigation: (Y.Z). Writing – review & editing: (C.W).

**Conflict of interest:** The authors declare that they have no competing interests.

**Funding:** This study is held up by Liaoning Natural Science Foundation Project (20170540256) and scientific research fund project of Education Department of Liaoning Province (LZ2020027).

#### REFERENCES

- Haugen BR, Alexander EK, Bible KC, Doherty GM, Mandel SJ, Nikiforov YE, Pacini F, Randolph GW, Sawka AM, Schlumberger M, Schuff KG, Sherman SI, Sosa JA, Steward DL, Tuttle RM, Wartofsky L (2016) 2015 American Thyroid Association Management Guidelines for Adult Patients with Thyroid Nodules and Differentiated Thyroid Cancer: The American Thyroid Association Guidelines Task Force on Thyroid Nodules and Differentiated Thyroid Cancer. *Thyroid*, **26**(1): 1-133.
- Prete A, Borges de Souza P, Censi S, Muzza M, Nucci N, Sponziello M (2020) Update on fundamental mechanisms of thyroid cancer. *Front Endocrinol (Lausanne)*, **13**(11): 102.
- Valderrabano P, McIver B (2017) Evaluation and management of indeterminate thyroid nodules: The revolution of risk stratification beyond cytological diagnosis. *Cancer Control*, **24**(5): 1073274817729231.
- Woliński K, Szkudlarek M, Szczepanek-Parulska E, Ruchała M (2014) Usefulness of different ultrasound features of malignancy in predicting the type of thyroid lesions: a meta-analysis of prospective studies. *Pol Arch Med Wewn*, **124**(3): 97-104.
- Reginelli A, Urraro F, di Grezia G, Napolitano G, Maggioletti N, Cappabianca S, Brunese L, Squillaci E (2014) Conventional ultrasound integrated with elastosonography and B-flow imaging in the diagnosis of thyroid nodular lesions. *Int J Surg*, **12**(1): S117-22.
- Wang XN, Zhao Q, Li DJ, Wang ZY, Chen W, Li YF, Cui R, Shen L, Wang RK, Peng XY, Yang WL (2019) Quantitative evaluation of primary retinitis pigmentosa patients using colour Doppler flow imaging and optical coherence tomography angiography. *Acta Ophthalmol*, **97**(7): e993-e997.
- Hata T, Koyanagi A, Yamanishi T, Bouno S, Takayoshi R, Miyake T (2020) Superb microvascular imaging with Doppler luminance using an 18-MHz probe to visualize fetal intra-abdominal blood vessels and organ microvasculature. *J Perinat Med*, **48**(2): 184-188.
- Jiang ZZ, Huang YH, Shen HL, Liu XT (2019) Clinical Applications of Superb Microvascular Imaging in the Liver, Breast, Thyroid, Skeletal Muscle, and Carotid Plaques. *J Ultrasound Med*, **38**(11): 2811-2820.
- Cappelli C, Pirola I, Gandossi E, Marini F, Cristiano A, Casella C, Lombardi D, Agosti B, Ferlin A, Castellano M (2019) Ultrasound Microvascular Blood Flow Evaluation: A New Tool for the Management of Thyroid Nodule? *Int J Endocrinol*, **25**(2019): 7874890.
- Tian C, Wang Z, Hou X, Wang C (2020) The diagnostic accuracy of superb microvascular imaging in distinguishing thyroid nodules: A protocol for systematic review and meta analysis. *Medicine*, **99**(40): e22350.
- Kong J, Li JC, Wang HY, Wang YH, Zhao RN, Zhang Y, Jin J (2017) Role of superb micro-vascular imaging in the preoperative evaluation of thyroid nodules: Comparison with power doppler flow imaging. *J Ultrasound Med*, **36**(7): 1329-1337.
- Pei S, Cong S, Zhang B, Liang C, Zhang L, Liu J, Guo Y, Zhang S (2019) Diagnostic value of multimodal ultrasound imaging in differentiating benign and malignant TI-RADS category 4 nodules. *Int J Clin Oncol*, **24**(6): 632-639.
- Zhu YC, Zhang Y, Deng SH, Jiang Q (2018) A prospective study to compare superb microvascular imaging with grayscale ultrasound and color doppler flow imaging of vascular distribution and morphology in thyroid nodules. *Med Sci Monit*, **19**(24): 9223-9231.
- Zhao Y, Zhou P, Peng H, Liu W, Zhang Y, Lu X (2019) Application of superb microvascular imaging and contrast enhanced ultrasound in the differential diagnosis of thyroid nodules. *J Cent South Univ Med Sci*, **44**(6): 649-656.
- Li YH, Wen DH, Li CX, Li XJ, Xue G (2017) The role of ATA (2015) guidelines, superb microvascular imaging, and spectral Doppler in differentiation between malignant and benign thyroid nodules. *J. Clin. Otorhinolaryngol. Head Neck Surg*, **31**(15): 1152-1156.
- Yang, GX (2017) The value of superb microvascular imaging for diagnosis of thyroid. Master's Thesis, Zunyi Medical University, Zunyi.
- Chen X, Wu CJ, Xing P, Chu YZ (2017) Value of thyroid imaging-reporting and data system combined with shear wave elastography and superb microvascular imaging in the differentiation of benign and malignant thyroid nodules. *J Harbin Med Univ*, **51**(1): 44-48, 52.
- Diao XH, Zhan J, Chen L (2016) The value of superb micro-vascular imaging for diagnosis of thyroid nodules. *Chin J Med Ultrasound*, **13**(8): 622-626.
- Zhao YF, Zhou P, Peng H, Liu WG, Zhang Y (2020) Superb microvascular imaging compared with contrast-enhanced ultrasound to assess microvessels in thyroid nodules. *J Med Ultrason*, **47**: 287-297.
- Gharib H, Papini E, Paschke R, Duick DS, Valcavi R, Hegedus L, Vitti P (2010) AACE/American Thyroid Association Task Force on Thyroid Nodules: American Association of Clinical Endocrinologists, Associazione Medici Endocrinologi, and European Thyroid Association Medical guidelines for clinical practice for the diagnosis and management of thyroid nodules: executive summary of recommendations. *Endocr Pract*, **16**(3): 468-475.
- Cohen O, Lahav G, Schindel D, Halperin D (2020) Surgeon performed thyroid and neck ultrasound as a tool for better patient care. *Harefuah*, **159**(1): 128-131.
- Nguemgo Kouam P, Bühler H, Hero T, Adamietz I (2019) The increased adhesion of tumor cells to endothelial cells after irradiation can be reduced by FAK-inhibition. *Radiat. Oncol*, **14**(1): 25.
- Sultan LR, Xiong H, Zafar HM, Schultz SM, Langer JE, Sehgal CM (2015) Vascularity assessment of thyroid nodules by quantitative color Doppler ultrasound. *Ultrasound Med Biol*, **41**(5):1287-1293.
- Zhan J, Diao XH, Jin JM, Chen L, Chen Y (2015) Superb microvascular imaging-a new vascular detecting ultrasonographic technique for avascular breast masses: a preliminary study. *Eur J Radiol*, **85**(5): 915-921.
- Zhong L and Wang C (2020) Diagnostic accuracy of ultrasound superb microvascular imaging for breast tumor: a meta-analysis. *Med Ultrason*, **22**(3): 313-318.

